

The Neoadjuvant Chemotherapy and Expandable Prosthesis Reconstruction to Treat Osteosarcoma Around the Knee in Child

Jiajia Cheng

Mianyang Central Hospital

Junqi Huang (✉ 13011277676@163.com)

Mianyang Central Hospital

Wenzhi Bi

Chinese PLA General Hospital

Gang Han

Chinese PLA General Hospital

Jinpeng Jia

Chinese PLA General Hospital

Meng Xu

Chinese PLA General Hospital

Wei Wang

Chinese PLA General Hospital

Research Article

Keywords: Osteosarcoma, Knee, arthroplasty, child

Posted Date: December 10th, 2020

DOI: <https://doi.org/10.21203/rs.3.rs-120042/v1>

License: © ⓘ This work is licensed under a Creative Commons Attribution 4.0 International License.

[Read Full License](#)

Abstract

Background: To investigate: (1) what are the prognosis in patients treated with this chemotherapy scheme and limb salvage; (2) what are the clinical outcomes of expandable endoprosthesis reconstruction in child?

Methods: From January 2009 to December 2014, we retropected 29 skeletally immature kids (mean age, 10.5 years; range, 6-15 years) with osteosarcoma around knee. Of the 29 patients who underwent neoadjuvant chemotherapy and limb salvage surgery, this expandable prosthesis was implanted to reconstruct. These 29 patients were included in our retrospection. No patients were missed during follow-up. The evaluation index involved follow-up time, complication, functional results, lengthening procedures. The survivorship and recurrence were assessed by SPSS software. The function was assessed by Musculoskeletal Tumor Society (MSTS) scoring system.

Results: A mean of follow-up time was 8.9 years (range, 6-12years). The overall 5-year survival was 89.1% based on Kaplan-Meier. Relapse suffered in three patients and one underwent amputation. Lung metastasis developed in one patient. At six months after operation, patients had a mean MSTS score of 27 points (range, 24-29). Two patients underwent revision surgery—one for implant infection and one for aseptic loosening.

Conclusions: Chemotherapy scheme and limb salvage could achieved high survival rate. Use of this expandable prosthesis was associated with good function and low complication. The character of expandability could be a method to overcome discrepancy in the growth period.

Level of Evidence Level IV, therapeutic study.

Introduction

Osteosarcoma is the most common primary bone malignant disease, which occurs in about seven children per million a year¹. The current protocols to treat osteosarcoma include neoadjuvant chemotherapy and surgery². Protocols of chemotherapy are still various in different institutions. There is no standardized method showing superior prognosis. Meanwhile, Limb salvage after tumor resection, particularly in immature patients, is challenging³. The growth of the lower extremity is attributed 35% and 30%, respectively, to the epiphyses of the distal femur and proximal tibia⁴. Surgical resection completely removes the lesion with adequate margins. Reduced growth in surgery results in a potential discrepancy⁵. Small anatomic size, high functional and mechanical demands of active immature patients are also problems.

Limb reconstruction after tumor resection includes arthrodeses, megaprosthesis, allografts, allograft-prosthetic devices. The main limitation about arthrodeses is poor activity and appearance.

Megaprosthesis and allograft-prosthetic devices are confined to affect the physis⁶. Allografts are hard to

match small anatomic size in immature patients⁷. It increases the risk for osteolysis and degenerative arthritis.

Expandable prosthesis have been designed to overcome these problems⁸. Both sides of views are coexistence. There are positive reports on postoperative results of the device⁹. Some study also demonstrates the expandable prosthesis has high complication rate and revision rate^{10,11}. The complications are aseptic loosening, infection, disable prolong device, implant fracture.

We therefore analyzed our experience with neoadjuvant chemotherapy and expandable prosthesis reconstruction. We asked (1) what are the prognosis in patients treated with this chemotherapy scheme and limb salvage; (2) what are the clinical outcomes of expandable endoprosthesis reconstruction in child?

Results

All patients had a mean follow-up time of 8.9 years (range from 6–12 years). The overall survival was 89.1% at 5 years[Figure 3]. One patient had died of lung metastasis after 8 months. Three patients had relapse during the follow-up time. Further chemotherapy and wide resection was conducted. Of those patients, two died of the disease, and one was alive without evidence of disease at the time of the latest follow-up. The patients with recurrence or metastasis had higher serum alkaline phosphatase level than the normal range[Table 2]. Nonparametric correlations test revealed the connection between alkaline phosphatase change after treatment and prognosis ($P = 0.012$).

These twenty-nine patients had a mean The Musculoskeletal Tumor Society(MSTS) 93 score of 27 points. Three patients with proximal tibia lesion presented lower function score than patients with distal femur lesion. The range of motion was 90–120° and 100–140° respectively. Correlations test demonstrated no dependency the length of bone resection and MSTS score($P > 0.05$).

At the time of surgery, the height of patients ranges from 115 cm to 165 cm. The rate of lower limb/height in our cohort was 45% equally. 18 patients were performed lengthening surgery. An average lengthening of 4 cm per patient was obtained.

One patient had prosthesis infection after 26 months postoperatively. It appeared swell and pain around joint. Leukocyte counts and erythrocyte sedimentation rate were higher than the normal level. Gram-negative bacilli was cultured from synovial fluid. Debridement and antibiotics were conducted in the early period. It is time to revision when biochemistry index was controlled. One patient had clinical and radiographic signs of aseptic loosening. Complete revision of the primary prosthesis was underwent at the 4th year postoperative. One patient suffered from numbness and paresthesia. Neurotrophic medicine was used postoperatively to relieve the symptom within 6 months.

Discussion

Neoadjuvant chemotherapy is the necessary treatment for extremity osteosarcoma. This common conclusion was deduced by many studies^{15,16}. On the basis of previous results, methotrexate, doxorubicin, cisplatin and ifosfamide are treated as active medicines. But the best combination for regimen has not yet been confirmed¹⁷.

In this retrospective study, patients were administered the 3-drug regimen. The overall survival was 89.1% at 5 years. We found it better tolerated with similar efficacy. Relapse rate was not added. Survival rate at 5 years was higher than the value in multiple-discipline therapy studies¹⁸. The reason for desirable prognosis might be that patients in our study were treated in early time and that the size of lesion was limitation. Alkaline phosphatase as indirect detection was measured pre and post treatment. The value of alkaline phosphatase was descended after remedy. When relapse or metastasis experienced, the value showed absolutely abnormal. It sent a dangerous message in follow-up. The correlation test confirmed the change of alkaline phosphatase pre and post treatment affected prognosis. Though, other factors such as chemotherapy courses had faint influence with prognosis. Pathologic fracture might not be the contraindication of limb salvage.

Reconstruction after resection of tumor is challenging in children. The risk of limb discrepancy after limb salvage surgery draws concern¹⁹. The use of traditional prosthesis may destroy unaffected growth plate, causing additional crispation. It is not available and therefore not an option.

We present an expandable prosthesis that restores defection of bone and preserves unaffected growth plate. Adequate lengthening of the extremity can be achieved with this prosthesis. Small anatomic size is also the elementary factors in immature patients. In our series, the smallest device is 80 mm in length and 8 mm in diameter. It is not necessary to expand marrow. The relation between device complication like prosthesis breakage and size of prosthesis was not significant in our study. Previous reports suggested that infection and local recurrence are the main failure reasons^{20,21}. In our study, only one patient had infection. Lower prosthesis complication reduced the risk of second intervention before replacement with a permanent prosthesis. This process saves medical expense which plays an important role in developing country. Functional assessment in the follow up indicated that affected limb was competent for daily life.

Considering soft-tissue cover and nerve strain, the prosthesis was 2 cm longer than bone loss initially. The concrete time based on whole length of limb measurement. Pelvic anteroposterior radiographs and whole length of lower limb graphs had to be shot that ensuring the extent of limb discrepancy. The slight difference of limb length could be eliminated by shoe lift. Patients were considered for external limb lengthening with the difference over 3 cm. In our series, prosthesis was prolonged about 2 cm per 10 months postoperatively to avoid discrepancy. The average actual length reached was 4 cm. We observed no nerve injury. This process needs compliance from the patient and the family. They had to be conscious of the necessity of lengthening of implants and at least 1 revision. Also, further knee exercise is necessary on the part of the patient, and the patient's family.

Patients And Methods

We reviewed twenty-nine immature participants (younger than 15 years) with high-grade osteosarcoma around knee, between January 2009 and December 2013 at one institution. This research has been approved by the Institutional Review Board (IRB) of our institutions. Principles of all research were followed and all procedures were conducted according to the guidelines established by WMA Declaration of Helsinki – Ethical Principles for Medical Research Involving Human Subjects. Informed consent was obtained from all subjects or, if subjects are under 18, from a parent and/or legal guardian.

The patients in this study underwent neoadjuvant chemotherapy and expandable prosthesis reconstruction after tumor resection. The series included nineteen male, ten female patients, with a mean age of 10.5 years (range 6 to 15 years). Twenty-six lesions were located at the distal femur, three at the proximal tibia. All patients had Stage IIB tumors according to the Enneking staging system¹².

All of the patients received neoadjuvant chemotherapy. The chemotherapy protocol consisted of ifosfamide, methotrexate and doxorubicin. Ifosfamide was given at 2 g/m²/d on days 1 to 5 while methotrexate 8 g/m²/d on day 3. Doxorubicin was administered at 40 mg/m²/d on day 5. 3 cycles later, the eligible met the following inclusion criteria: (1) having complete fat edge surrounding tumor in MRI, (2) not invading popliteal (tibial) artery and vein, not invading tibial (peroneal) nerve, (3) without detecting metastasis, (4) without active infection. Nine individuals were added 1 course because of the broad invasion of lesion. Considering preoperative reaction and tolerance, 6–9 courses chemotherapy would be finished postoperatively.

Age and tumor extension were treated as main factors to use expandable implant reconstruction. Magnetic resonance imaging (MRI) was mandatory for excluded any joint contamination and surgical planning. Wide resection margins were attained in patients. The initial length of expandable prosthesis was 2 cm longer than resected specimens. The average length of prosthesis gained was 18 cm. The average prosthesis diameter was 1.14 cm. Stem length was 14.8 cm [Table 1]. The patellar tendon was reattached in prosthesis groove in 3 patients with proximal tibia osteosarcoma. A medial gastrocnemius muscle flap was used to rebuilt soft-tissue coverage of the device in 2 patients with insufficient normal soft-tissue.

The discrepancy was defined as the different length from anterior superior spine to malleolus medialis, and pelvic incline. Patients were considered for external limb lengthening with the difference over 3 cm. Minimal invasive surgery was conducted to lengthen the implant. The expandable prosthesis had a lengthening mechanism composed of two titanium alloy tube connected with screw [Figure 1]. The titanium alloy tube was rotated and expanded, lengthening the prosthesis. It takes 360° rotation to obtain 1 mm expansion. It is locked by variable size of prolonged loop embedded in the gap between two alloy tube [Figure 2]. The length of expansion was shorter than 2 cm every time to avoid the nerve strain injured.

The early weight bearing, active and passive motion was continued postoperatively. To ensure the tension union, activity were delayed about 3 weeks in patients with patella ligament reattachment. All patients

were examined limb X-ray, lung CT per 6 months in follow-up. PET was conducted every year. The purpose was to detect local control and distal metastases.

We collected clinical records(including sex, age, location of lesion, pathological fracture, resection length), the course of chemotherapy, the change of alkaline phosphatase between pre- and post-treatment¹³, and prosthesis characteristics(device length, stem diameter, stem length, time of lengthening, complication). We analyzed survival rate by the Kaplan-Meier method. The functional results were estimated by Musculoskeletal Tumor Society (MSTS) at 6 months postoperatively. The six items were scored on a 0(worst) to 5(best) scale, including pain, function, emotional acceptance, supports(brace, cane, crutches), walking ability and gait. Functional outcomes were ranked by score as follows: excellent(at least 23 points), good(15 to 22 points), fair(8 to 14 points), and poor(less than 8 points)¹⁴.

Conclusion

Although this study has limitations for short-term investigation, neoadjuvant chemotherapy and expandable prosthesis reconstruction we described seems to be an available option. This method provides well prognosis and function. Future larger series and multicenter cohort studies are imperative to better determine its performance, results and complications.

Declarations

Consent for publication

Not applicable.

Availability of data and materials

The datasets used and/or analysed during the current study are available from the corresponding author on reasonable request.

Competing interests

The authors declare that they have no competing interests.

Author contributions

JC as secondary surgeon made substantial contributions to conception and design, and acquisition of data. JH and WB is treating surgeon for cases involved. JH made substantial contributions to manuscript revising. GH offered initial advice and acted as one of the reviewers. JJ made substantial contributions to study design, drafting the manuscript and revising it critically for important intellectual content. MX and WW was involved in the conception of the study improving it with important intellectual content. All authors read and approved the final manuscript.

References

1. Brown HK, Tellez-Gabriel M, Heymann D. Cancer stem cells in osteosarcoma. *Cancer Lett.* 2017 Feb;386:189-195.
2. Junqi Huang, Wenzhi Bi, Gang Han, et al. The multidisciplinary treatment of osteosarcoma of the proximal tibia: a retrospective study. *BMC Musculoskelet Disord* 2018 Sep 5;19(1):315.
3. Eric L. Staals, Marco Colangeli, Nikolin Ali, Jose´ M. Casanova, Davide M. Donati, Marco Manfrini. Are Complications Associated With the Repiphysis1 Expandable Distal Femoral Prosthesis Acceptable for Its Continued Use? *Clin Orthop Relat Res.* 2015 Sep;473(9):3003-13.
4. Arkader A, Viola DC, Morris CD, Boland PJ, Healey JH. Coaxial extendible knee equalizes limb length in children with osteogenic sarcoma. *Clin Orthop Relat Res.* 2007 Jun;459:60-5.
5. Vivek Ajit Singh, Dinesh Earnest Kunasingh, Amber Haseeb, et al. Outcome of expandable endoprosthesis: A single centre retrospective review. *J Orthop Surg.* 2019;27(2):2309499019850313.
6. Ahmad M Shehadeh, Ula Isleem, Samer Abdelal, et al. Surgical Technique and Outcome of Custom Joint-Sparing Endoprosthesis as a Reconstructive Modality in Juxta-Articular Bone Sarcoma. *J Oncol.* 2019 Dec 26;2019:9417284.
7. Campanacci L, Manfrini M, Colangeli M, Ali N, Mercuri M. Long-term results in children with massive bone osteoarticular allografts of the knee for high-grade osteosarcoma. *J Pediatr Orthop.* 2010 Dec;30(8):919-27.
8. Daniel A Porney, Andrew S Bi, Robert A Christian, et al. Outcomes of expandable prostheses for primary bone malignancies in skeletally immature patients: a systematic review and pooled data analysis. *J Pediatr Orthop.* 2019 Oct 22.
9. Olga D Savvidou, Angelos Kaspiris, Leonidas Dimopoulos, et al. Functional and surgical outcomes after endoprosthetic reconstruction with expandable prostheses in children: a systematic review. *Orthopedics.* 2019 Jul;42(4):184-190.
10. Grimer RJ, Belthur M, Carter SR, Tillman RM, Cool P. Extendible replacements of the proximal tibia for bone tumours. *J Bone Joint Surg Br.* 2000 Mar;82(2):255-60.
11. Kang S, Lee JS, Park J, et al. Staged lengthening and reconstruction for children with a leg-length discrepancy after excision of an osteosarcoma around the knee. *Bone Joint J.* 2017 Mar;99-B(3):401-408.
12. Enneking WF, Spanier SS, Goodman MA. [A system for the surgical staging of musculoskeletal sarcoma.](#) 1980.. *Clin Orthop Relat Res* 2003 Oct;(415):4-18.
13. [Hai-Yong Ren, Ling-Ling Sun, Heng-Yuan Li, Zhao-Ming Ye.](#) Prognostic Significance of Serum Alkaline Phosphatase Level in Osteosarcoma: A Meta-Analysis of Published Data. *Biomed Res Int.* 2015; 2015 Nov(4): 160835.
14. Justin M M Cates. Simple staging system for osteosarcoma performs equivalently to the AJCC and MSTS systems. *J Orthop Res.* 2018 Oct;36(10):2802-2808.

15. Anderson ME. Update on survival in osteosarcoma. Orthop Clin North Am. 2016 Jan;47(1):283-292.
16. Marina NM, Smeland S, Bielack SS, et al. Comparison of MAPIE versus MAP in patients with a poor response to preoperative chemotherapy for newly diagnosed high-grade osteosarcoma (EURAMOS-1): an open-label, international, randomised controlled trial. Lancet Oncol. 2016 Oct; 17(10): 1396–1408.
17. Neyssa M Marina, Sigbjorn Smeland, Stefan S Bielack, et al. Comparison of MAPIE versus MAP in patients with a poor response to preoperative chemotherapy for newly diagnosed high-grade osteosarcoma (EURAMOS-1): an open-label, international, randomised controlled trial. Lancet Oncol. 2016 Oct;17(10):1396-1408.
18. Sigbjorn Smeland, Stefan S Bielack, Jeremy Whelan, et al. Survival and prognosis with osteosarcoma: outcomes in more than 2000 patients in the EURAMOS-1 (European and American Osteosarcoma Study) cohort. Eur J Cancer. 2019 Mar;109:36-50.
19. Kirsten K. Ness, Michael D. Neel, Sue C. Kaste, Catherine A. Billups, Victoria G. Marchese, Bhaskar N. Rao, Najat C. Daw. A comparison of function after limb salvage with non-invasive expandable or modular prostheses in children. Eur J Cancer. 2014 December ; 50(18): 3212–3220
20. T. Peel, D. May, K. Buising, K. Thursky, M. Slavin, P. Choong. Infective complications following tumour endoprosthesis surgery for bone and soft tissue tumours. EJSO. 2014 Sep;40(9):1087-94.
21. Akihiko Takeuchi, Norio Yamamoto, Katsuhiko Hayashi, et al. Joint-preservation surgery for pediatric osteosarcoma of the knee joint. Cancer Metastasis Rev. 2019 Dec;38(4):709-722.

Tables

Table 1
General information of the prostheses.

		Stem length(mm)	Prostheses length(mm)	Stem diameter(mm)
N	Effective	29	29	29
	Miss	0	0	0
Mean		147.76	180.86	11.48
Standard deviation		20.159	29.431	1.184
Minimum value		80	140	8
Maximum value		190	250	14

Table 2
Alkaline phosphatase examination

	N	minimum	maximum	mean
alkaline phosphatase at admission	29	123.5	485.2	234.806
alkaline phosphatase at discharge	29	83	319	133.64
Recurrence	3	261.5	714.8	424.1
Lung metastasis	1	1328.3	1328.3	1328.3

Figures

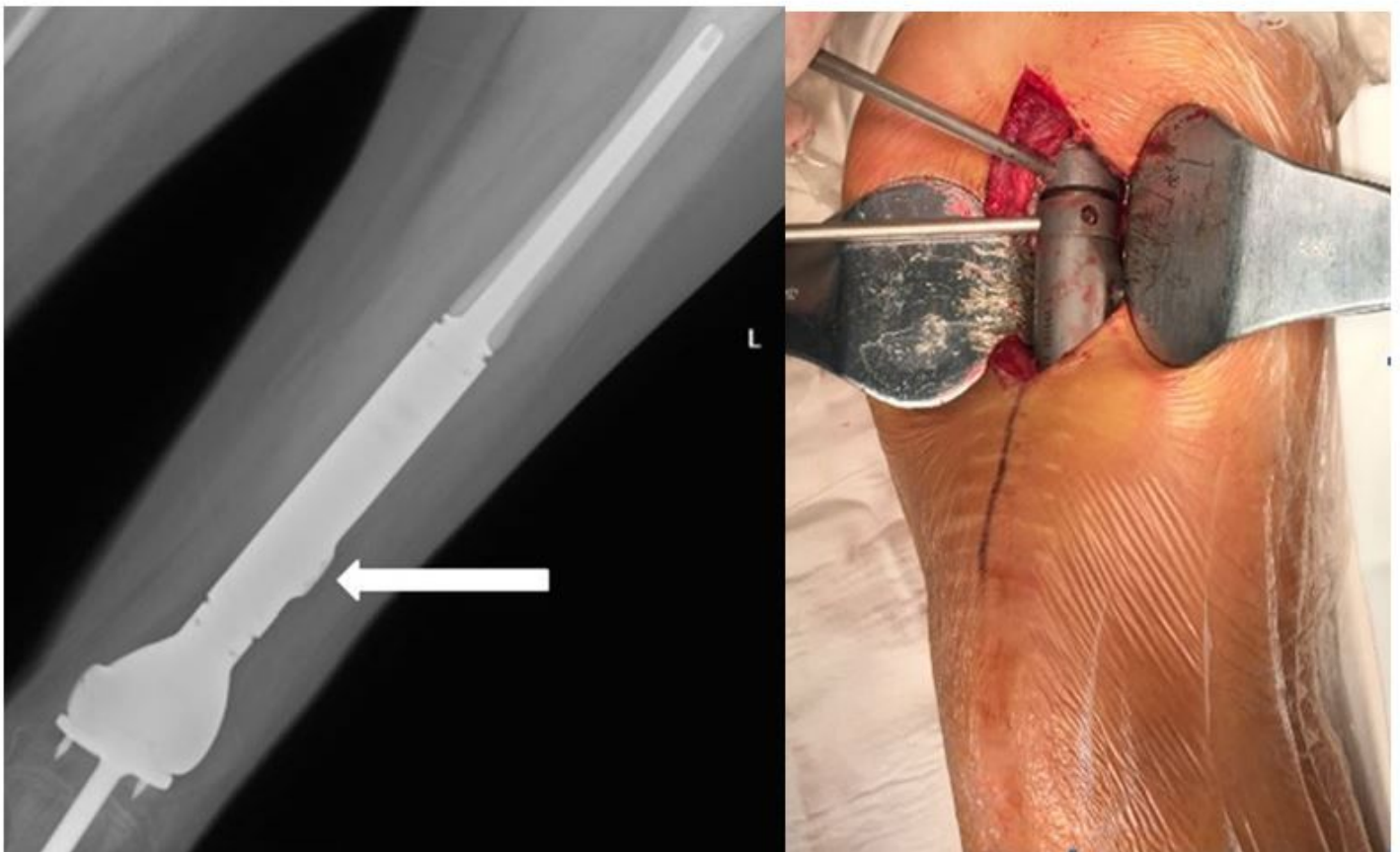


Figure 1

1A. X-ray shows the lengthening device (arrow). 1B. The titanium alloy tube was rotated to expand the prosthesis.

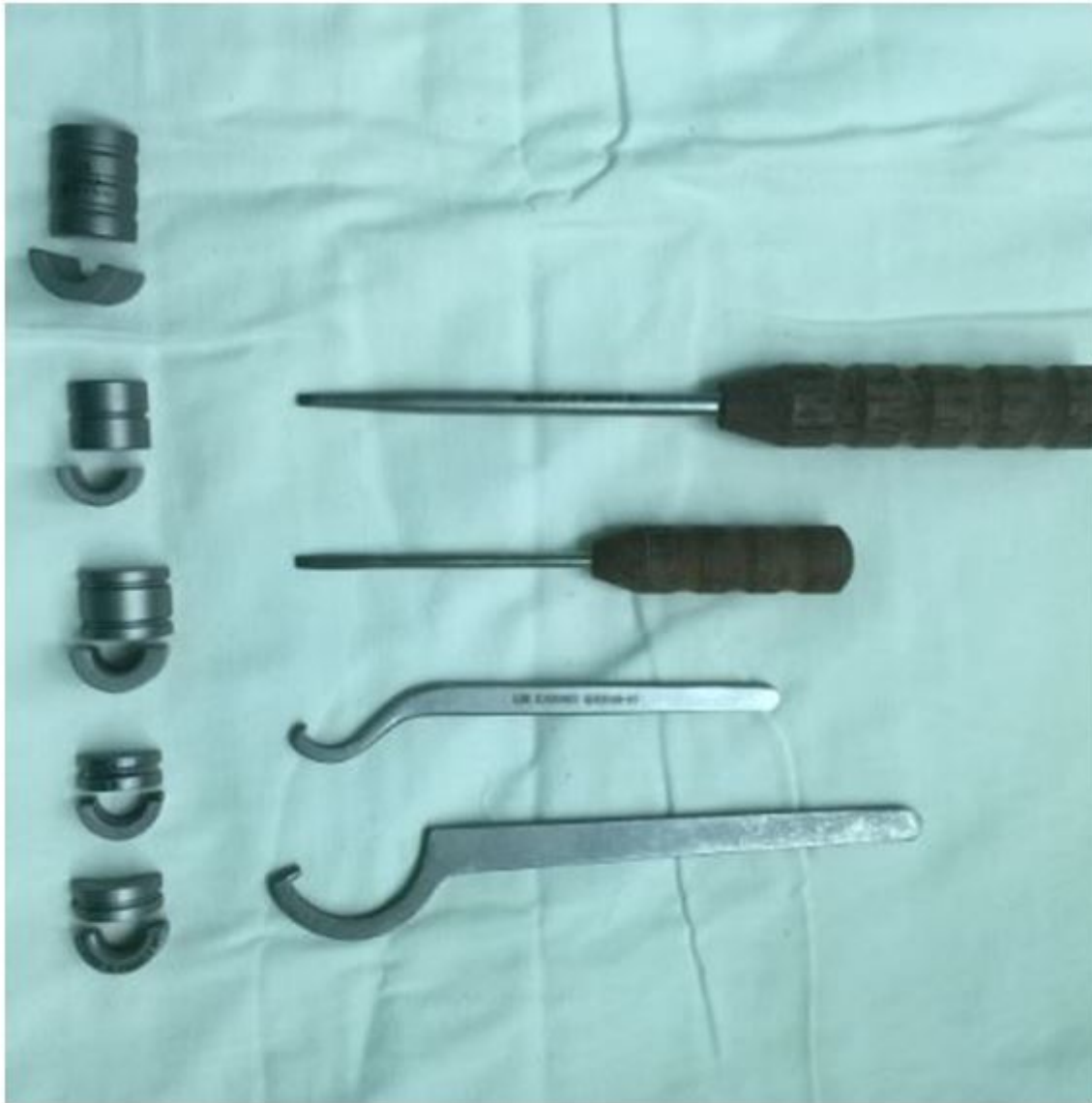

Figure 2

The different size of prolonged loop.

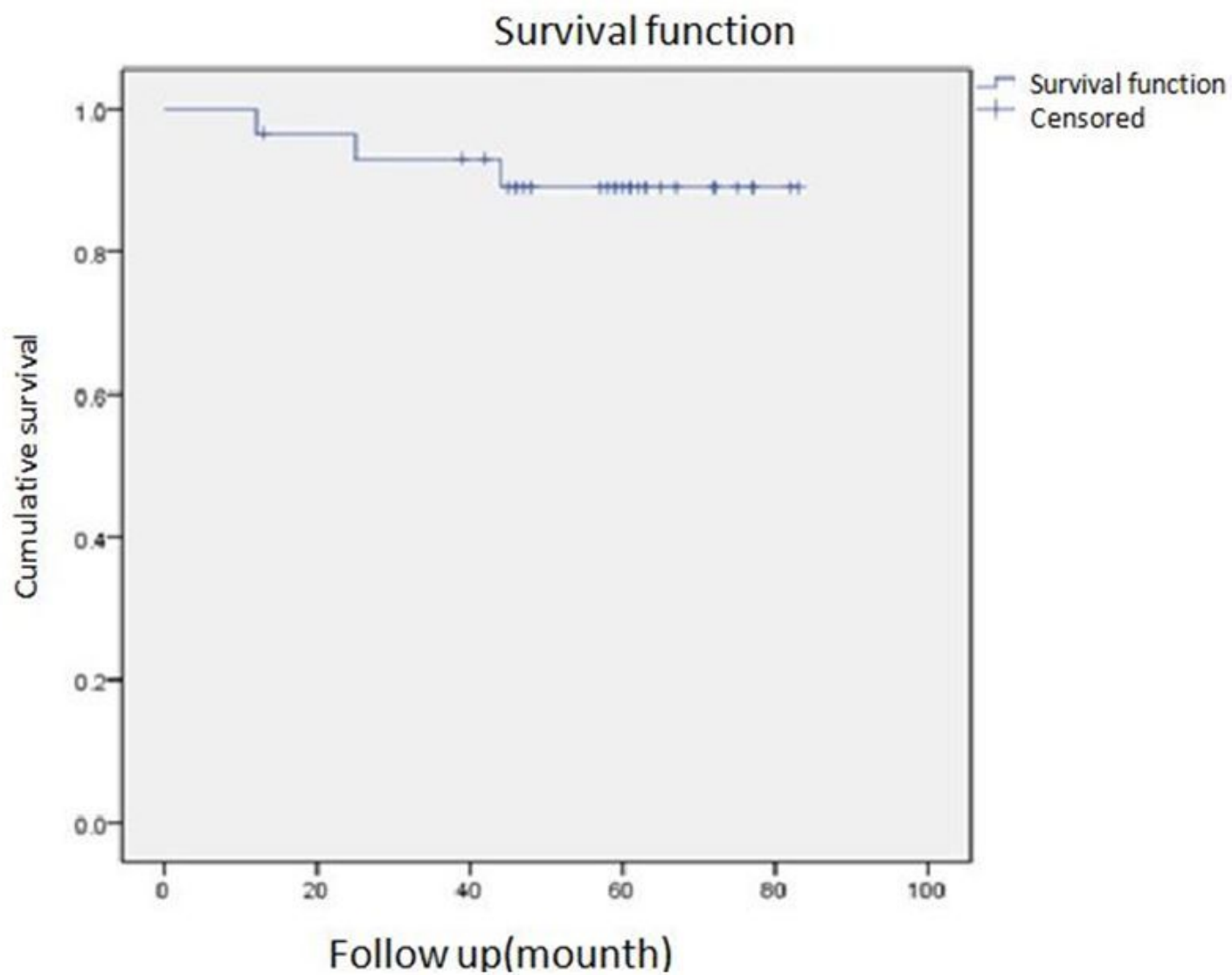


Figure 3

Kaplan-Meier survival curve of 29 patients shows the overall survival is 89.1% at 5 years.