

# Efficacy of Positron Emission Tomography in Diagnosis of Lateral Lymph Node Metastases in Patients with Rectal Cancer: A retrospective study

**Ryohei Yukimoto**

Department of Gastroenterological Surgery, Graduate School of Medicine, Osaka University

**Mamoru Uemura** (✉ [muemura@gesurg.med.osaka-u.ac.jp](mailto:muemura@gesurg.med.osaka-u.ac.jp))

Department of Gastroenterological Surgery, Graduate School of Medicine, Osaka University

**Takahiro Tsuboyama**

Department of Radiology, Graduate School of Medicine, Osaka University

**Tsuyoshi Hata**

Department of Gastroenterological Surgery, Graduate School of Medicine, Osaka University

**Shiki Fujino**

Department of Gastroenterological Surgery, Graduate School of Medicine, Osaka University

**Takayuki Ogino**

Department of Gastroenterological Surgery, Graduate School of Medicine, Osaka University

**Norikatsu Miyoshi**

Department of Gastroenterological Surgery, Graduate School of Medicine, Osaka University

**Hidekazu Takahashi**

Department of Gastroenterological Surgery, Graduate School of Medicine, Osaka University

**Taishi Hata**

Department of Gastroenterological Surgery, Graduate School of Medicine, Osaka University

**Hirofumi Yamamoto**

Department of Gastroenterological Surgery, Graduate School of Medicine, Osaka University

**Tsunekazu Mizushima**

Department of Gastroenterological Surgery, Graduate School of Medicine, Osaka University

**Akira Kida**

Department of Radiology, Jinsenkaï MI Clinic

**Mamoru Furuyashiki**

Department of Radiology, Jinsenkaï MI Clinic

**Yuichiro Doki**

Department of Gastroenterological Surgery, Graduate School of Medicine, Osaka University

**Hidetoshi Eguchi**

Department of Gastroenterological Surgery, Graduate School of Medicine, Osaka University



---

## Research Article

**Keywords:** positron emission tomography, lateral pelvic lymph node, rectal cancer, maximum standardized uptake value; metastases

**Posted Date:** December 10th, 2020

**DOI:** <https://doi.org/10.21203/rs.3.rs-119898/v1>

**License:**   This work is licensed under a Creative Commons Attribution 4.0 International License. [Read Full License](#)

---

# Abstract

**Background** The presence of lateral pelvic lymph node (LLN) metastasis is an essential prognostic factor in rectal cancer patients. Thus, preoperative diagnosis of LLN metastasis is clinically important to determine the therapeutic strategy. The aim of this study was to evaluate the efficacy of preoperative positron emission tomography/computed tomography (PET/CT) in the diagnosis of LLN metastasis.

**Methods** Eighty-six patients with rectal cancer who underwent LLN dissection at Osaka University were included in this study. The maximum standardized uptake value ( $SUV_{max}$ ) of the primary tumor and LLN were preoperatively calculated using PET/CT. Simultaneously, the short axis of the lymph node was measured using multi-detector row computed tomography (MDCT). The presence of metastases was evaluated by postoperative pathological examination.

**Results** Of the 86 patients, LLN metastases developed in the left, right, and both LLN regions in 7, 8, and 2 patients, respectively. The diagnosis of the metastases was predicted with a sensitivity of 84%, specificity 94%, positive predictive value 62%, and negative predictive value 98% when the cutoff value of the LLN  $SUV_{max}$  was set at 1.5. The cutoff value of the short axis set at 7 mm on MDCT was most useful in diagnosing LLN metastases, but  $SUV_{max}$  was even more useful in terms of specificity.

**Conclusions** The cutoff value of 1.5 for lymph node  $SUV_{max}$  in PET is a reasonable measure to predict the risk of preoperative LLN metastases in rectal cancer patients.

## Background

The presence of lateral pelvic lymph node (LLN) metastasis is an important prognostic factor in patients with lower rectal cancer [1]. The treatment strategy for LLN differs between Japan, Europe, and North America. In Europe and North America, LLN metastases are considered a metastatic disease, and total mesorectal excision (TME) with preoperative radiotherapy and chemotherapy is commonly performed [2,3]. Conversely, in Japan, LLN metastases are considered a local metastasis, and TME with lateral lymph node dissection (LLND) is performed as the standard surgical procedure for advanced lower rectal cancer.

Several previous reports have indicated the efficacy of LLND and its prognostic impact [4–7]. However, this surgical procedure has several potential disadvantages such as hemorrhage, prolonged surgical time, and risk of complications such as dysuria and sexual dysfunction [8,9]. Considering these potential complications, accurate preoperative prediction of LLN metastasis is required to identify the patients who are suitable for LLND. Currently, the preoperative diagnosis of lymph node metastases is mainly based on their size on computed tomography (CT) or magnetic resonance imaging (MRI) scans. A study conducted by the Japan Clinical Oncology Group (JCOG 0212) set the cutoff value for the short axis of a lymph node at 10 mm for the prediction of LLN metastases [9]. To date, several studies have focused on preoperative diagnosis of LLN metastases, and several diagnostic criteria have been indicated. These studies employed cutoff values between 5 mm and 10 mm, but the results varied [10–12]. Until now, no definitive conclusions have been drawn regarding the optimal cutoff value.

$^{18}F$ -fluorodeoxyglucose positron emission tomography/computed tomography ( $^{18}F$ -FDG PET/CT), a technique that reveals the biological variability of tumors, has been widely used to preoperatively evaluate rectal cancer in recent years [13,14]. This study aimed to assess the effectiveness of PET/CT in the preoperative diagnosis of LLN metastases. Furthermore, we investigated the optimal cutoff value for the prediction of such metastases.

# Methods

This study aimed to assess the effectiveness of PET/CT in the preoperative diagnosis of LLN metastases.

## Patients

This retrospective study aimed to assess the effectiveness of  $^{18}\text{F}$ -FDG PET/CT in the preoperative diagnosis of LLN metastases. We included patients with colorectal cancer who underwent elective surgery with LLND at Osaka University (Suita, Japan) from January 2011 to December 2019. The patients were excluded from the study if 1) they had not undergone preoperative  $^{18}\text{F}$ -FDG PET/CT scans ( $n=15$ ) and 2) they had been diagnosed with locally recurrent rectal cancer ( $n=11$ ).

## Positron emission tomography/computed tomography

Briefly,  $^{18}\text{F}$ -FDG PET/CT scans were obtained using the Discovery 710 (GE Health, Japan). The PET parameter included was the maximum standardized uptake value ( $\text{SUV}_{\text{max}}$ ).

Three-dimensional data acquisition was initiated 60 min after the injection of 4.8 MBq/kg of  $^{18}\text{F}$ -FDG. The  $\text{SUV}_{\text{max}}$  in the region of interest (ROI) was used as a representative value for the assessment of FDG uptake in the lesion.

## Multi-detector row computed tomography

Multi-detector row computed tomography (MDCT) scanning was performed at the same time as PET/CT. The MDCT parameters were as follows: tube voltage 120 kV, tube current 10–320 mA, automatic exposure control in the x, y, and z planes with a noise index of 11.0, rotation speed 0.6 s/r, helical pitch 17.5 mm/r, and slice thickness 0.625 mm. The reconstruction intervals were set to 0.5 mm. For the contrast-enhanced MDCT images, a nonionic contrast agent with an iodine concentration of 350 mg/mL (Optiray, Guerbet Japan, Osaka, Japan) was infused at a flow rate of 4.0 mL/s followed by saline at the same rate during arterial phase scanning with a dual-head injector (Stellant, Medrad, Indianola, PA, USA). The volume of injected contrast agent was 100 mL for patients weighing >49 kg, and 2.0 mL/kg for patients weighing <50 kg. To determine the arterial phase scan delay, a test injection with 10 mL of contrast agent and 10 mL of saline was performed at the same rate [15]. The imaging examinations using PET, followed by MDCT were performed on the same day.

## Evaluation of diagnostic performance

The diagnostic performance of  $\text{SUV}_{\text{max}}$  of PET was analyzed in the right and left LLN regions. The largest short axes of the lymph nodes in the left and right LLN regions were measured, and their  $\text{SUV}_{\text{max}}$  was also measured.

The short axes of lymph nodes in both regions were measured using the Universal Viewer Ver 6.0 (GE Healthcare) and ROI analysis was performed. The  $\text{SUV}_{\text{max}}$  of the largest short axis of the LLN and the primary tumor were measured (in the axial plane). These measured values were comparably evaluated during the postoperative pathology.

The receiver operating characteristic (ROC) curve was used to determine the optimal cutoff values of the lymph node  $\text{SUV}_{\text{max}}$  for the prediction of metastasis. The cutoff values were calculated with the highest sensitivity and the highest specificity located on the ROC curve at the highest point on the vertical axis and furthest point to the left on the horizontal axis.

## Statistical analysis

All analyses were performed using JMP Pro 14 for Windows (SAS Institute, USA). The pathological status and  $SUV_{max}$  of the LLN were collected to generate the ROC curve. Furthermore, the corresponding areas under the ROC curve (AUC) were calculated. The optimal cutoff was detected using Youden index. The sensitivity, specificity, positive predictive value (PPV), negative predictive value (NPV), false positive (FP), and false negative (FN) were determined based on the comparison of the PET/CT images using a cutoff value of 1.5 for lymph node  $SUV_{max}$  and short axis (10 and 7 mm) with histological diagnosis. To compare the sensitivity and specificity for the evaluation of two diagnostic tests, McNemar test was carried out. Results were considered statistically significant when  $p < 0.05$  was obtained.

## Results

In total, 112 patients underwent LLND at Osaka University during January 2011–December 2019. Of these, we excluded 15 patients who did not undergo preoperative  $^{18}F$ -FDG PET/CT scans and 11 who were diagnosed with locally recurrent rectal cancer. Finally, 86 patients (53 men and 33 women) who underwent LLND for primary rectal cancer were included in this study (Table 1).

Table 1  
Clinical and pathological characteristics of the patients and preoperative PET results

Characteristics	N = 86
Age (years)	61 (27–83)
Median/Range	
Sex (male/female)	53 (62%)/33 (38%)
Tumor location (Ra/Rb/P)	6/77/3
Preoperative chemotherapy (+/-)	68 (79%)/18 (21%)
Preoperative radiation therapy (+/-)	4 (5%)/82 (95%)
Tumor differentiation (well differentiated tubular adenocarcinoma/moderately differentiated tubular adenocarcinoma/squamous cell carcinoma/mucinous adenocarcinoma)	43/37/2/4
Pathological T stage (T0/Tis/T1/T2/T3/T4)	6/1/8/21/38/12
Pathological N stage (N0/N1/N2/N3)	49/15/5/17
LLN metastasis (+/-)	17 (20%)/69 (80%)
Location of LLN metastasis (263R/263L/273R/273L/283R/283L)	4/5/1/0/7/5
Pathological stage 0/I/IIa/IIb/IIc/IIIa/IIIb/IIIc/IV	6/22/16/1/3/4/15/16/3
Primary tumor SUV <sub>max</sub>	14.2 ± 6.76
LLN SUV <sub>max</sub>	1.4 ± 1.73
LLN, lateral pelvic lymph node; PET, positron emission tomography; SUV <sub>max</sub> , maximum standardized uptake value	
LLND was performed in 86 patients who underwent TME: 36 with low anterior resection, 24 with intersphincteric resection, 18 with abdominoperineal resection, and 5 with total pelvic exenteration.	

### Incidence Of Lateral Lymph Node Metastasis

LLN metastasis was identified in 17 patients (20%) based on histopathological examination of whom, 15 had unilateral lymph node metastasis and 2 had bilateral lymph node metastasis.

### Cutoff Value Evaluation Using ROC Curve Analysis

The ROC curve analysis for per-patient prediction of the lymph node status is shown in Fig. 1. ROC curve analysis of the LLN SUV<sub>max</sub>, primary SUV<sub>max</sub>, and LLN SUV<sub>max</sub>/primary SUV<sub>max</sub> ratio confirmed that LLN SUV<sub>max</sub> was the best

predictor for metastasis while primary  $SUV_{max}$  was the poorest among the three. The AUC of the LLN  $SUV_{max}$  was 0.91.

The best cutoff value of the LLN  $SUV_{max}$  was found to be 1.5, based on the ROC curve analysis.

Among the 86 patients (172 lymph nodes examined in total), the pathology examination results were positive in 17 patients (19 lymph nodes). Of these, the PET/CT results were negative in three patients (3 lymph nodes) when the cutoff value of the LLN was set at 1.5 (Table 2). Furthermore, the MDCT results were negative in 5 patients (5 lymph nodes) when the cutoff value of the short axis of the lymph node was set at 7 mm (Table 3). The ROC curve analysis for per-patient prediction of the short axis of the lymph node is shown in Fig. 2. The best cutoff value of the short axis of the lymph node was found to be 7 mm based on the ROC curve analysis.

Table 2  
Prediction of metastases using PET/CT based on histopathological diagnosis

	Histopathological diagnosis		
	Negative	Positive	Total
PET			
Negative	143	3	147
Positive	10	16	25
Total	153	19	172
The cutoff value of the lateral lymph node $SUV_{max}$ was set at 1.5.			
PET, positron emission tomography			

Table 3  
Prediction of metastases using MDCT based on histopathological diagnosis

	Histopathological diagnosis		
	Negative	Positive	Total
MDCT			
Negative	126	5	131
Positive	27	14	41
Total	153	19	172
The cutoff value of the short axis of the lymph node was set at 7 mm.			
MDCT, Multi-detector row computed tomography			

## Sensitivity, Specificity, PPV, And NPV

The diagnostic performance of PET when the  $SUV_{max}$  cutoff value was 1.5 was as follows: sensitivity, 84.2%; specificity, 93.5%; PPV, 61.5%; and NPV, 97.9%. Moreover, the diagnostic performance of MDCT with the cutoff value of 10 mm was as follows: sensitivity of 52.6%, specificity of 98.7%, PPV of 83.3%, and NPV 94.4%. At a cutoff value of 7 mm, the corresponding values for sensitivity, specificity, PPV, and NPV were 73.7, 82.4, 34.1, and 96.2%, respectively (Table 4).

Table 4  
Sensitivity, specificity, PPV, NPV, FP, and FN using PET/CT and MDCT

	<b>Sensitivity</b>	<b>Specificity</b>	<b>PPV</b>	<b>NPV</b>	<b>FP</b>	<b>FN</b>
$SUV_{max}$ Cutoff value 1.5	84.2%	93.5%	61.5%	97.9%	38.5%	2.1%
MDCT Cutoff value 10 mm (short axis)	52.6%	98.7%	83.3%	94.4%	16.7%	5.6%
MDCT Cutoff value 7 mm (short axis)	73.7%	82.4%	34.1%	96.2%	65.9%	3.8%
The cutoff value of the lateral pelvic lymph node $SUV_{max}$ was set at 1.5 and that of the short axis of the lymph nodes in MDCT was set at 10 mm and 7 mm.						
FP, false positive; FN, false negative; MDCT, Multi-detector row computed tomography; NPV, negative predictive value; PET, positron emission tomography; PPV, positive predictive value						

In patients with LLN metastases, there was no statistically significant difference in sensitivity between the short axis diameters, which set a cutoff value of MDCT and  $SUV_{max}$  at 7 mm, and that of PET at 1.5 ( $P = 0.157$ ). In patients without LLN metastases, there was a statistically significant difference in specificity between the short axis diameters, which set a cutoff value of MDCT and  $SUV_{max}$  at 7 mm, and that of PET at 1.5 ( $P < 0.01$ ).

## Discussion

In this retrospective study, we evaluated the effectiveness of PET/CT in the preoperative diagnosis of LLN metastasis. Lymph node metastasis is an important prognostic factor in patients with colorectal cancer [1]. In addition to the number of metastases, the sites of metastases also influence the prognosis. Specifically, LLN metastases are strongly associated with the prognosis in patients with rectal cancer [16]. Therefore, in Japan, LLND is regarded as a standard surgical procedure for these patients. However, to determine the necessity of LLND, the prognostic impact of LLN metastasis should be determined. At the same time, the clinical benefit of LLND should be weighed against the possible operation-related morbidities, especially the deterioration of voiding and sexual function due to nerve injury.

The size of the lymph nodes tends to be larger in patients with LLN metastasis than in those without metastasis; thus, the size of the node has been widely used as a reference in diagnosing metastases [5]. Several studies have



evaluated the accuracy of the preoperative prediction of metastasis based on the short axis diameter of a lymph node in MDCT or MRI. When the cutoff value of the short axis was set between 5 and 10 mm, the sensitivity, specificity, and accuracy rate were 50–85%, 41–75%, and 51–86%, respectively, showing high variability. Thus, it is unknown whether the patients with LLN metastasis are accurately identified before surgery based on the measurement of the short axis diameter of the lymph node. Recently, PET/CT has been widely used for the staging of rectal cancer and determining the treatment strategy in patients with rectal cancer [17]. In particular,  $SUV_{max}$  is commonly employed for  $^{18}F$ -FDG quantification. However, few studies have evaluated the efficacy of PET in diagnosing LLN metastases in patients with rectal cancer. The AUC was an indicator of the effectiveness of the examination. The present study showed that the AUC was 0.91. The results showed that PET may be a useful indicator to predict LLN metastases and could be useful in improving the accuracy, as shown in our data.

When we compared the sensitivity and specificity between diagnostics based on LLN short axis diameter and diagnostic method using the  $SUV_{max}$  value of LLN in patients with LLN metastases, we found a statistically significant difference in specificity between the short axis diameters, setting a cutoff value for MDCT at 7 mm and that of  $SUV_{max}$  for PET/CT at 1.5. To select the patients with LLN metastases for LLND, high specificity might be crucial. The results of this study and those of previous studies using CT and MRI for predicting metastases have been compared in Table 5 [8, 10, 11, 18–20]. Compared to the previous studies, the sensitivity was particularly higher and FN rates were lower in this study. This indicates that LLN  $SUV_{max}$  is highly useful for establishing the indication criteria for LLND. Recently, evaluation of MRI findings, including concentrations, shape, and the short axis of the lymph node has been reported with the goal of improving diagnostic accuracy. In addition, to improve the diagnostic accuracy, other factors suggestive of metastases, such as “an irregular border” and “mixed signal intensity or the presence of a high-intensity nodule within the lymph node,” should be considered. However, the evaluation of the MRI scans is primarily subjective and influenced by the experience of the assessors, making it difficult to establish an objective standard evaluation method [21].

Table 5  
Comparison of cutoff value, sensitivity, PPV, NPV, and accuracy across previous studies and present study

Author	Year	Number	Modality	Cutoff value	Sensitivity	Specificity	PPV	NPV	Accuracy
Arii et al <sup>18)</sup>	2006	53	CT	7 mm	22%	78%	8%	95%	75%
Arii et al <sup>18)</sup>	2006	53	MRI	7 mm	56%	97%	91%	81%	83%
Fujita et al <sup>8)</sup>	2009	210	CT	5 mm	62%	90%	64%	89%	84%
Akasu et al <sup>10)</sup>	2009	104	MRI	4 mm (short axis)	87%	87%	52%	97%	87%
Akasu et al <sup>10)</sup>	2009	104	MRI	3 mm (short axis)	93%	81%	45%	99%	83%
Matsuoka et al <sup>11)</sup>	2007	51	MRI	5 mm (short axis)	67%	83%	-	-	78%
Ishibe et al <sup>19)</sup>	2016	84	MRI	10 mm (short axis)	43.8%	98.5%	87.5%	88.2%	88.1%
Amano et al <sup>20)</sup>	2019	46	MRI	6 mm (short axis)	35.3%	97%	54.6%	94%	91.3%
Amano et al <sup>20)</sup>	2019	46	CT	6 mm (short axis)	35.3%	100%	100%	96.7%	94%
This study	2020	86	PET	SUV <sub>max</sub> 1.5	84.2%	93.5%	61.5%	97.9%	92.4%
This study	2020	86	MDCT	10 mm (short axis)	52.6%	98.7%	83.3%	94.4%	93.6%
This study	2020	86	MDCT	7 mm (short axis)	73.7%	82.4%	34.1%	96.2%	81.4%
CT, computed tomography; MDCT, Multi-detector row computed tomography; MRI, magnetic resonance imaging; NPV, negative predictive value; PET, positron emission tomography; PPV, positive predictive value; SUV <sub>max</sub> , maximum standardized uptake value									

The severity of preoperative lymph node metastasis may be underestimated due to slice intervals in CT and MRI scans. However, this may be compensated by PET analysis because it shows the biological variability of the lymph nodes. Considering this, metastases may be suspected in PET when FDG gets accumulated in the lymph nodes. Several studies on the prediction of lymph node metastases in patients with colorectal or rectal cancers have been

conducted, in which the cutoff value of SUV<sub>max</sub> was set within the range of 1.15–2.5 [22–25]. Although the present study focused only on the LLN, no significant difference was observed in the cutoff values when comparing the results of our study with those of other studies. However, the limitation of these studies was the small number of patients.

This study has several limitations. First, the number of patients who underwent LLND after preoperative PET was limited. Second, in this study, PET/CT evaluation was performed before the preoperative treatment in patients who underwent chemoradiation therapy or chemotherapy preoperatively. Therefore, the pathological findings were influenced by preoperative treatments. However, the complete response rate to preoperative treatment in this cohort was 7.3%. Moreover, LLN recurrence continues to be a significant problem after chemoradiotherapy plus TME in LLNs with a short axis of at least 7 mm on an MRI scan [12]. Therefore, it is unlikely that LLN metastases had completely disappeared post chemoradiotherapy.

## Conclusions

The diagnosis of the LLN metastases using PET/CT was predicted with the highest sensitivity when the cutoff value of the LLN SUV<sub>max</sub> was set at 1.5. Therefore, this criterion may be useful in determining indications for LLN metastasis, although a prospective study with a large sample size is warranted for a definitive conclusion.

## List Of Abbreviations

AUC, area under the curve; CT, computed tomography; <sup>18</sup>F-FDG, <sup>18</sup>F-fluorodeoxyglucose; FN, false negative; FP, false positive; LLN, lateral pelvic lymph node; LLND, lateral lymph node dissection; MDCT, multi-detector row computed tomography; MRI, magnetic resonance imaging; NPV, negative predictive value; PET, positron emission tomography; PPV, positive predictive value; ROC, receiver operating characteristic; ROI, region of interest; SUV<sub>max</sub>, maximum standardized uptake value; TME, total mesorectal excision

## Declarations

### Availability of data and materials

The datasets generated and/or analyzed during the current study are not publicly available, due to the privacy of the enrolled subjects, but these may be requested from the corresponding author, upon reasonable request.

### Ethics approval and consent to participate

The study was performed following the Declaration of Helsinki and Good Clinical Practice Guidelines, and All patients provided written informed consent before any form of clinical examination.

This retrospective study was approved by the Research Ethics Committee of Osaka University (approval ID: 12418-6).

### Consent for publication

Not applicable

### Availability of data and materials

Not applicable

### **Competing interests**

The authors declare that they have no competing interests

### **Funding**

Not applicable

### **Authors' contributions**

RY, MU and TT conceived and designed the study. TH, SF, TO, AK and MF collected patients' data. NM, HT, and TH analysed the data. TM and HY wrote the manuscript with contribution from all authors. YD and HE provided critical comments for this manuscript. All authors read and approved the final manuscript.

All authors read and approved the final manuscript.

### **Acknowledgements**

Not applicable

### **Authors' information**

**Department of Gastroenterological Surgery, Osaka University Graduate School of Medicine, Suita, Osaka, Japan**

Ryohei Yukimoto, Mamoru Uemura, Tsuyoshi Hata, Shiki Fujino, Takayuki Ogino, Norikatsu Miyoshi, Hidekazu Takahashi, Taishi Hata, Hirofumi Yamamoto, Tsunekazu Mizushima, Yuichiro Doki & Hidetoshi Eguchi

**Department of Radiology, Graduate School of Medicine, Osaka University, Suita, Osaka, Japan**

Takahiro Tsuboyama

**Department of Radiology, Jinsenai MI Clinic, Toyonaka, Osaka, Japan**

Akira Kida, Mamoru Furuyashiki

## **References**

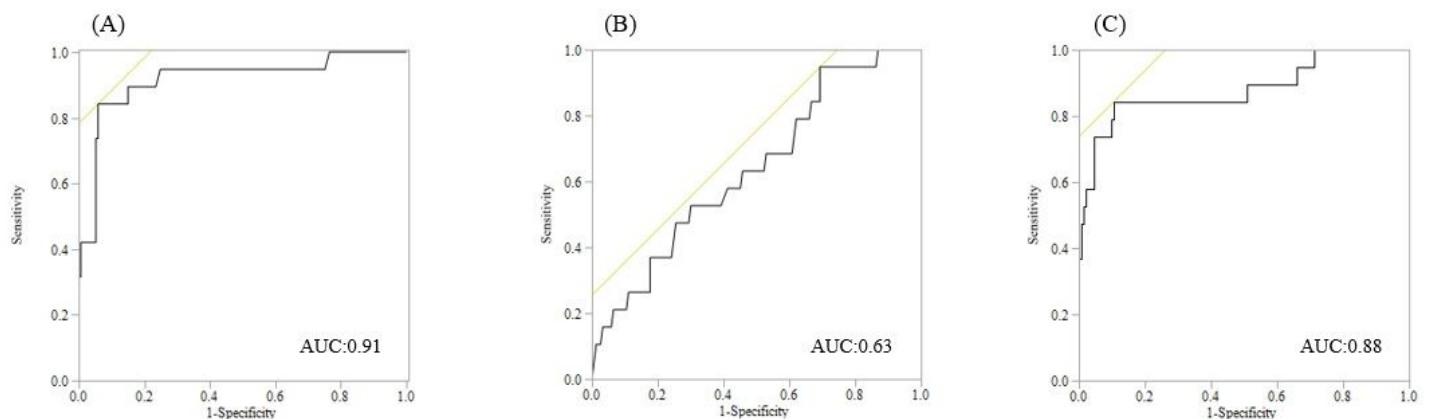
1. Wolmark N, Fisher B, Wieand HS. The prognostic value of the modifications of the Dukes' C class of colorectal cancer. An analysis of the NSABP clinical trials. *Ann Surg.* 1986;203:115-22. doi: [10.1097/0000658-198602000-00001](https://doi.org/10.1097/0000658-198602000-00001)
2. Van Gijn W, Marijnen CAM, Nagtegaal ID, Kranenbarg EM, Putter H, Wiggers T, et al. Preoperative radiotherapy combined with total mesorectal excision for resectable rectal cancer: 12-year follow-up of the multicentre, randomised controlled TME trial. *Lancet Oncol.* 2011;12(6):575-82. doi: [10.1016/S1470-2045\(11\)70097-3](https://doi.org/10.1016/S1470-2045(11)70097-3).
3. Georgiou P, Tan E, Gouvas N, Antoniou A, Brown G, Nicholls RJ, et al. Extended lymphadenectomy versus conventional surgery for rectal cancer: a meta-analysis. *Lancet Oncol.* 2009;10:1053-62. doi: [10.1016/S1470-2045\(09\)70224-4](https://doi.org/10.1016/S1470-2045(09)70224-4).

4. Moriya Y, Sugihara K, Akasu T, Fujita S. Importance of extended lymphadenectomy with lateral node dissection for advanced lower rectal cancer. *World J Surg.* 1997;21:728-32. doi: 10.1007/s002689900298.
5. Ueno H, Mochizuki H, Hashiguchi Y, Ishiguro M, Miyoshi M, Kajiwarra Y, et al. Potential prognostic benefit of lateral pelvic node dissection for rectal cancer located below the peritoneal reflection. *Ann Surg.* 2007;245:80-7. doi: 10.1097/01.sla.0000225359.72553.8c.
6. Sugihara K, Kobayashi H, Kato T, Mori T, Mochizuki H, Kameoka S, et al. Indication and benefit of pelvic sidewall dissection for rectal cancer. *Dis Colon Rectum.* 2006;49:1663-72. doi: 10.1007/s10350-006-0714-z.
7. Fujita S, Mizusawa J, Kanemitsu Y, Ito M, Kinugasa Y, Komori K, et al. Mesorectal Excision With or Without Lateral Lymph Node Dissection for Clinical Stage II/III Lower Rectal Cancer (JCOG0212): A Multicenter, Randomized Controlled, Noninferiority Trial. *Ann Surg.* 2017;266:201-7. doi: 10.1097/SLA.0000000000002212.
8. Nagawa H, Muto T, Sunouchi K, Higuchi Y, Tsurita G, Watanabe T, et al. Randomized, controlled trial of lateral node dissection vs. nerve-preserving resection in patients with rectal cancer after preoperative radiotherapy. *Dis Colon Rectum.* 2001;44:1274-80. doi: 10.1007/BF02234784.
9. Fujita S, Akasu T, Mizusawa J, Saito N, Kinugasa Y, Kanemitsu Y, et al. Postoperative morbidity and mortality after mesorectal excision with and without lateral lymph node dissection for clinical stage II or stage III lower rectal cancer (JCOG0212): Results from a multicentre, randomised controlled, non-inferiority trial. *Lancet Oncol.* 2012;13:616-21. doi: 10.1016/S1470-2045(12)70158-4.
10. Akasu T, Iinuma G, Takawa M, Yamamoto S, Muramatsu Y, Moriyama N. Accuracy of high-resolution magnetic resonance imaging in preoperative staging of rectal cancer. *Ann Surg Oncol.* 2009;16:2787-94. doi: 10.1245/s10434-009-0613-3.
11. Matsuoka H, Nakamura A, Masaki T, Sugiyama M, Nitatori T, Ohkura Y, et al. Optimal diagnostic criteria for lateral pelvic lymph node metastasis in rectal carcinoma. *Anticancer Res.* 2007;27(5B):3529-33.
12. Ogura A, Konishi T, Cunningham C, Garcia-Aguilar J, Iversen H, Toda S, et al. Neoadjuvant (Chemo)radiotherapy with total mesorectal excision only is not sufficient to prevent lateral local recurrence in enlarged nodes: result of the multicenter lateral node study of patients with low cT3/4 rectal cancer. *J Clin Oncol.* 2019;37:33-43. doi: 10.1200/JCO.18.00032.
13. Vriens D, de Geus-Oei LF, van der Graaf WT, Oyen WJ. Tailoring therapy in colorectal cancer by PET-CT. *Q J Nucl Med Mol Imaging.* 2009;53:224-44.
14. Watanabe A, Harimoto N, Yokobori T, Araki K, Kubo N, Igarashi T, et al. FDG-PET reflects tumor viability on SUV in colorectal cancer liver metastasis. *Int J Clin Oncol.* 2020;25:322-29. doi: 10.1007/s10147-019-01557-0.
15. Ogino T, Takemasa I, Horitsugi G, Furuyashiki M, Ohta K, Uemura M, Nishimura J, Hata T, Mizushima T, Yamamoto H, Doki Y, Mori M. Preoperative evaluation of venous anatomy in laparoscopic complete mesocolic excision for right colon cancer. *Ann Surg Oncol.* 2014 Jun;21 Suppl 3:S429-35. doi: 10.1245/s10434-014-3572-2.
16. Min BS, Kim JS, Kim NK, Lim JS, Lee KY, Cho CH, et al. Extended lymph node dissection for rectal cancer with radiologically diagnosed extramesenteric lymph node metastasis. *Ann Surg Oncol.* 2009;16:3271-8. doi: 10.1245/s10434-009-0692-1.
17. Gearhart SL, Frassica D, Rosen R, Choti M, Schulick R, Wahl R. Improved staging with pretreatment positron emission tomography/computed tomography in low rectal cancer. *Ann Surg Oncol.* 2006;13:397-404. doi: 10.1245/ASO.2006.04.042.
18. Arii K, Takifuji K, Yokoyama S, Matsuda K, Higashiguchi T, Tominaga T, et al. Preoperative evaluation of pelvic lateral lymph node of patients with lower rectal cancer: comparison study of MR imaging and MDCT in 53

patients. *Langenbecks Arch Surg.* 2006;391:449-54. doi: 10.1007/s00423-006-0066-0

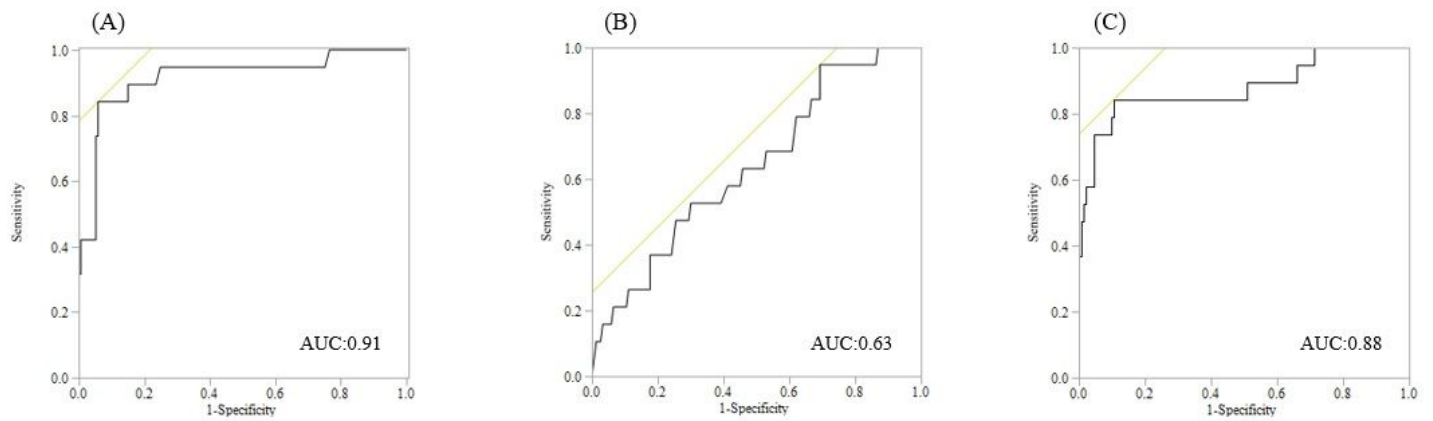
19. Ishibe A, Ota M, Watanabe J, Suwa Y, Suzuki S, Kanazawa A, et al. Prediction of Lateral Pelvic Lymph-Node Metastasis in Low Rectal Cancer by Magnetic Resonance Imaging. *World J Surg.* 2016;40:995-1001. doi: 10.1007/s00268-015-3299-7.
20. Amano K, Fukuchi M, Kumamoto K, Hatano S, Ohno H, Osada H, et al. Pre-operative Evaluation of Lateral Pelvic Lymph Node Metastasis in Lower Rectal Cancer: Comparison of Three Different Imaging Modalities. *J Anus Rectum Colon.* 2020;4:34-40. doi: 10.23922/jarc.2019-022.
21. Brown G, Richards CJ, Bourne MW, Newcombe RG, Radcliffe AG, Dallimore NS, et al. Morphologic predictors of lymph node status in rectal cancer with use of high-spatial-resolution MR imaging with histopathologic comparison. *Radiology.* 2003;227: 371-377. doi: 10.1148/radiol.2272011747.
22. Dahmarde H, Parooie F, Salarzaei M. Is [ <sup>18</sup>F ] FDG pet / Ct an accurate way to detect Lymph Node Metastasis in colorectal Cancer: a systematic review and meta-analysis. *Contrast Media Mol Imaging.* 2020; 2020:5439378. <https://doi.org/10.1155/2020/5439378>
23. Tsunoda Y, Ito M, Fujii H, Kuwano H, Saito N. Preoperative diagnosis of lymph node metastases of colorectal cancer by FDG-PET/CT. *Jpn J Clin Oncol.* 2008;38:347-53. doi: 10.1093/jjco/hyn032.
24. Chen R, Wang Y, Zhou X, Huang G, Liu J. Preoperative PET/CT <sup>18</sup>F-FDG standardized uptake by lymph nodes as a significant prognostic factor in patients with colorectal cancer. *Contrast Media Mol Imaging.* 2018;2018:5802109. doi: 10.1155/2018/5802109.
25. Ishihara S, Kawai K, Tanaka T, Kiyomatsu T, Hata K, Nozawa H, et al. Diagnostic value of FDG-PET/CT for lateral pelvic lymph node metastasis in rectal cancer treated with preoperative chemoradiotherapy. *Tech Coloproctol.* 2018;22:347-54. doi: 10.1007/s10151-018-1779-0.

## Figures



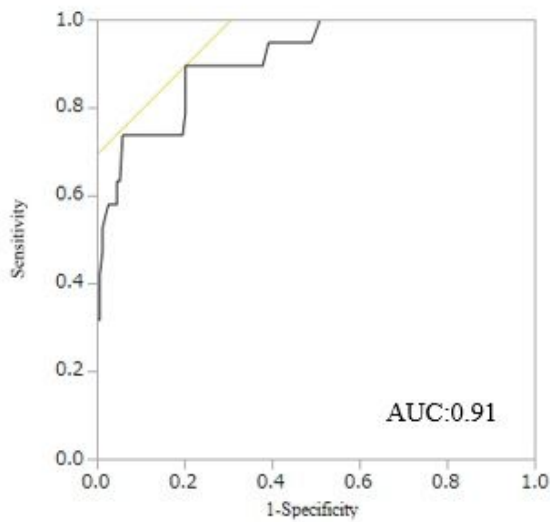
**Figure 1**

a. Receiver operating characteristic (ROC) curve of the maximum standardized uptake value (SUVmax) in the lateral pelvic lymph nodes as a predictor of pathological metastasis for lateral pelvic lymph nodes. b. ROC curve of the SUVmax in the primary tumor as a predictor of pathological metastasis for lateral pelvic lymph nodes. c. ROC curve of the SUVmax in the lateral pelvic lymph nodes/primary tumor as a predictor of pathological metastasis for lateral pelvic lymph nodes.



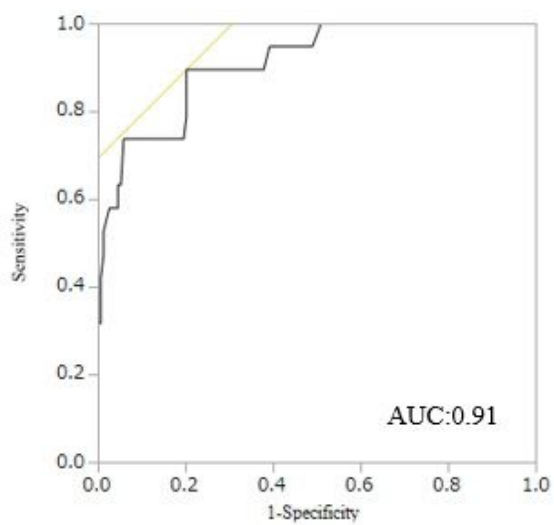
**Figure 1**

a. Receiver operating characteristic (ROC) curve of the maximum standardized uptake value (SUVmax) in the lateral pelvic lymph nodes as a predictor of pathological metastasis for lateral pelvic lymph nodes. b. ROC curve of the SUVmax in the primary tumor as a predictor of pathological metastasis for lateral pelvic lymph nodes. c. ROC curve of the SUVmax in the lateral pelvic lymph nodes/primary tumor as a predictor of pathological metastasis for lateral pelvic lymph nodes.



**Figure 2**

Receiver operating characteristic curves of the short axes of lateral pelvic lymph nodes as a predictor of pathological metastasis for lateral pelvic lymph nodes.



**Figure 2**

Receiver operating characteristic curves of the short axes of lateral pelvic lymph nodes as a predictor of pathological metastasis for lateral pelvic lymph nodes.