Research Square

Preprints are preliminary reports that have not undergone peer review. They should not be considered conclusive, used to inform clinical practice, or referenced by the media as validated information.

Artemisia Annua Ethanolic Extract Mitigated Small Intestinal Lesions in Hamsters Infected With Giardia Lamblia Possibly Through Modulation of Mucosal Immunity

Tarek Hamdy Abd-Elhamid (tabdelhamid@aun.edu.eg)
Assiut University Faculty of Medicine https://orcid.org/0000-0002-3920-6474

Iman A. M. Abdel-Rahman
South Valley University Faculty Of Pharmacy

Amany Refaat Mahmoud
Assiut University Faculty of Medicine

Samer S. Fouad
South Valley University Qena Faculty of Medicine: South Valley University Faculty of Medicine

Osama H. Abdella
South Valley University Qena Faculty of Medicine: South Valley University Faculty of Medicine

Asmaa M. El-Kady
South Valley University Qena Faculty of Medicine: South Valley University Faculty of Medicine

---

Research

Keywords: Giardia lamblia infection, Artemisia annua extracts, Nitric Oxide, IL 6, TNF-α, INF-γ

Posted Date: December 3rd, 2020

DOI: https://doi.org/10.21203/rs.3.rs-117752/v1

License: This work is licensed under a Creative Commons Attribution 4.0 International License.
Read Full License

Abstract

Giardiasis is a worldwide health problem caused by *Giardia lamblia.* Unfortunately, *G. lamblia* developed drug resistance against commonly used therapeutic agents. *Artemisia annua* (*A. annua*) derivatives showed therapeutic efficacy against a number of parasitic infestations. Here, we aimed to elucidate the effect of *A. annua* on giardiasis-induced small intestinal changes in hamsters. Thirty-two hamsters were divided into 4 groups. GI: Uninfected, GII: infected with *G. lamblia* cysts and untreated, GIII: infected and treated with metronidazole, served as a positive control, and GIV: infected and treated with the *A. annua* ethanolic extract. The efficacy of the extract was assessed by trophozoite counts, serum cytokine levels and histopathology. Infection of gerbils with *G. lamblia* cysts significantly decreased serum nitrite, while increased serum IL-6, INF-γ and TNF-α. Additionally, *G. lamblia* increased intraepithelial lymphocytes (IEL) while reduced villus heights, goblet cell (GC) number and muscularis externa (ME) thickness. Immunohistochemical analysis showed that *G. lamblia* increased inducible nitric oxide synthase (iNOS) and caspase-3 expression. In contrast, treating infected animals with *A. annua* significantly reduced the mean trophozoite counts, serum nitrite, IL-6, INF-γ, TNF-α levels and IEL numbers while increased villus heights, GC numbers and ME thickness. Moreover, A. annua reversed giardiasis-induced changes in iNOS and caspase-3 expression. In conclusion; we showed clearly that *A. annua* extract reduced the severity and morphological changes of giardiasis possibly through modulation of nitric oxide production and mucosal immunity. These effects were comparable to effects of metronidazole. Therefore, we assume that A. annua extracts could be used as adjuvant therapy during treatment of giardiasis.

Introduction

Giardiasis is one of the most common human intestinal protozoal infections worldwide. It is caused by *Giardia lamblia* (also known as *Giardia duodenalis*) which is a flagellated protozoan infecting the small intestine of man [1]. Globally, approximately 280 million people are infected with Giardia every year [2]. The prevalence rates in developing countries were estimated at 20-30 % and in developed countries at 2-5% [3]. In Egypt, the prevalence rate of giardiasis ranges from 10 to 35% making Egypt an endemic region according to the criteria of the World Health Organization (WHO) [4-7].

Giardiasis is a major health problem. It is transmitted through the ingestion of cysts in food and water. Giardiasis has highly variable clinical manifestations ranging from asymptomatic, to acute or chronic diarrheal disease associated with abdominal pain and nausea [8]. Chronic giardiasis causes severe diarrhea, malabsorption, and loss of weight particularly in children [9, 10] with a negative impact on their cognitive abilities [11]. In immunocompromised patients, infectious diseases are of major concern because intestinal immunity is compromised making infections, like giardiasis, more virulent [12].

A large body of evidence has described histopathological changes in the intestine with giardiasis. The organism is usually found on the villus surface or between the intestinal villi [13]. Infection with *giardia* is associated with mucosal inflammation, intraepithelial inflammatory cell infiltration, and changes in the villus architecture [14]. Additionally,LL Ventura, DR Oliveira, JC Viana, JF Santos, MV Caliari and MA

Gomes [15] have observed increased mucus production in the intestine of animal model of giardiasis. Moreover, giardiasis has been linked with enterocyte apoptosis compromising the integrity of the mucosal barrier [16, 17]. Furthermore, infection with giardia alters the morphology of enteric neurons and reduces the thickness of the external muscle layer of the intestine [18].

Previous studies of Giardiasis in rodents have implicated interleukin-6 (IL-6) in promoting immunity against *Giardia*. In this regard, elevated IL-6 mRNA levels have been seen in mice infected with giardia. Interestingly, IL-6-deficient mice have a diminished ability to clear the infection caused by *G. intestinalis* [19, 20]. Mice studied in these experiments were able to produce intestinal anti-trophozoite IgA. These observations suggest that IL-6 exerts its anti-giardia effect through IgA independent mechanism. Recently, dendritic cells have been identified as a source of IL-6 that promotes clearance of *Giardia* infection in mice [21, 22]. These data highlight an important role for IL-6 in controlling giardiasis.

There is an evidence that intestinal nitric oxide (NO) contributes to the host clearance of *Giardialamblia* trophozoites. NO is produced from arginine amino acid by nitric oxide synthases (NOSs) [23]. In fact, NO production is not a favorite for many pathogens including giardia due to its cytotoxicity [24, 25]. Interestingly, *Giardia* trophozoites limits NO production by either compete with the host for arginine [26] or increase the host production of arginase that decrease arginine availability [27]. While these effects reduce the dietary arginine available for absorption by the host, they are important for trophozoite survival by reducing NO production [28]. Therefore, promoting NO production by different therapeutics could be a new strategy for controlling giardiasis.

Drugs such as; furazolidone, quinacrine, paromomycin, benzimidazole compounds, 5-nitroimidazole compounds, nitazoxanide, have long been used as a therapy for giardiasis [29]. Although they are effective, they have been associated with undesirable effects such as gastrointestinal upset, haptic and renal toxicity, dermatitis, leucopenia, ototoxicity [30] severe pancreatitis [31] and high incidences of congenital anomalies [29]. Moreover, several studies have reported resistance of *Giardia lamblia* protozoa to these compounds and the number of cases is likely to increase [32, 33]. Consequently, there is a need for more studies into medicinal plants or herbs for alternative regimens against giardiasis.

Over thousands of years, plants have been used to treat human diseases. Their contents of active ingredients are interesting for many research groups. Plants in the genus *Artemisia*, a worldwide growing plant, have been used to treat various disease conditions [34]. They are a rich source of bioactive natural substances that have medical importance for both humans [35] and animals [36]. Artemisinin, the main sesquiterpene isolated from *Artemisia annua*, has been shown highly effective in the treatment of quinine-resistant malaria [37]. Moreover, Artemisia annua is a potent antioxidant medication, an effect attributed to its high phenolic content [38]. Recently, consumption of the extracts and the essential oil of Artemisia annua in treatment of various parasitic infections has received much attention. In this regard, Artemisia annua has showed effectiveness against trypanosomiasis [39], schistosomiasis [40], toxoplasmosis [41], leishmaniasis [42, 43] and coccidiosis [44]. Additionally, *in vitro* experiments have shown that extracts of Artemisia annua plant were effective against *Giardia lambliain vitro* [45].

To further elucidate the protective effect of Artemisia annua against *giardiasis*-induced small intestinal lesion, we investigated whether the ethanolic extracts of Artemisia annua were effective against *Giardialamblia* in an animal model of giardiasis and compared its protective effect on the small intestinal lesion to the effect of metronidazole, the currently used drug for giardiasis.

Materials And Methods

This is a case-control study conducted at the animal house and Parasitology Department, Faculty of Medicine, South Valley University, Qena, Egypt. All experiments in this study were conducted according to the Animal Care and Use Committee at the Faculty of Medicine, South Valley University, Qena, Egypt. The study design was approved by the Institutional Research Committee at the Faculty of Medicine, South Valley University, Qena, Egypt.

Animals:

Thirty-two male golden hamsters, ageing 3–4 weeks and weighing 150– 200 g each, were obtained from the animal house at Theodore Bilharz Research Institute (TBRI), Giza Egypt. Hamsters were bred under specified pathogen-free conditions. To ensure that hamsters are free from intestinal parasites, stool samples were examined for three consecutive days before starting the experiments.

Preparation of the *Artemisia annua* extracts:

Artemisia annua ethanolic extract was prepared according to the method described previously [46]. *Artemisia annua* was powdered mechanically. Ethanolic extracts were prepared by maceration of 200 g powdered plant material with 1 Liter of 95% ethanol. Plant material was allowed to macerate for 16 h at room temperature and then filtered. The process was repeated three times. The combined filtrates were evaporated to dryness in a rotary evaporator under reduced pressure, to give the crude ethanolic extract. The obtained solvent-free residue (16 g) was stored at $4^{o}C$ for subsequent preparation of the required doses.

Preparation of the parasite for infection:

G. lamblia cysts were collected from the stool of patients who attended the outpatient clinics in the university hospitals, South Valley University, Qena, Egypt. All stool specimens were processed immediately at the parasitology laboratory. *Giardia* cyst viability was assessed using 0.1 %eosin vital staining. Cysts were counted in 0.1 ml of sediment and the concentration process was repeated with more stool samples until the suspension contained about 10,000 cysts/mL of phosphate-buffered saline. Animals of groups II, III, and IV were infected orally each with 1 ml phosphate-buffered saline containing 10000 cysts [47].

Experimental groups:

Animals were equally divided into 4 groups, 8 animals each. GI included uninfected animals. Animals of GII were infected with 1 ml phosphate-buffered saline containing 10000 giardia cysts orally [47]. GIII animals were infected and treated with metronidazole 120 mg/kg body weight orally for 2 successive days and served as a positive control [48]. Animals of GIV were infected and treated with the ethanolic extract of Artemisia annua at a dose of 400 mg/kg [49] for 3 consecutive days. Three weeks post-infection, animals were administered medication orally using stainless steel esophageal tube. Animals of all groups were killed 2 weeks after treatment as previously reported [50] to evaluate the drug efficacy. Doses of metronidazole and *Artemisia annua* ethanolic extracts were selected according to previously published reports [48, 49].

Assessment of the efficacy of the extract:

Parasitological studies:

Two weeks after treatment, stool samples were collected from each hamster for 3 days before scarification for intermittent discharge of cysts. Ten high power fields were examined for each sample and the mean number of cysts/HPF (high power field) was calculated as previously described [51]. The small bowel was removed and the duodenal contents were subjected to parasitological examination in order to count the number of *G. lamblia* trophozoites in five successive fields/animal as previously described [52]

Biochemical study:

Blood samples were collected, and sera were separated and stored at −20°C till used. Levels of nitric oxide (NO) were determined by a direct method using an atomic absorption spectrophotometer according to previously published methods [53]. The level of interleukin-6 (IL-6) was determined using Rat IL-6 ELISA kit according to the manufacturer's protocol (Koma Biotech Inc. Cat. No. K0331229). The Level of TNF-α was determined using an ELISA kit purchased from (Koma Biotech Inc., Cat No. K0331196) and we followed the manufacturer's protocol. Finally, levels of INF γ was determined using the ELISA kit purchased from (Koma Biotech Inc., Cat No. K0331209) following manufacturer's instructions.

Histopathological examination:

Specimens of 2-5 cm from the proximal part of the small intestine (duodenum and jejunum) removed from sacrificed hamsters were fixed in 10% formalin and embedded in paraffin. Sections at 5-micrometer thickness were stained with hematoxylin and eosin and Periodic Acid Schiff (PAS) and hematoxylin as previously described [54].

Assessment of villi length and muscularis externa thickness:

Three animals were used for the assessment of these parameters. A total of 15 images of random fields/group were used. Images captured at 100x magnification were used for assessment of the villi

length while we used images at 400x magnification for measuring muscularis externa thickness using Fiji ImageJ software version 1.52p.

Assessment of intraepithelial Lymphocytes (IEL) and goblet cell number:

Sections from 3 animals were used for the assessment of IEL and goblet cell number. Images of random fields taken from small intestinal sections stained with hematoxylin and eosin and captured at 200x magnification were used for assessing IEL. We counted 2500 enterocytes and IEL and then the proportion of IEL/100 enterocytes was calculated [55]. For goblet cell count, fifteen images of random fields of sections stained with Periodic acid Schiff (PAS) and hematoxylin were used. In each image, we counted the number of goblet cells and enterocytes and then we calculate the proportion of goblet cells/100 enterocytes.

Immunohistochemistry:

Paraffin sections of the small intestine of different groups were deparaffinized and rehydrated with descending grades of ethanol. Sections were boiled in citrate buffer (pH 6.0) in a microwave for epitope retrieval. Then, endogenous peroxidases were blocked with 3% hydrogen peroxide in ethanol. Sections were incubated with anti-caspase-3 antibodies (Thermo Scientific, USA, dilution 1:500) or anti-inducible nitric oxide synthase (iNOS) polyclonal antibodies (Thermo Scientific, USA, dilution 1:50) for 60 minutes at room temperature. Next, sections were washed with TBS containing 0.05% tween-20 (TBS-T). Afterward, sections were incubated with HRP conjugated goat anti-rabbit secondary antibodies (Vivantis Technologies, Malaysia) at a dilution of 1:5000, for 1 h at 4 °C. After washing in TBS-T, the color was developed by incubating sections with 0.05% diaminobenzidine (DAB) and 0.01% H_2O_2 for 3 minutes. For negative control, we omitted the primary antibodies during staining of some slides. Images were captured using a Leica light microscope equipped with a digital camera in the Histology and Cell Biology department Assiut University Faculty of Medicine, Assiut Egypt.

Statistical analysis:

The collected data were analyzed by SPSS (Statistical Package for Social Sciences) version 20 for windows. All values were expressed as mean ± standard deviation (SD). Differences between groups were determined using one-way ANOVA test to compare the mean values between treated and control groups for different variables by the Bonferroni post hoc test. Differences were considered significant when $p<0.05$.

Ethical consideration:

Experiments on animals were performed in accordance with the ethical animal guidelines and regulations set by the Animal Care Committee of the Faculty of Medicine, South Valley University, and guidelines of the National Institute of Health for the Care and Use of Laboratory Animals. Ethical approval was granted by the Research and Ethics Committee of the Faculty of Medicine, South Valley University.

Results

Giardia lamblia is a causative parasite of Giardiasis. This disease condition is highly prevalent in human especially children and malnourished individuals [56, 57]. Currently, metronidazole is the drug of choice in the treatment of giardiasis. However, its therapeutic efficacy against giardiasis decreased due to the developing of resistance [58]. Here, we sought to investigate the effect of *Artemisia annua* on *Giardia lamblia*-infected hamster and compare its effects on the small intestinal lesion to the effect of metronidazole administration.

Parasitological analysis:

Oral application of ten thousand *Giardia lamblia* cysts/animal led to the establishment of giardiasis in hamsters. This was confirmed by finding *Giardia lamblia* cysts in feces of infected animals. Interestingly, the examination of small intestine belonging to metronidazole and *Artemisia annua* ethanolic extracts-treated groups for trophozoite count revealed that these animals had significant reductions in trophozoite count compared to the infected untreated group. Importantly, treating animals with *Artemisia annua* significantly reduced the trophozoites count compared to animals treated with metronidazole (98.3 % and 92.5%, respectively) (Table 1 and Fig. 1). These data suggest that *Artemisia annua* extracts were more effective in reducing *Giardia lamblia* trophozoite count in the small intestine than metronidazole. (Reduction of trophozoite number in *Artemisia annua*-treated group and metronidazole treated group was statistically significant ($P<0.001$)

Biochemical analysis:

Nowadays, the role of nitric oxide (NO) in the immune response to *giardia* infection has been well established. Therefore, we sought to investigate the serum levels of NO end-products (NOx) in animals infected with *Giardia lamblia* and treated with either metronidazole or *Artemisia annua*. In infected untreated animals, the serum levels of NOx were comparable to uninfected animals. In contrast, the treatment of infected hamsters with metronidazole had significantly elevated serum NOx levels compared to infected untreated animals ($p<0.001$) and uninfected control group ($p<0.001$). Similarly, infected animals treated with *Artemisia annua* extracts had their serum NOx levels significantly increased compared to infected untreated animals ($p<0.001$). However, we did not find a significant difference between the effect of metronidazole and *Artemisia Annua* extracts on serum NOx levels (Table 2 and Fig. 2a).

We next examined the serum interleukin-6 (IL-6) levels. Previously, Zhou et al. [19] had found increased IL-6 levels during the course of giardiasis in mice. Therefore, we sought to compare the effects of metronidazole and *Artemisia annua* on giardiasis-induced increase in IL-6 serum levels. Serum samples from animals infected with *Giardia lamblia* showed a significant increase in IL-6 levels compared to uninfected animals ($P < 0.05$). In contrast, treatment of giardia infected animals with metronidazole had significantly decreased serum IL-6 levels. Similarly, treatment of infected animals with *Artemisia annua* had significantly reduced serum IL-6 levels compared to untreated infected hamsters ($P < 0.05$). By

comparing the serum IL-6 levels after treatment with metronidazole or *Artemisia annua*, we observed that metronidazole significantly decreased the IL-6 serum levels compared to *Artemisia annua* ($P < 0.05$) (Table 2 and Fig. 2b).

A recent study by Pacheco and colleagues [59] has demonstrated elevated serum gamma interferon (IFN-γ) in children infected with giardiasis. Therefore, we sought to compare the effect of metronidazole and *Artemisia annua* on giardiasis-induced elevated serum IFN-γ levels. As expected, animals infected with *Giardia* lamblia showed significant increase in the serum level of IFN-γ compared to the uninfected animals ($P<0.05$). On the other hand, the serum IFN-γ levels were significantly lower in hamsters treated with metronidazole than infected untreated animals ($P< 0.05$). In animals treated with *Artemisia annua*, the serum IFN-γ had significantly reduced compared to the infected untreated animals ($P < 0.05$). These levels were higher than the serum IFN-γ levels in animals infected and treated with metronidazole (Table 2, Fig. 2c).

We also investigated the serum tumor necrosis factor (TNF)-α levels in infected animals treated with metronidazole or *Artemisia annua* extracts. As shown in table 2 and fig. 2d, serum levels of TNF-α in infected untreated animals had significantly elevated compared to the uninfected animals ($P< 0.05$). In contrast, treating infected animals with metronidazole or *Artemisia annua* extracts had significantly reduced serum levels of TNF-α compared to the infected untreated hamsters by 4 and 3 folds, respectively.

Histopathological analysis:

To further explore the effects of metronidazole and *Artemisia annua* on giardiasis-induced small intestinal lesions, we stained sections taken from the proximal parts of the small intestine with hematoxylin and eosin stains. Small intestinal sections taken from uninfected animals showed normal intestinal villi and crypts (Fig. 3a, arrowheads, and arrows). In contrast, marked shortening and destruction of intestinal villi together with retraction of their connective tissue cores were observed in small intestinal sections taken from animals infected with *Giardia lamblia* cysts (Fig. 3b, arrowheads, and stars). On the other hand, treating infected animals with metronidazole or *Artemisia annua* restored the structure of the villi and their connective tissue cores (Fig. 3c and d, arrowheads, and stars). We measured the villi length in pictures taken with 10x objective lenses using ImageJ software. As demonstrated in fig. 4, significant reduction in the villi length was observed in sections taken from infected untreated animals compared to the uninfected animals ($P<0.001$). In contrast, treating infected animals with metronidazole or *Artemisia annua* had restored the normal villi length ($P<0.001$). We did not find a significant difference between the effects of metronidazole and *Artemisia annua* on the villi length.

At the higher magnification figure, small intestinal sections taken from uninfected hamsters exhibited normal histological structure of the villi. They are covered with simple columnar epithelial cells (Fig. 5a, arrowheads) and goblet cells (Fig. 5a, asterisks). Few intraepithelial lymphocytes were observed in section taken from these animals (Fig. 5a, arrows). The core of the villi is formed of connective tissue (Fig. 5a, stars). On the other hand, infecting animals with *Giardia lamblia* cysts lead to desquamation of

epithelial cells, disruption of the epithelium covering the villi (Fig. 5b, double-headed arrows), increased intraepithelial lymphocytes (IEL) (Fig. 5b, arrows) and disintegration of the connective tissue core of the villi with few scattered connective tissue cells in this core (Fig. 5b, stars). We also observed the *Giardia lamblia* trophozoites in the intervillous spaces (Fig. 5b, arrowheads). However, tissue sections taken from infected animals treated with metronidazole showed normal covering epithelium of the villi except of few areas of epithelial disruptions (Fig. 5c, double headed arrow), regeneration of the connective tissue core of the villi (Fig. 5c, stars) and decreased intraepithelial lymphocytes infiltration (Fig. 5c, arrows). Additionally, few *Giardia lamblia* trophozoites were observed in the intervillous spaces (Fig. 5c, arrowheads). More specifically, small intestinal sections taken from infected animals treated with *Artemisia annua* extracts showed preserved architecture of the epithelial covering the villi, few desquamated cells (Fig. 5d, double headed arrows), few IEL (Fig. 5c, arrows) and well-preserved villous connective tissue core (Fig. 5c, stars). Few Giardia lamblia trophozoites were shown in the intervillous regions (Fig.5c, arrows).

We counted the IEL per 100 epithelial cells on images of hematoxylin and eosin-stained sections taken at 200x magnification. A total of 2500 epithelial cells were counted in each group according to previously published methods [55]. As shown in fig. 6, infecting hamsters with *Giardia lamblia* cysts significantly increased IEL number/100 epithelial cells compared to uninfected animals ($P<0.001$). However, treating infected animals with metronidazole or *Artemisia annua* significantly decreased the IEL number/100 epithelial cells compared to infected untreated animals ($P<0.001$). We did not find a significant difference between the effect of metronidazole and *Artemisia annua* on the number of IEL/100 epithelial cells.

To better demonstrate goblet cells, we stained our small intestinal sections with Periodic acid Schiff reagent (PAS) and hematoxylin. In uninfected animals, goblet cells are distributed among the epithelial cells in the epithelium covering the villi (Fig. 7a). Few goblet cells were observed in sections taken from infected untreated animals (Fig. 7b). However, treating infected gerbils with metronidazole or *Artemisia annua* reversed *Gardia lamblia*-induced reduction of goblet cells (Fig. 7c and d).

To confirm our observations, we evaluated the number of goblet cells/100 epithelial cells in images of small intestinal sections stained with PAS and hematoxylin taken at 200x magnification. A total of 2500 epithelial cells per group were counted according to previously published methods [60]. As demonstrated in fig. 8, infection of hamsters with *Giardia lamblia* cysts significantly reduced goblet cell number compared to the uninfected animals ($P<0.001$). On the other hand, treating infected animals with metronidazole or *Artemisia annua* had significantly increased the goblet cell number compared to the infected untreated animals ($P<0.001$). No significant difference was found between the effect of metronidazole and *Artemisia annua* on goblet cell number.

Earlier, Pavanelli et al. [18] have demonstrated that giardiasis reduced the muscularis externa thickness. We sought to investigate whether the treatment of infected animals with either metronidazole or *Artemisia annua* would reverse giardiasis-induced muscularis externa changes. In sections taken from the small intestine of uninfected hamsters, the muscularis externa is composed of smooth muscle fibers

arranged in two layers, inner circular and outer longitudinal layers. These cells have acidophilic cytoplasm and elongated vesicular centrally located nuclei (Fig. 9a). As expected, small intestinal sections taken from infected untreated hamsters showed extensive vacuolation of muscle cells of the muscularis externa (Fig. 9b, arrows). Additionally, the thickness of the muscularis externa of these animals appeared reduced. In contrast, small intestinal section taken from infected animals treated with metronidazole or *Artemisia annua* showed decreased cytoplasmic vacuolation of smooth muscle cells (Fig. 9c and d, arrows) and the muscularis externa layers appeared thicker than those of infected untreated animals (Fig. 9c and d).

To confirm our results, we measured the thickness of the muscularis externa using ImageJ software in 15 pictures of random fields taken at 400x magnification. As shown in fig. 10, infection of hamsters with Giardia lamblia significantly reduced muscularis externa thickness compared to the uninfected animals ($P<0.001$). On the other hand, treating infected animals with metronidazole or *Artemisia annua* extracts significantly increased the muscularis externa thickness compared to the infected untreated animals ($P<0.001$). No significant difference was observed between the effects of the two treatments.

Immunohistochemical analysis:

A large body of evidence has associated inducible nitric oxide synthase (iNOS) expression and *Giardia lamblia* infection [28, 61]**)**. To investigate whether treating infected hamsters with metronidazole or *Artemisia annua* would modulate the expression of iNOS, we employed the immunohistochemical technique to examine iNOS expression patterns in small intestinal tissues. In uninfected animals, we showed iNOS immunoreactivity in connective tissue cells in the core of the villi (Fig. 11a, arrows) and rarely in the enterocytes. Infection of hamsters with Giardia lamblia trophozoites caused intense iNOS signals in enterocytes covering the villi (Fig. 11b, arrowheads). In animals infected with *giardia* trophozoites and treated with metronidazole, moderate iNOS immunoreactivity was observed in villi-core connective tissue cells (Fig. 11c, arrows) and enterocytes (Fig. 11c, arrowheads). In contrast, tissues from the small intestine of animals infected with giardia trophozoites and treated with *Artemisia annua* extracts showed few cells of the villi core expressed iNOS (Fig. 11d, arrows) and barely seen signals in the enterocytes (Fig. 11d, arrowheads).

Previously, it has been demonstrated that *Giardia lamblia* trophozoites exhibited an apoptotic effect on cultured enterocytes [17]. Therefore, we sought to test whether treating infected hamsters with *Artemisia annua* extracts would attenuate giardia-induced apoptosis. We immunostained our small intestinal sections with anti-caspase-3 antibodies. In uninfected control animals, weak caspase-3 signals were observed in the enterocytes, lamina propria cells (Fig. 12a, arrows), crypt cells and muscularis externa layers (Fig. 12b, arrows). In contrast, strong caspase-3 signals were expressed by small intestinal epithelial cells and lamina propria cells (Fig. 12c, arrows) of infected untreated animals. We also observed strong caspase-3 signals in cells lining the crypts as well as smooth muscle cells of muscularis externa layers (Fig. 12d, arrows). In animals infected with *Giardia lamblia* cysts and treated with metronidazole, fewer epithelial cells in the villi and crypts as well as muscularis externa layers expressed

caspase-3 signals compared to infected untreated hamsters (Fig. 12e and f, arrows). On the other hand, the caspase-3 expression in tissues of animals infected with giardia cysts and treated with *Artemisia annua* appeared lower than those of infected untreated animals or animals infected and treated with metronidazole (Fig. 12g and h, arrows).

Discussion

Giardiasis is a major worldwide health problem. It is caused by *Giardia lamblia* parasite. Researcher have reported that this parasite developed resistance against commonly used anti-giardia drugs [32, 33]. On the other hand, many research groups have identified therapeutic potentials for many plants against parasitic diseases including *Artemisia annua* [47, 62, 63]. In the current study, we used a hamster model of giardiasis to assess the efficacy of ethanolic extracts of *Artemisia annua* as a treatment for *Giardialamblia* infections. We showed for the first time that *Artemisia annua* ethanolic extracts significantly decreased *G. lamblia* trophozoite counts. Additionally, we showed that *Artemisia annua* restored *G. lamblia*-induced changes of serum nitric oxide end-products, interlukin-6 (IL-6), interferon-γ (INF-γ) and tumor necrosis factor-α (TNF-α). Furthermore, *Artemisia annua* extracts reversed *G. lamblia*-induced changes in villus heights, intraepithelial lymphocytes, goblet cell numbers and muscularis externa thickness. Our results suggest an anti-giardia effect for *Artemisia annua* ethanolic extracts.

In the present study *Giardialamblia*-infected hamsters treated with *Artemisia annua* extracts showed a marked reduction in the number of trophozoites in intestinal tissues in comparison with the infected untreated animals and metronidazole treated group. This finding is in line with Alin and Bjorkman [64] observation who demonstrated that artemisinin, an *Artemisia annua* derivative, inhibited the growth of malaria parasite in a concentration dependent manner. Additionally, *in vitro* experiments of [45] demonstrated that *Artemisia annua* extracts destroyed giardia trophozoites in concentration and time dependent manners. Therefore, reduction of *Giardia lamblia* trophozoite counts after treatment with *Artemisia annua* extracts could be through inhibition of its growth and/or direct killing of trophozoites by Artemisia annua.

A large body of evidences suggested a role for nitric oxide (NO) in elimination of *G. lamblia* trophozoites [25, 65]. To survive in the intestine, *G. Lamblia* trophozoite developed strategies to limit host production of NO. They compete with host for the amino acid arginine, a substrate for NO production, as they used it as a fuel during various stages of growth [26]. Therefore, they decrease the availability of arginine for NO production. Additionally, *in vitro* experiments of [66] have demonstrated that giardia trophozoites secret arginase upon contact with intestinal epithelial cells. Furthermore, Maloney et al. [27] reported increased production of arginases by small intestinal macrophages during giardiasis. In line with these data, we have shown reduction in serum NO levels in animals infected with *G. lamblia* cysts. Although we, in the current work, and others [28, 61] reported increased expression of inducible nitric oxide synthase (iNOS) in the intestine, this failed to increase NO levels in infected animals due to arginine deficiency.

Additionally, we have shown that treating infected animals with *Artemisia annua* extracts increased serum NO levels compared to infected untreated animals. This could be attributable to the inhibitory effect of *Artemisia annua* on *G. lamblia* trophozoites growth, thus making arginine available for NO synthesis. Another explanation for *Artemisia annua* induced increased NO levels could be through inhibition of arginase release by macrophages. This assumption is partially supported by the work of Yang and colleagues [67] who showed that *Artemisia annua* derivatives inhibited activation of macrophages in vitro. The increased NO levels due to treatment with *Artemisia annua* extracts was associated with decreased expression of iNOS. A question arises here; how did *Artemisia annua* extracts increase NO production while decreasing iNOS expression? The answer for this question is suggested by the work of Li and colleagues who demonstrated that neuronal nitric oxide synthase (nNOS) is more important in getting rid of *Giardia* parasite than iNOS [68]. Therefore, *Artemisia annua* could increase serum NO levels through increased production of nNOS rather than iNOS. This role of *Artemisia annua* needs further investigation.

Our Results also showed significant increase in inflammatory cytokines levels namely; IL-6, TNF-α and INF-γ in animals infected with *G. lamblia* cysts. Our observation is in agreement with previous reports [69, 70].These cytokines are produced by the immune system to control *G. lamblia* infections. This argument was supported by the work of Li et al. [71] who demonstrated that increased cytokine production in mice deficient in toll-like receptor (TLR) 2 reduced the parasite burden and alleviated giardiasis. Additionally, Bienz at al. [20] showed that IL-6 deficient mice failed to control *G. lmablia* infection. Moreover, mice with deficient TNF-α have an increased parasite load and prolonged *Giardia lamblia* infection [70]. However, increased production of inflammatory cytokines during *Giardia lamblia* infection was associated with structural changes in the small intestine [72]. In animals infected and treated with *Artemisia annua*, serum IL-6 levels were lower than those of infected untreated animals. However, these levels were higher than those of metronidazole treated animals. These data give *Artemisia annua* extracts an advantage as IL-6 blocks epithelial cells apoptosis and helps in epithelial repair [73]. On the contrary, the level of TNF-α is lower in *Artemisia annua* treated group than that of metronidazole treated animals. These data also favor *Artemisia annua* over metronidazole as higher levels of TNF-α were associated with intestinal damage [74].

Our histological analysis reveals that infection of hamsters with giardia trophozoites lead to shortening of the intestinal villi, shedding and desquamation of enterocytes. This damaging effect of giardia trophozoites could be due to the secreted parasite proteins with proteolytic activities. These proteins lead to disruption of cell-cell junctions and enterocyte damage in vitro [75]. Additionally, Scott and colleagues [76] have demonstrated that intraepithelial $CD8^+$ T cells destroyed the apical membrane of enterocytes with loss of brush border and reduced disaccharidases activities. Other experiments have reported treating small intestinal epithelial cells with INF-γ disrupts mucosal barrier function through loss of zonula occludens (ZO)-1 and increased epithelial permeability [77]. Moreover, Troeger et al. [78] as well as Fisher et al. [79] have associated enterocyte damage with giardia-induced apoptosis. Furthermore, several authors have suggested that TNF-α signaling through TNF-α receptor 1 (TNFR1) induced enterocytes

apoptosis in a caspase-dependent manner [80-82]. In line with this hypothesis, our immunohistochemical data showed that infecting animals with *Giardia lamblia* cysts increased the expression of caspase-3 which could account for tissue damage seen in our model. Together, small intestinal damage observed in our model could be due to the parasite secretory products and/or because of elevated cytokines levels.

However, treating giardia infected gerbils with *Artemisia annua* extracts markedly decreased desquamated enterocytes with nearly normal villi covering. This effect could be attributable to the direct apoptotic effect of *Artemisia annua* on the *Giardia lamblia* parasite, an effect that protects enterocytes from the proteolytic enzymes secreted by the parasite. This assumption is partially supported by the work of Jiao and colleagues [44] who demonstrated that *Artemisia annua* leaves induced apoptosis of Eimeria tenella, an intracellular parasite that infects chicken enterocytes. In the same work, the authors also showed that *Artemisia annua* decreased the expression of the inflammatory markers; nuclear factor-$_{kappa}$B (NF-$_{k}$B) and IL-17. Moreover, Sun et al. [83] showed that artesunate, an *Artemisia annua* derivative, induced apoptosis of lamina propria macrophages, dendritic cells and decreased mucosal expression of TNF-α in a rodent model of colitis. Numerous studies have associated NF-kB and TNF-α with various inflammatory conditions [84, 85]. Therefore, controlling the activation of NF-$_{k}$B and expression of TNF-α could account for the curative effect of *Artemisia annua*. Treating infected animals with *Artemisia annua* extracts also decreased serum INF-γ levels. This effect of *Artemisia annua* could account for alleviation of morphological changes occurred during *G. lamblia* infection. On the other hand, Jiao et al. [44] have demonstrated that *Artemisia annua* leaves induced apoptosis of Eimeria tenella-infected enterocytes. Lang and colleagues [86] have also reported that *Artemisia annua* inhibited the viability of resistant cancer cells while unaltered cells escaped this inhibition. In the same context, our immunohistochemistry data revealed that treating infected animals with *Artemisia annua* extracts attenuated enterocytes caspase-3 expression. In line with this finding, Yuan et al. [87] demonstrated that *Artemisia* derivatives protected mice liver against injurious effect of acetaminophen through decrease caspase-3, 8 expression and serum TNF-α levels. Therefore, *Artemisia annua* derivatives could inhibit growth or induce apoptosis of altered cells as suggested by Deng et al. [88] and Jiao et al. [44] reports, while unaltered cells could be protected by *Artemisia annua* derivatives as shown by us and others [87]. Altogether, *Artemisia annua* attenuated giardia-induced enterocytes damage through abolishing the effect of *G. lamblia*-secreted proteins, anti-inflammatory and possible anti-apoptotic effect. These roles of *Artemisia annua* need further exploration.

In the current study, intestinal sections of infected untreated animals showed increased intraepithelial lymphocytes (IEL). Our observation is line with previous report [76]. Increased IEL is part of the immune mechanism to clear *G. lamblia* infection [89]. This rise of IEL number could be a response to antigens secreted by the parasite or chemotactic stimuli released in response to the parasite [90]. Unlike immunocompetent animals, nude athymic mice failed to eliminated *Giardia* infection [91] suggesting a role for T cells in elimination of the parasite. Both $CD4^{+}$ and $CD8^{+}$ cells contribute to the increased IEL during giardiasis [76]. However, increased IEL have been accused for villus damage and epithelial injury during Giardiasis. In this regard, Scott and colleagues [76] have demonstrated that transplantation of

activated $CD8^+$ T cell from *Giardia* infected animals to normal mice was associated with epithelial tissue damage. Additionally, Ebert [90] demonstrated that *G. lamblia* increased proliferation of $CD4^+$ T cells and increased secretion of IFN-γ from both intestinal and blood lymphocytes. On the contrary, animals treated with *Artemisia annua* showed lower number of IEL compared to infected untreated animals. This observation can be attributable to the reduction of the parasite load in animals treated with *Artemisia annua*.

Goblet cells are essential for protection of the intestinal epithelium from luminal pathogens [92]. Mucins produced by goblet cells form a protective viscous barrier against invading pathogens [93]. In giardiasis, trophozoites disrupt the mucus barrier by secretion of proteases to colonize the intestine [94]. Interestingly, Shukla and Sidhu [95] have demonstrated that infection of mice with *Giardia intestinalis* cysts reduced goblet cell number, increased excretion of cysts in stool and trophozoite count in their intestines. In accordance with this observation, we showed that infection of gerbils with *Giardia lamblia* cysts significantly reduced goblet cell number compared to uninfected animals. This reduction of goblet cells could be due to the depletion of their mucin by trophozoites [94], and hence could not be detected by Periodic Acid Schiff (PAS) reagent we used in assessment of goblet cell number.

In the present study, we showed that treating infected hamsters with *Artemisia annua* lead to restoration of goblet cell number. This could be attributable to the direct effect of *Artemisia annua* on the giardia trophozoites as we mentioned earlier. This effect protects the mucous barrier from proteases produced by the trophozoites. Therefore, we can assume that increase goblet cell number and hence mucus production by *Artemisia annua* stopped colonization of giardia trophozoite in the intestine. This assumption is supported by the in vitro experiments of Roskens and Erlandsen [96] who demonstrated that mucin inhibited the attachment of trophozoite to the substratum.

A possible limitation of our study should be noted here. We used high dose of *Artemisia annua* ethanolic extracts. Similar dosage was used by a number of studies [49, 97]. The advantage of using high dose of *Artemisia annua* ethanolic extracts in the current paper is that the extract supply all the molecules present in the plant, particularly the polysaccharides, coumarins, saponins, phytosterols, essential oils, polyphenols and flavonoids [98]. Additionally, the use of the whole plant was found to be more effective in the treatment of a rodent malaria model, as compared to the use of a comparable dose of pure artemisinin [99].

In conclusion, infection of gerbils with *Giardia lamblia* cysts lowered serum NO, while increased IL-6, IFN-γ and TNF-α. Additionally, *G. lamblia* infection reduced villus height, goblet cells number, muscularis externa thickness while increased IEL. Interestingly, all these abnormalities were alleviated upon treating infected animals with *Artemisia annua* extracts. Treatment of infected animals with *Artemisia annua* extracts also reduced small intestinal trophozoite count. These effects of *Artemisia annua* extracts were comparable to those of metronidazole. Therefore, we assume that *Artemisia annua* extracts can be used as adjuvant therapy during treatment of giardiasis. Further animal and human studies are needed to prove this assumption.

List Of Abbreviations

A. annua: Artemisia annua

HPF: high power field

IEL: intraepithelial Lymphocytes

IL-6: Interlukin-6

INF-γ: Interferon-γ

iNOS: inducible nitric oxide synthase

NF-$_{k}$B: Nuclear factor-$_{kappa}$B

nNOS: neuronal nitric oxide synthase

NO: nitric oxide

PAS: Periodic acid Schiff reagent

TNFR1: TNF-α receptor 1

TNF-α: Tumor necrosis factor-α

Declarations

Ethics approval:

Experiments on animals were performed in accordance with the ethical animal guidelines and regulations set by the Animal Care Committee of the Faculty of Medicine, South Valley University, and guidelines of the National Institute of Health for the Care and Use of Laboratory Animals. Ethical approval was granted by the Research and Ethics Committee of the Faculty of Medicine, South Valley University.

Conflict of interest:

The authors declare no conflict of interest.

Consent for publication:

Not applicable

Availability of data and materials:

The datasets during and/or analyzed during the current study available from the corresponding author on reasonable request.

Competing interests:

The authors declare that they have no competing interests.

Funding:

This work was not supported by any funding agency.

Author contributions:

Abd-Elhamid, T.H. Conceptualization, Methodology, software, Writing original drafts and visualization, Formal analysis. **Abdel-Rahman, I.A.M.** Methodology, Writing Reviewing and Editing, Visualization. **Mahmoud, A.R.** Investigation, Data collection, Writing, Reviewing, Editing. **Fouad, S.S.** Methodology, writing, Reviewing and Editing, Visualization. **Abdella, O.H.** Methodology, Writing Reviewing and Editing, Visualization. **El-Kady, A.M.** Conceptualization, Methodology, Investigation, Software, Formal analysis, Writing original drafts. All authors approved the final manuscript.

References

1. Krauss H, Weber A, Appel M, Enders B, Isenberg HD, Schiefer HG, Slenczka W, von Graevenitz A, Zahner H: **Parasitic Zoonoses**. In: *Zoonoses: Infectious Diseases Transmissible from Animals to Humans*, Third Edition edn. Washington, D.C.: American Society of Microbiology; 2003: 280.
2. Ankarklev J, Jerlstrom-Hultqvist J, Ringqvist E, Troell K, Svard SG: **Behind the smile: cell biology and disease mechanisms of Giardia species**. *Nat Rev Microbiol* 2010, **8**(6):413-422.
3. Thompson RC: **Giardiasis as a re-emerging infectious disease and its zoonotic potential**. *International journal for parasitology* 2000, **30**(12-13):1259-1267.
4. Abdel-Hafeez EH, Ahmad AK, Ali BA, Moslam FA: **Opportunistic parasites among immunosuppressed children in Minia District, Egypt**. *Korean J Parasitol* 2012, **50**(1):57-62.
5. Baiomy AM, Mohamed KA, Ghannam MA, Shahat SA, Al-Saadawy AS: **Opportunistic parasitic infections among immunocompromised Egyptian patients**. *Journal of the Egyptian Society of Parasitology* 2010, **40**(3):797-808.
6. Foronda P, Bargues MD, Abreu-Acosta N, Periago MV, Valero MA, Valladares B, Mas-Coma S: **Identification of genotypes of Giardia intestinalis of human isolates in Egypt**. *Parasitology research* 2008, **103**(5):1177-1181.
7. El-Naggar SM, El-Bahy MM, Abd Elaziz J, El-Dardiry MA: **Detection of protozoal parasites in the stools of diarrhoeic patients using different techniques**. *Journal of the Egyptian Society of Parasitology* 2006, **36**(1):7-22.

8. Feng Y, Xiao L: **Zoonotic potential and molecular epidemiology of Giardia species and giardiasis**. *Clinical microbiology reviews* 2011, **24**(1):110-140.
9. Balcioglu IC, Limoncu E, Ertan P, Yereli K, Ozbilgin A, Onag A: **Incidence of giardiasis among siblings in Turkey**. *Pediatr Int* 2003, **45**(3):311-313.
10. Veenemans J, Mank T, Ottenhof M, Baidjoe A, Mbugi EV, Demir AY, Wielders JP, Savelkoul HF, Verhoef H: **Protection against diarrhea associated with Giardia intestinalis Is lost with multi-nutrient supplementation: a study in Tanzanian children**. *PLoS Negl Trop Dis* 2011, **5**(6):e1158.
11. Eppig C, Fincher CL, Thornhill R: **Parasite prevalence and the worldwide distribution of cognitive ability**. *Proc Biol Sci* 2010, **277**(1701):3801-3808.
12. Goncalves AC, Gabbay YB, Mascarenhas JD, Yassaka MB, Moran LC, Fraga VD, Castro E, Franco C, Machado RL, Rossit AR: **Calicivirus and Giardia lamblia are associated with diarrhea in human immunodeficiency virus-seropositive patients from southeast Brazil**. *The American journal of tropical medicine and hygiene* 2009, **81**(3):463-466.
13. Reynoso-Robles R, Ponce-Macotela M, Rosas-Lopez LE, Ramos-Morales A, Martinez-Gordillo MN, Gonzalez-Maciel A: **The invasive potential of Giardia intestinalis in an in vivo model**. *Sci Rep* 2015, **5**:15168.
14. Panarelli NC, Gobara N, Hoda RS, Chaump M, Jessurun J, Yantiss RK: **Cytology Preparations of Formalin Fixative Aid Detection of Giardia in Duodenal Biopsy Samples**. *Am J Surg Pathol* 2017, **41**(4):570-574.
15. Ventura LL, Oliveira DR, Viana JC, Santos JF, Caliari MV, Gomes MA: **Impact of protein malnutrition on histological parameters of experimentally infected animals with Giardia lamblia**. *Experimental parasitology* 2013, **133**(4):391-395.
16. Panaro MA, Cianciulli A, Mitolo V, Mitolo CI, Acquafredda A, Brandonisio O, Cavallo P: **Caspase-dependent apoptosis of the HCT-8 epithelial cell line induced by the parasite Giardia intestinalis**. *FEMS Immunol Med Microbiol* 2007, **51**(2):302-309.
17. Chin AC, Teoh DA, Scott KG, Meddings JB, Macnaughton WK, Buret AG: **Strain-dependent induction of enterocyte apoptosis by Giardia lamblia disrupts epithelial barrier function in a caspase-3-dependent manner**. *Infection and immunity* 2002, **70**(7):3673-3680.
18. Pavanelli MF, Colli CM, Bezagio RC, Gois MB, de Alcantara Nogueira de Melo G, de Almeida Araujo EJ, de Mello Goncales Sant'Ana D: **Assemblages A and B of Giardiaduodenalis reduce enteric glial cells in the small intestine in mice**. *Parasitology research* 2018, **117**(7):2025-2033.
19. Zhou P, Li E, Zhu N, Robertson J, Nash T, Singer SM: **Role of interleukin-6 in the control of acute and chronic Giardia lamblia infections in mice**. *Infection and immunity* 2003, **71**(3):1566-1568.
20. Bienz M, Dai WJ, Welle M, Gottstein B, Muller N: **Interleukin-6-deficient mice are highly susceptible to Giardia lamblia infection but exhibit normal intestinal immunoglobulin A responses against the parasite**. *Infection and immunity* 2003, **71**(3):1569-1573.
21. Lee HY, Kim J, Noh HJ, Kim HP, Park SJ: **Giardia lamblia binding immunoglobulin protein triggers maturation of dendritic cells via activation of TLR4-MyD88-p38 and ERK1/2 MAPKs**. *Parasite*

immunology 2014, **36**(12):627-646.

22. Kamda JD, Nash TE, Singer SM: **Giardia duodenalis: dendritic cell defects in IL-6 deficient mice contribute to susceptibility to intestinal infection**. *Experimental parasitology* 2012, **130**(3):288-291.
23. Popovic PJ, Zeh HJ, 3rd, Ochoa JB: **Arginine and immunity**. *J Nutr* 2007, **137**(6 Suppl 2):1681S-1686S.
24. Das P, Lahiri A, Lahiri A, Chakravortty D: **Modulation of the arginase pathway in the context of microbial pathogenesis: a metabolic enzyme moonlighting as an immune modulator**. *PLoS Pathog* 2010, **6**(6):e1000899.
25. Eckmann L, Laurent F, Langford TD, Hetsko ML, Smith JR, Kagnoff MF, Gillin FD: **Nitric oxide production by human intestinal epithelial cells and competition for arginine as potential determinants of host defense against the lumen-dwelling pathogen Giardia lamblia**. *Journal of immunology (Baltimore, Md : 1950)* 2000, **164**(3):1478-1487.
26. Brown DM, Upcroft JA, Edwards MR, Upcroft P: **Anaerobic bacterial metabolism in the ancient eukaryote Giardia duodenalis**. *International journal for parasitology* 1998, **28**(1):149-164.
27. Maloney J, Keselman A, Li E, Singer SM: **Macrophages expressing arginase 1 and nitric oxide synthase 2 accumulate in the small intestine during Giardia lamblia infection**. *Microbes Infect* 2015, **17**(6):462-467.
28. Stadelmann B, Hanevik K, Andersson MK, Bruserud O, Svard SG: **The role of arginine and arginine-metabolizing enzymes during Giardia - host cell interactions in vitro**. *BMC Microbiol* 2013, **13**:256.
29. Dupouy-Camet J: **New drugs for the treatment ofhuman parasitic protozoa**. *Parassitologia* 2004, **46**(1-2):81-84.
30. Huang DB, White AC: **An updated review on Cryptosporidium and Giardia**. *Gastroenterol Clin North Am* 2006, **35**(2):291-314, viii.
31. Lalle M: **Giardiasis in the post genomic era: treatment, drugresistance and novel therapeutic perspectives**. *Infect Disord Drug Targets* 2010, **10**(4):283-294.
32. Long KZ, Rosado JL, Montoya Y, de Lourdes Solano M, Hertzmark E, DuPont HL, Santos JI: **Effect of vitamin A and zinc supplementation on gastrointestinal parasitic infections among Mexican children**. *Pediatrics* 2007, **120**(4):e846-855.
33. Upcroft JA, Dunn LA, Wright JM, Benakli K, Upcroft P, Vanelle P: **5-Nitroimidazole drugs effective against metronidazole-resistant Trichomonas vaginalis and Giardia duodenalis**. *Antimicrobial agents and chemotherapy* 2006, **50**(1):344-347.
34. Bora KS, Sharma A: **The genus Artemisia: a comprehensive review**. *Pharm Biol* 2011, **49**(1):101-109.
35. Daddy NB, Kalisya LM, Bagire PG, Watt RL, Towler MJ, Weathers PJ: **Artemisia annua dried leaf tablets treated malaria resistant to ACT and i.v. artesunate: Case reports**. *Phytomedicine : international journal of phytotherapy and phytopharmacology* 2017, **32**:37-40.
36. Valderrabano J, Calvete C, Uriarte J: **Effect of feeding bioactive forages on infection and subsequent development of Haemonchus contortus in lamb faeces**. *Veterinary parasitology* 2010, **172**(1-2):89-

94.

37. Ferreira JF, Luthria DL, Sasaki T, Heyerick A: **Flavonoids from Artemisia annua L. as antioxidants and their potential synergism withartemisinin against malaria and cancer**. *Molecules* 2010, **15**(5):3135-3170.
38. Chukwurah PN, Brisibe EA, Osuagwu AN, Okoko T: **Protective capacity of Artemisia annua as a potent antioxidant remedy against free radical damage**. *Asian Pac J Trop Biomed* 2014, **4**(Suppl 1):S92-98.
39. Mishina YV, Krishna S, Haynes RK, Meade JC: **Artemisinins inhibit Trypanosoma cruzi and Trypanosoma brucei rhodesiense in vitro growth**. *Antimicrobial agents and chemotherapy* 2007, **51**(5):1852-1854.
40. Ferreira JF, Peaden P, Keiser J: **In vitro trematocidal effects of crude alcoholic extracts of Artemisia annua, A. absinthium, Asimina triloba, and Fumaria officinalis: trematocidal plant alcoholic extracts**. *Parasitology research* 2011, **109**(6):1585-1592.
41. de Oliveira TC, Silva DA, Rostkowska C, Bela SR, Ferro EA, Magalhaes PM, Mineo JR: **Toxoplasma gondii: effects of Artemisia annua L. on susceptibility to infection in experimental models in vitro and in vivo**. *Experimental parasitology* 2009, **122**(3):233-241.
42. Mesa LE, Vasquez D, Lutgen P, Velez ID, Restrepo AM, Ortiz I, Robledo SM: **In vitro and in vivo antileishmanial activity of Artemisia annua L. leaf powder and its potential usefulness in the treatment of uncomplicated cutaneous leishmaniasis in humans**. *Rev Soc Bras Med Trop* 2017, **5**0(1):52-60.
43. Sen R, Bandyopadhyay S, Dutta A, Mandal G, Ganguly S, Saha P, Chatterjee M: **Artemisinin triggers induction of cell-cycle arrest and apoptosis in Leishmania donovani promastigotes**. *J Med Microbiol* 2007, **56**(Pt 9):1213-1218.
44. Jiao J, Yang Y, Liu M, Li J, Cui Y, Yin S, Tao J: **Artemisinin and Artemisia annua leaves alleviate Eimeria tenella infection by facilitating apoptosis of host cells and suppressing inflammatory response**. *Veterinary parasitology* 2018, **254**:172-177.
45. Golami S, Rahimi-Esboei B, Mousavi P, Marhaba Z, Youssefi MR, Rahimi MT: **Survey on efficacy of chloroformic extract of Artemisia annua against Giardia lamblia trophozoite and cyst in vitro**. *J Parasit Dis* 2016, **40**(1):88-92.
46. Tariq KA, Chishti MZ, Ahmad F, Shawl AS: **Anthelmintic activity of extracts of Artemisia absinthium against ovine nematodes**. *Veterinary parasitology* 2009, **160**(1-2):83-88.
47. Rahimi-Esboei B, Ebrahimzadeh MA, Gholami S, Falah-Omrani V: **Anti-giardial activity of Sambucus ebulus**. *European review for medical and pharmacological sciences* 2013, **17**(15):2047-2050.
48. Laurence DR, Bacharach AL: **Evaluation of drug activities: pharmacometrics**. London; New York: Academic Press; 1964.
49. Squires JM, Ferreira JF, Lindsay DS, Zajac AM: **Effects of artemisinin andArtemisia extracts on Haemonchus contortus in gerbils (Meriones unguiculatus)**. *Veterinary parasitology* 2011, **175**(1-2):103-108.

50. Aly E, Sabry H, Fahmy Z, Zalat R: **Efficacy of combination therapy (metronidazole and/or artemether) in experimental giardiasis and its impact on nonenzymatic oxidative stress biomarkers**. *Parasitologists United Journal* 2014, **7**(1):68-74.
51. Fathy FM: **Effect of mirazid (Commiphora molmol) on experimental giardiasis**. *Journal of the Egyptian Society of Parasitology* 2011, **41**(1):155-177.
52. Rayan P, Stenzel D, McDonnell PA: **The effects of saturated fatty acids on Giardia duodenalis trophozoites in vitro**. *Parasitology research* 2005, **97**(3):191-200.
53. Nuttall KL, Gordon WH, Ash KO: **Inductively coupled plasma mass spectrometry for trace element analysis in the clinical laboratory**. *Annals of clinical and laboratory science* 1995, **25**(3):264-271.
54. Drury RAB, Wallington EA: **Carleton's Histological Technique**, 5th edn. Oxford, New York, Toronto: Oxford University Press; 1980.
55. Chott A, Gerdes D, Spooner A, Mosberger I, Kummer JA, Ebert EC, Blumberg RS, Balk SP: **Intraepithelial lymphocytes in normal human intestine do not express proteins associated with cytolytic function**. *The American journal of pathology* 1997, **151**(2):435-442.
56. Rogawski ET, Bartelt LA, Platts-Mills JA, Seidman JC, Samie A, Havt A, Babji S, Trigoso DR, Qureshi S, Shakoor S *et al*: **Determinants and Impact of Giardia Infection in the First 2 Years of Life in the MAL-ED Birth Cohort**. *Journal of the Pediatric Infectious Diseases Society* 2017, **6**(2):153-160.
57. Squire SA, Ryan U: **Cryptosporidium and Giardia in Africa: current and future challenges**. *Parasites & vectors* 2017, **10**(1):195.
58. Gardner TB, Hill DR: **Treatment of giardiasis**. *Clinical microbiology reviews* 2001, 14(1):114-128.
59. Pacheco FTF, Carvalho SS, Cardoso LS, Andrade LS, das Chagas GMT, Gomes DC, Merces CF, Rocha FC, Silva LK, Soares NM *et al*: **Immune response markers in sera of children infected with Giardia duodenalis AI and AII subassemblages**. *Immunobiology* 2019, **224**(4):595-603.
60. Mello Rde O, Silva CM, Fonte FP, Silva DL, Pereira JA, Margarido NF, Martinez CA: **Evaluation of the number of goblet cells in crypts of the colonic mucosa with and without fecal transit**. *Revista do Colegio Brasileiro de Cirurgioes* 2012, **39**(2):139-145.
61. Mokrzycka M, Kolasa A, Kosierkiewicz A, Wiszniewska B: **Inducible nitric oxide synthase in duodenum of children with Giardia lamblia infection**. *Folia histochemica et cytobiologica* 2010, **48**(2):191-196.
62. Calzada F, Yépez-Mulia L, Aguilar A: **In vitro susceptibility of Entamoeba histolytica and Giardia lamblia to plants used in Mexican traditional medicine for the treatment of gastrointestinal disorders**. *Journal of ethnopharmacology* 2006, **108**(3):367-370.
63. Kim WS, Choi WJ, Lee S, Kim WJ, Lee DC, Sohn UD, Shin HS, Kim W: **Anti-inflammatory, Antioxidant and Antimicrobial Effects of Artemisinin Extracts from Artemisia annua L**. *The Korean journal of physiology & pharmacology : official journal of the Korean Physiological Society and the Korean Society of Pharmacology* 2015, **19**(1):21-27.
64. Alin MH, Bjorkman A: **Concentration and time dependency of artemisinin efficacy against Plasmodium falciparum in vitro**. *The American journal of tropical medicine and hygiene* 1994,

50(6):771-776.

65. Fernandes PD, Assreuy J: **Role of nitric oxide and superoxide in Giardia lamblia killing**. *Brazilian journal of medical and biological research = Revista brasileira de pesquisas medicas e biologicas* 1997, **30**(1):93-99.
66. Ringqvist E, Palm JE, Skarin H, Hehl AB, Weiland M, Davids BJ, Reiner DS, Griffiths WJ, Eckmann L, Gillin FD *et al*: **Release of metabolic enzymes by Giardia in response to interaction with intestinal epithelial cells**. *Molecular and biochemical parasitology* 2008, **159**(2):85-91.
67. Yang Z, Ding J, Yang C, Gao Y, Li X, Chen X, Peng Y, Fang J, Xiao S: **Immunomodulatory and anti-inflammatory properties of artesunate in experimental colitis**. *Current medicinal chemistry* 2012, **19**(26):4541-4551.
68. Li E, Zhou P, Singer SM: **Neuronal nitric oxide synthase is necessary for elimination of Giardia lamblia infections in mice**. *Journal of immunology (Baltimore, Md : 1950)* 2006, **176**(1):516-521.
69. Matowicka-Karna J, Dymicka-Piekarska V, Kemona H: **IFN-gamma, IL-5, IL-6 and IgE in patients infected with Giardia intestinalis**. *Folia histochemica et cytobiologica* 2009, **47**(1):93-97.
70. Zhou P, Li E, Shea-Donohue T, Singer SM: **Tumour necrosis factor alpha contributes to protection against Giardia lamblia infection in mice**. *Parasite immunology* 2007, **29**(7):367-374.
71. Li X, Zhang X, Gong P, Xia F, Li L, Yang Z, Li J: **TLR2(-/-) Mice Display Decreased Severity of Giardiasis via Enhanced Proinflammatory Cytokines Production Dependent on AKT Signal Pathway**. *Front Immunol* 2017, **8**:1186.
72. Solaymani-Mohammadi S, Singer SM: **Host immunity and pathogen strain contribute to intestinal disaccharidase impairment following gut infection**. *Journal of immunology (Baltimore, Md : 1950)* 2011, **187**(7):3769-3775.
73. Kuhn KA, Manieri NA, Liu TC, Stappenbeck TS: **IL-6 stimulatesintestinal epithelial proliferation and repair after injury**. *PloS one* 2014, **9**(12):e114195.
74. Zong X, Hu W, Song D, Li Z, Du H, Lu Z, Wang Y: **Porcine lactoferrin-derived peptide LFP-20 protects intestinal barrier by maintaining tight junction complex and modulating inflammatory response**. *Biochemical pharmacology* 2016, **104**:74-82.
75. Cabrera-Licona A, Solano-Gonzalez E, Fonseca-Linan R, Bazan-Tejeda ML, Raul A-G, Bermudez-Cruz RM, Ortega-Pierres G: **Expression and secretion of the Giardia duodenalis variant surface protein 9B10A by transfected trophozoites causes damage to epithelial cell monolayers mediated by protease activity**. *Experimental parasitology* 2017, **179**:49-64.
76. Scott KG, Yu LC, Buret AG: **Role of CD8+ and CD4+ T lymphocytes in jejunal mucosal injury during murine giardiasis**. *Infection and immunity* 2004, **72**(6):3536-3542.
77. Youakim A, Ahdieh M: **Interferon-gamma decreases barrier function in T84 cells by reducing ZO-1 levels and disrupting apical actin**. *The American journal of physiology* 1999, 276(5):G1279-1288.
78. Troeger H, Epple HJ, Schneider T, Wahnschaffe U, Ullrich R, Burchard GD, Jelinek T, Zeitz M, Fromm M, Schulzke JD: **Effect of chronic Giardia lamblia infection on epithelial transport and barrier function in human duodenum**. *Gut* 2007, 56(3):328-335.

79. Fisher BS, Estrano CE, Cole JA: **Modeling long-term host cell-Giardia lamblia interactions in an in vitro co-culture system**. *PloS one* 2013, **8**(12):e81104.
80. Williams JM, Duckworth CA, Watson AJ, Frey MR, Miguel JC, Burkitt MD, Sutton R, Hughes KR, Hall LJ, Caamano JH *et al*: **A mouse model of pathological small intestinal epithelial cell apoptosis and shedding induced by systemic administration of lipopolysaccharide**. *Disease models & mechanisms* 2013, **6**(6):1388-1399.
81. Piguet PF, Vesin C, Donati Y, Barazzone C: **TNF-induced enterocyte apoptosis and detachment in mice: induction of caspases and prevention by a caspase inhibitor, ZVAD-fmk**. *Laboratory investigation; a journal of technical methods and pathology* 1999, **79**(4):495-500.
82. Parker A, Vaux L, Patterson AM, Modasia A, Muraro D, Fletcher AG, Byrne HM, Maini PK, Watson AJM, Pin C: **Elevated apoptosis impairs epithelial cell turnover and shortens villi in TNF-driven intestinal inflammation**. *Cell death & disease* 2019, **10**(2):108.
83. Sun W, Han X, Wu S, Wu J, Yang C, Li X: **Unexpected mechanism of colitis amelioration by artesunate, a natural product from Artemisia annua L**. *Inflammopharmacology* 2019.
84. Abd-Elhamid TH, Elgamal DA, Ali SS, Ali FEM, Hassanein EHM, El-Shoura EAM, Hemeida RAM: **Reno-protective effects of ursodeoxycholic acid against gentamicin-induced nephrotoxicity through modulation of NF-kappaB, eNOS and caspase-3 expressions**. *Cell and tissue research* 2018, **374**(2):367-387.
85. Ali FEM, Hassanein EHM, Bakr AG, El-Shoura EAM, El-Gamal DA, Mahmoud AR, Abd-Elhamid TH: **Ursodeoxycholic acid abrogates gentamicin-induced hepatotoxicity in rats: Role of NF-kappaB-p65/TNF-alpha, Bax/Bcl-xl/Caspase-3, and eNOS/iNOS pathways**. *Life sciences* 2020, **254**:117760.
86. Lang SJ, Schmiech M, Hafner S, Paetz C, Steinborn C, Huber R, Gaafary ME, Werner K, Schmidt CQ, Syrovets T *et al*: **Antitumor activity of an Artemisia annua herbal preparation and identification of active ingredients**. *Phytomedicine : international journal of phytotherapy and phytopharmacology* 2019, **62**:152962.
87. Yuan HD, Jin GZ, Piao GC: **Protective effects of the active part of Artemisia sacrorum Ledeb. against acetaminophen-induced liver injury in mice**. *Biological & pharmaceutical bulletin* 2009, **32**(10):1683-1688.
88. Deng XR, Liu ZX, Liu F, Pan L, Yu HP, Jiang JP, Zhang JJ, Liu L, Yu J: **Holotransferrin enhances selective anticancer activity of artemisinin against human hepatocellular carcinoma cells**. *Journal of Huazhong University of Science and Technology Medical sciences = Hua zhong ke ji da xue xue bao Yi xue Ying De wen ban = Huazhong keji daxue xuebao Yixue Yingdewen ban* 2013, **33**(6):862-865.
89. Cevallos AM, Farthing MJG: **Parasitic infections of the gastrointestinal tract**. *Current Opinion in Gastroenterology* 1992, **8**(1).
90. Ebert EC: **Giardia induces proliferation and interferon gamma production by intestinal lymphocytes**. *Gut* 1999, **44**(3):342-346.
91. Heyworth MF, Owen RL, Jones AL: **Comparison of leukocytes obtained from the intestinal lumen of Giardia-infected immunocompetent mice and nude mice**. *Gastroenterology* 1985, **89**(6):1360-1365.

92. Deplancke B, Gaskins HR: **Microbial modulation of innate defense: goblet cells and the intestinal mucus layer**. *The American journal of clinical nutrition* 2001, **73**(6):1131S-1141S.
93. Birchenough GM, Johansson ME, Gustafsson JK, Bergstrom JH, Hansson GC: **New developments in goblet cell mucus secretion and function**. *Mucosal immunology* 2015, **8**(4):712-719.
94. Amat CB, Motta JP, Fekete E, Moreau F, Chadee K, Buret AG: **Cysteine Protease-Dependent Mucous Disruptions and Differential Mucin Gene Expression in Giardia duodenalis Infection**. *The American journal of pathology* 2017, **187**(11):2486-2498.
95. Shukla G, Sidhu RK: **Lactobacillus casei as a probiotic in malnourished Giardia lamblia-infected mice: a biochemical and histopathological study**. *Can J Microbiol* 2011, **57**(2):127-135.
96. Roskens H, Erlandsen SL: **Inhibition of in vitro attachment of Giardia trophozoites by mucin**. *The Journal of parasitology* 2002, **88**(5):869-873.
97. Deng Y, Liu Z, Geng Y: **Anti-allergic effect of Artemisia extract in rats**. *Experimental and therapeutic medicine* 2016, **12**(2):1130-1134.
98. Bilia AR, Santomauro F, Sacco C, Bergonzi MC, Donato R: **Essential Oil of Artemisia annua L.: An Extraordinary Component with Numerous Antimicrobial Properties**. *Evidence-based complementary and alternative medicine : eCAM* 2014, **2014**:159819.
99. Elfawal MA, Towler MJ, Reich NG, Golenbock D, Weathers PJ, Rich SM: **Dried whole plant Artemisia annua as an antimalarial therapy**. *PloS one* 2012, **7**(12):e52746.

Tables

Table 1: Effect of administration of metronidazole or Artemisia Annua on trophozoite count in small intestine

Groups	Trophozoite count (Mean ± SEM)	
		% reduction
Infected untreated group	24.00± 9.327	-
Metronidazole-treated group	1.80± 1.304[b]	92.5
Artemisia Annua-treated group	0.40 ± 0.548 [b,c]	98.3

Statistical analysis of the trophozoite count in the intestinal tissue of infected hamsters. Data were analyzed using ANOVA and Bonferroni corrections as a post hoc test. Data were expressed as Mean±SD.

b significant difference against Infected untreated group (P< 0.001)

c significant difference against Metronidazole-treated group (P< 0.001)

Table 2: Serum levels of NOx, IL-6, INF-γ and TNF-α levels after treating infected hamster with metronidazole or Artemisia Annua.

Groups	Serum NOx levels (µmol/ml)	Serum IL-6 level (pg/ml)	Serum IFN-γ level (pg/ml)	Serum TNF-α level (pg/ml)
Uninfected	88.20± 2.950	22.80 ± 3.194	32.25 ± 2.9	17.00 ± 1.82
Infected untreated	76.80± 6.099[a]	190.60 ± 11.082 [a]	180.5 ± 3.87[a]	222.25 ± 11.02[a]
Metronidazole-treated	102.60±5.320[a,b]	84.80 ± 9.654[b]	67.75 ± 3.77[b]	61.25 ± 1.70[b]
Artemisia Annua-treated	92.80 ± 9.884[c]	114.40 ± 7.733[b,c]	123.75 ± 8.53[b,c]	88.5 ± 7.3[b,c]

Data were analyzed by one way analysis of variance (ANOVA) test for comparison of the mean between groups with Bonferroni corrections as a post hoc test. Values are Means ± SD. (n=8).

For serum nitric oxide end product (NOx) levels; **a** significant difference versus UI group ($p<0.001$), **b** significant difference versus IGL ($p<0.001$), **c** significant difference versus IGL group ($p<0.001$).

For serum IL-6, INF-γ and TNF-α levels; **a** significant difference versus UI group. **b** significant difference versus IGL group. **c** significant difference versus M group. ($p<0.05$).

UI uninfected group. IGL infected with giardia lamblia. Met infected and treated with metronidazole. AA infected and treated with Artemisia Annua.

Figures

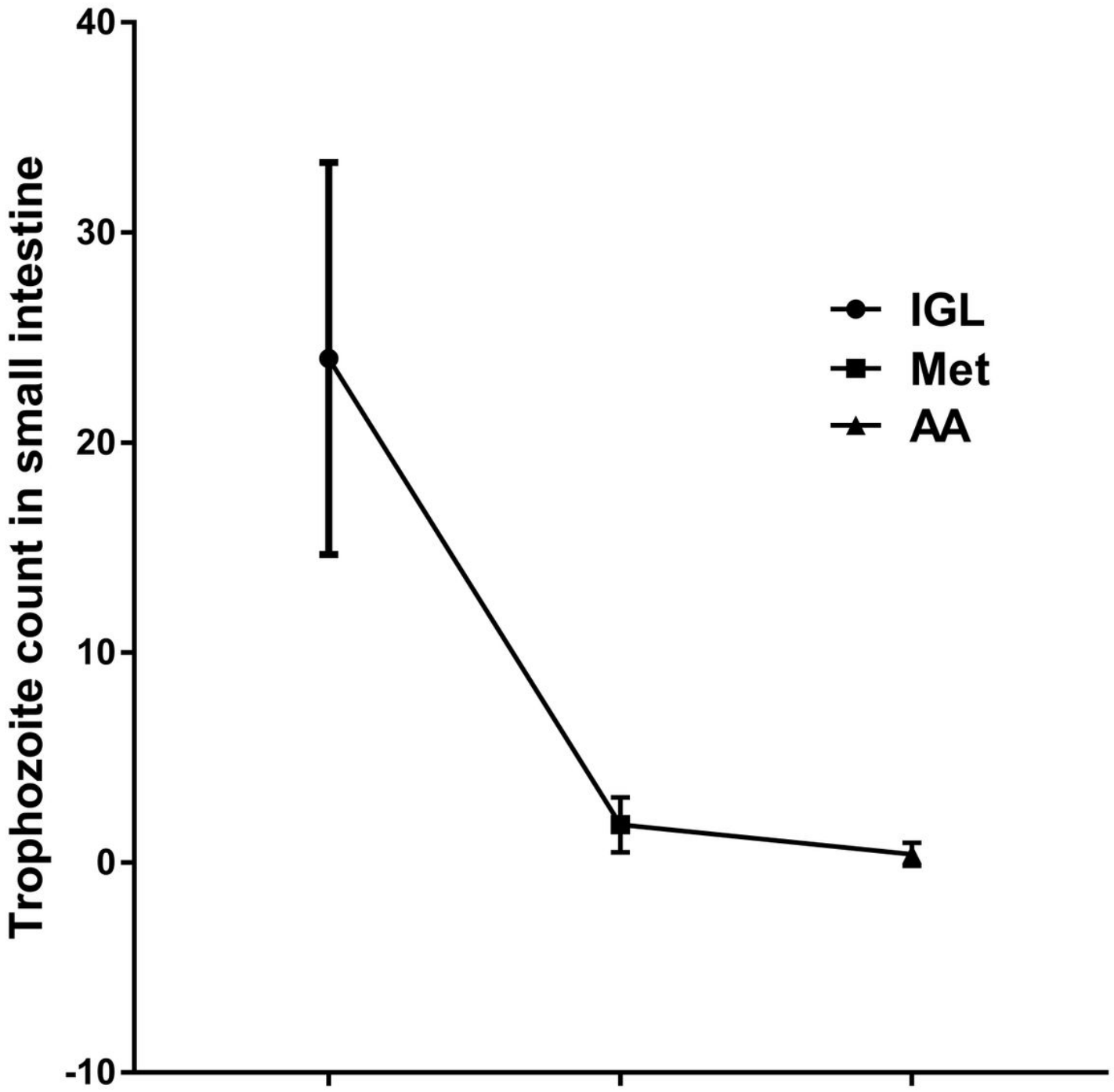

Figure 1

Graphical representation of trophozoite count in the small intestine of gerbils on day 21 post-infection. Treatment of infected animals with metronidazole or Artemisia annua significantly decreased the trophozoite count compared to infected untreated gerbils. Data were analyzed with ANOVA and Bonferroni corrections for pairwise comparison. Data expressed as Mean ± SD (n=8). $p<0.001$ against infected untreated group.

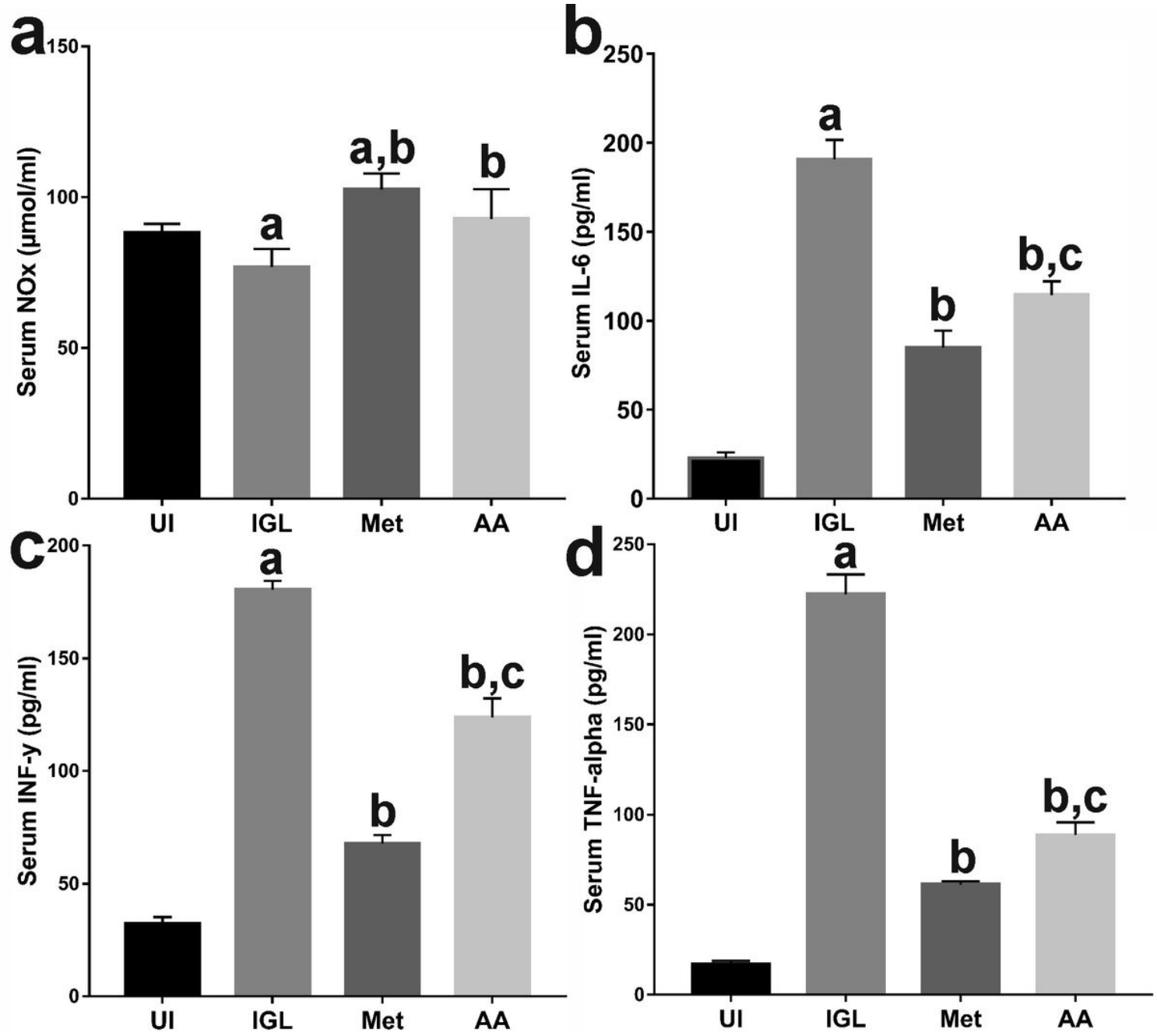

Figure 2

The effect of treating infected animals with metronidazole or Artemisia annua on different parameters. (a) serum nitric oxide end products (NOx) levels in different groups. a significant difference versus UI group ($p<0.001$), b significant difference versus IGL ($p<0.001$), c significant difference versus Met group ($p<0.01$). (b) serum levels od IL-6 in different groups. (c) serum levels of IFN-γ. (d) serum levels of TNF-α. a significant difference versus UI group. b significant difference versus IGL group. c significant difference versus Met group. ($p<0.05$). Data were analyzed using ANOVA and Bonferroni corrections as a post hoc test. Values are Means ± SD. Eight animals were used to assess these parameters. UI uninfected group. IGL infected with giardia lamblia. Met infected and treated with metronidazole. AA infected and treated with Artemisia annua extracts.

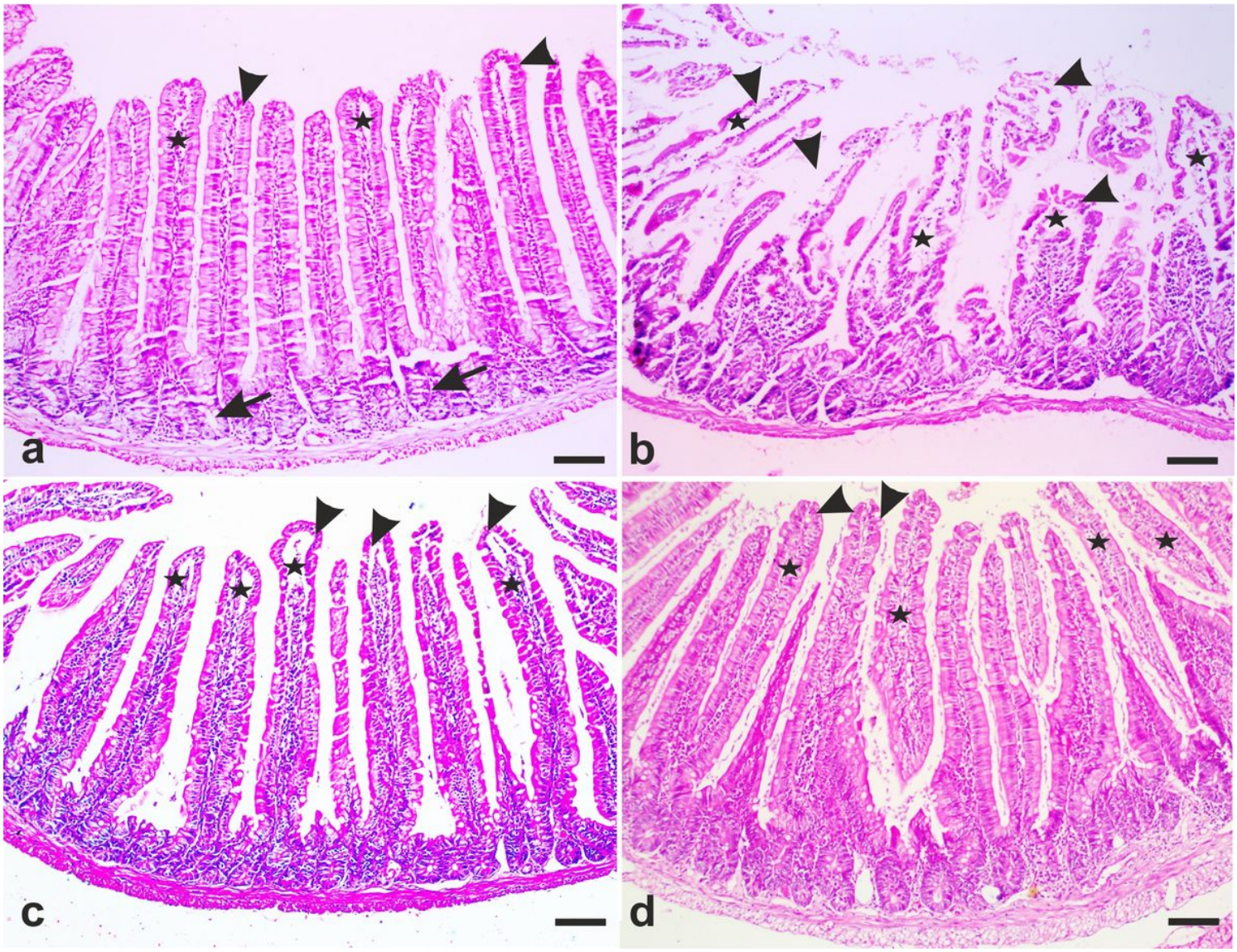

Figure 3

Representative photomicrographs of small intestinal sections of hamster stained with hematoxylin and eosin. (a) A section from uninfected hamster showing intact villi (arrowheads) and crypts (arrows). Stars depict connective core of the villi. b showing a section from animals infected untreated with shortening and disruption of villi (arrowheads). Stars refer to retraction of the connective tissue core of the villi. c showing section of infected animals and treated with metronidazole with well formed mucosal epithelial lining of the villi (arrowheads) and intact villus cores (stars). (d) A section from infected gerbils and treated with Artemisia annua extracts showing well-formed villi (arrowheads) with regular epithelial lining and intact connective tissue core (stars). Scale bars = 100 μm.

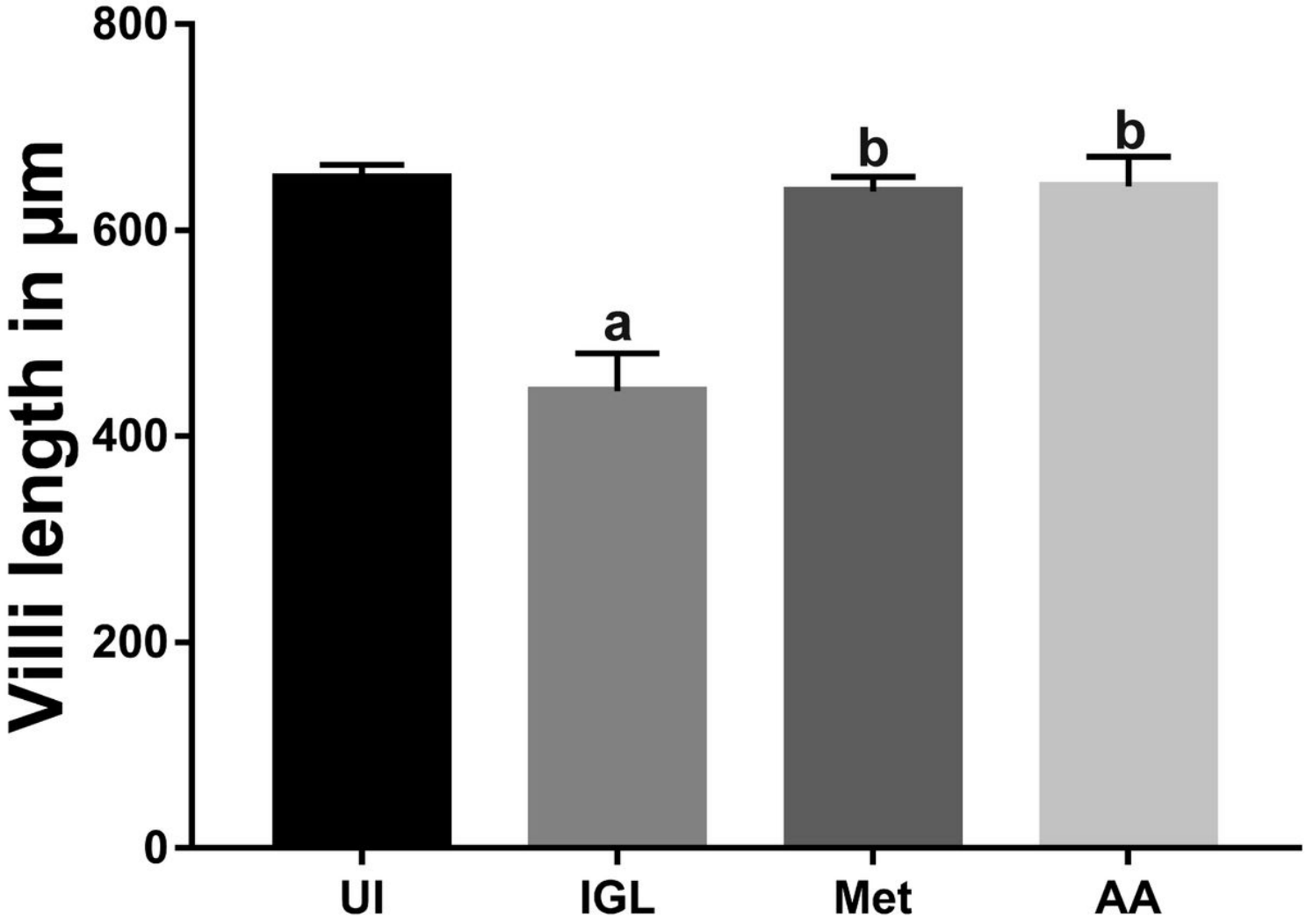

Figure 4

Small intestine villi length assessed with ImageJ software using pictures stained with hematoxylin and eosin and captured at 100x. Treating infected gerbils with Artemisia annua extracts significantly increased the mean villous length compare to infected untreated hamster.. This effect was comparable to the effect of treating infected animals with metronidazole. a significant difference versus UI group. b significant difference versus IGL. ($p<0.001$). Data were analyzed using ANOVA test to compare the mean differences between groups and Bonferroni corrections as a post hoc test. Data are Means ± SDs. (n=3). UI uninfected group. IGL infected with giardia lamblia. Met infected and treated with metronidazole. AA infected and treated with Artemisia annua extracts.

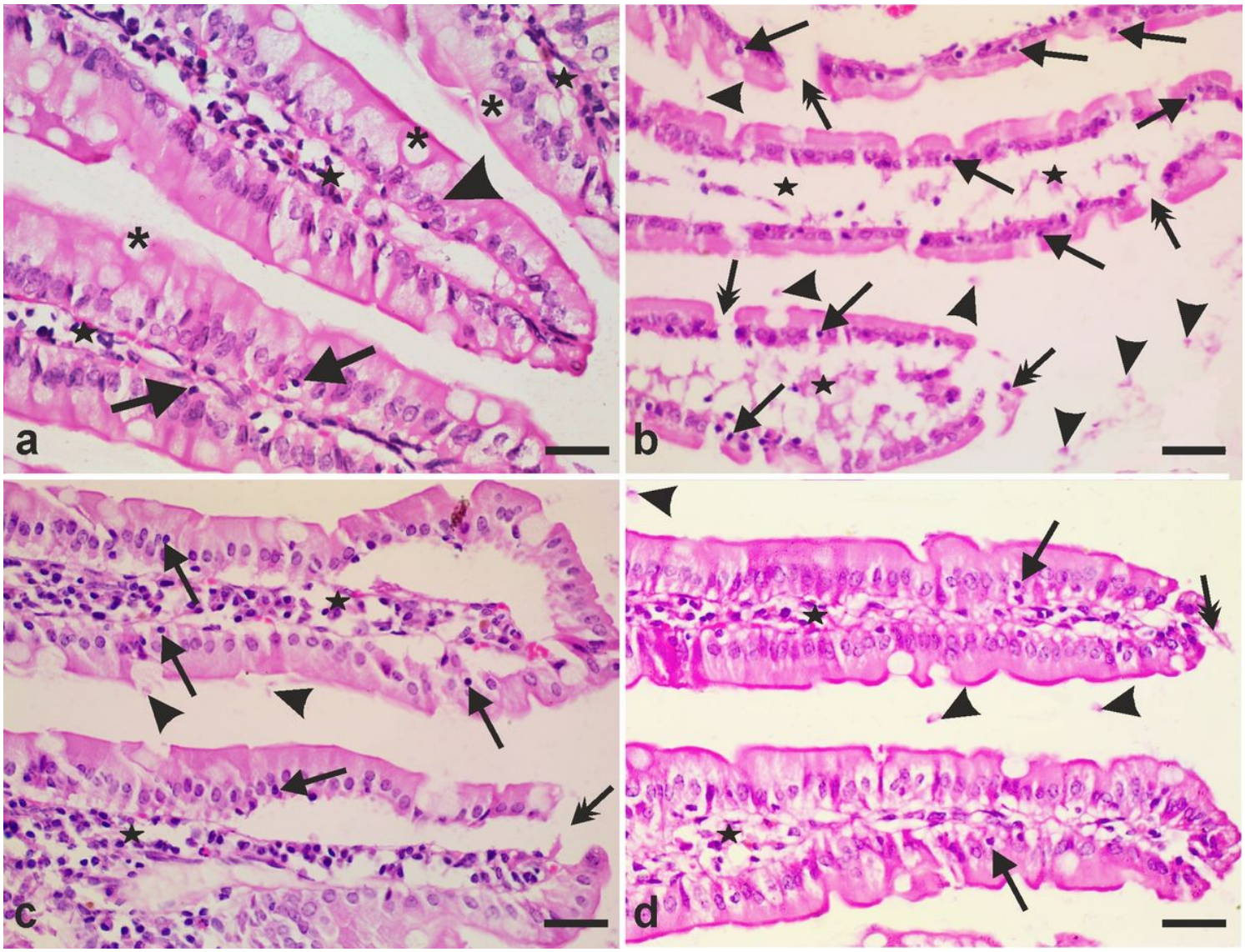

Figure 5

Photomicrographs of higher magnification images of small intestinal tissue stained with hematoxylin and eosin. (a) A section of uninfected animals showing intact intestinal villi that are covered with simple columnar epithelium (arrowheads) with goblet cells (asterisks). Stars refer to villi core. Note, few lymphocytes were seen in the epithelium (arrows). b showing a section of infected untreated gerbils with disruption of the mucosal epithelium (double-headed arrows) and marked increase in the intraepithelial lymphocytes (arrows). Stars denote retracted villi core with few scattered connective tissue cells. Note, the presence of giardia trophozoite between villi (arrowheads). (c) A section of infected hamster treated with metronidazole showing mucosal epithelium with few desquamated cells (double-headed arrows) and regeneration of the villi core (stars). Arrows point to intraepithelial lymphocytes while arrowheads denote giardia trophozoites in the intervillous spaces. (d) A section of infected animals treated with Artemisia annua showing preserved intestinal villi with few desquamated cells (double-headed arrows) and intraepithelial lymphocytes (arrows). Stars point to intact villi core. Note, few giardia trophozoite found between the villi (arrowheads). Scale bar = 30 μm.

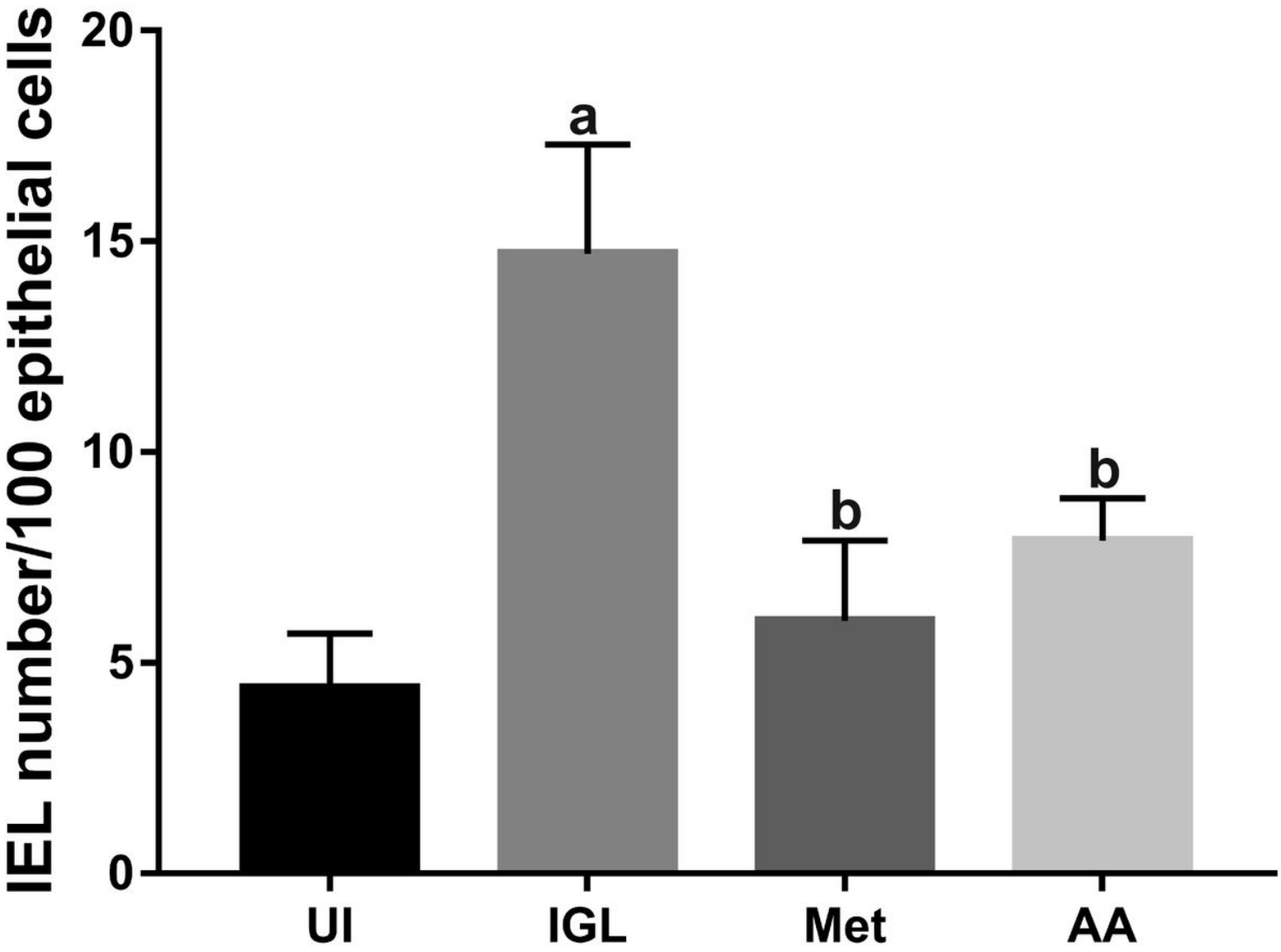

Figure 6

Graphical representation of intraepithelial lymphocytes (IEL) counts. Images stained with hematoxylin and eosin were used to assess IEL count. Infection of gerbils with giardia trophozoites significantly increased IEL count compared to uninfected animals. Treatment of infected gerbils with Artemisia annua significantly decreased IEL count compared to infected untreated animals. No significant difference was found between treating infected animals with metronidazole or Artemisia annua. a significant difference versus UI group. b significant difference versus IGL. ($p<0.001$). Data were analyzed using ANOVA test to compare the mean differences between groups and Bonferroni corrections as a post hoc test. Data are Means ± SDs. (n=3). UI uninfected group. IGL infected with giardia lamblia. Met infected and treated with metronidazole. AA infected and treated with Artemisia annua.

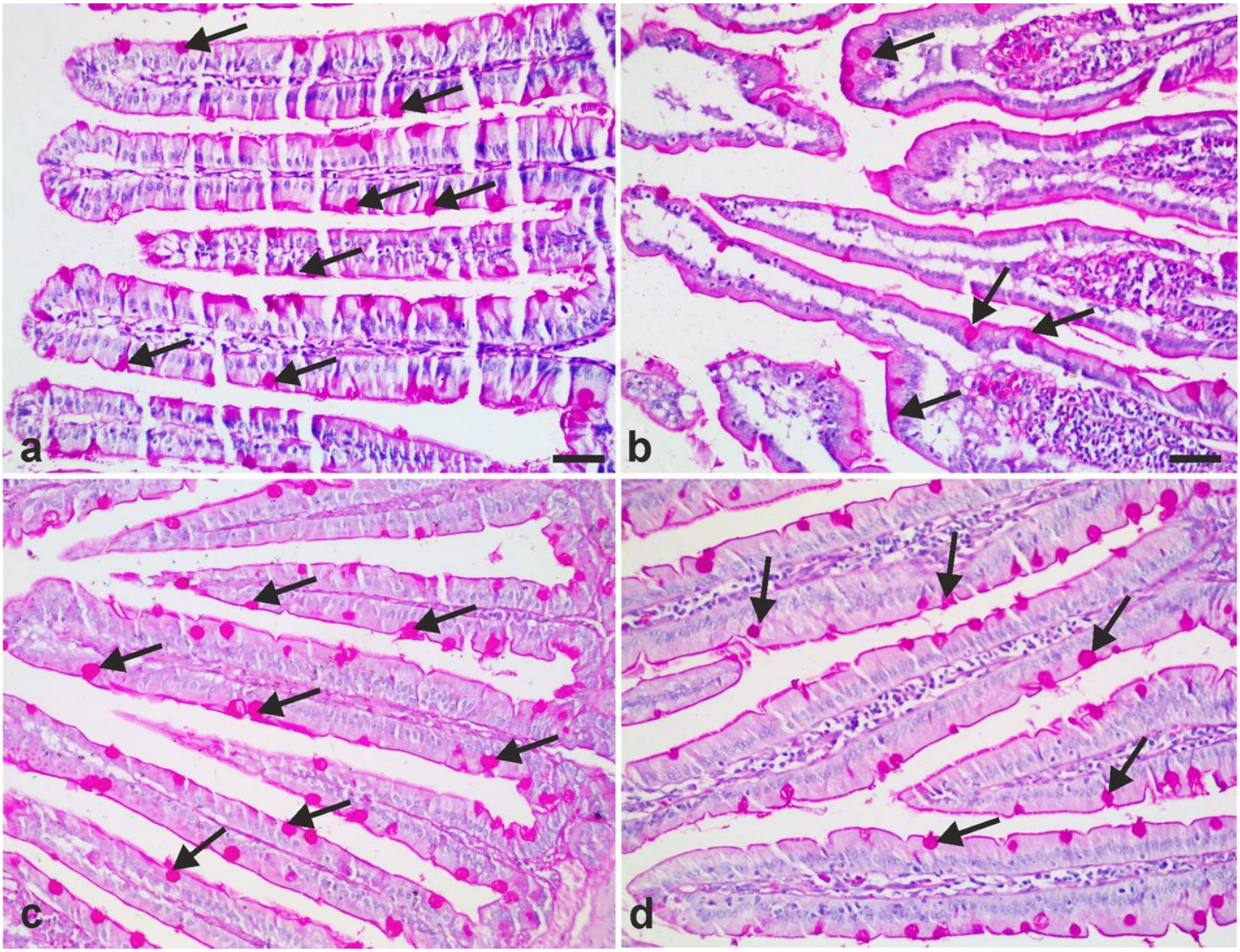

Figure 7

Photomicrographs of small intestine stained with Periodic Acid Schiff (PAS) and hematoxylin to demonstrate goblet cells. (a) A section of uninfected hamster showing intestinal villi with goblet cell scattered between epithelia cells. b showing depletion of goblet cells in tissue section of infected untreated gerbils. (c) A section of infected animals treated with metronidazole showing restoring goblet cells in epithelial covering the villi. (d) A sections of infected animals treated with Artemisia annua extracts has recovered goblet cells from the effect of giardia trophozoites. Scale bar= 50 µm.

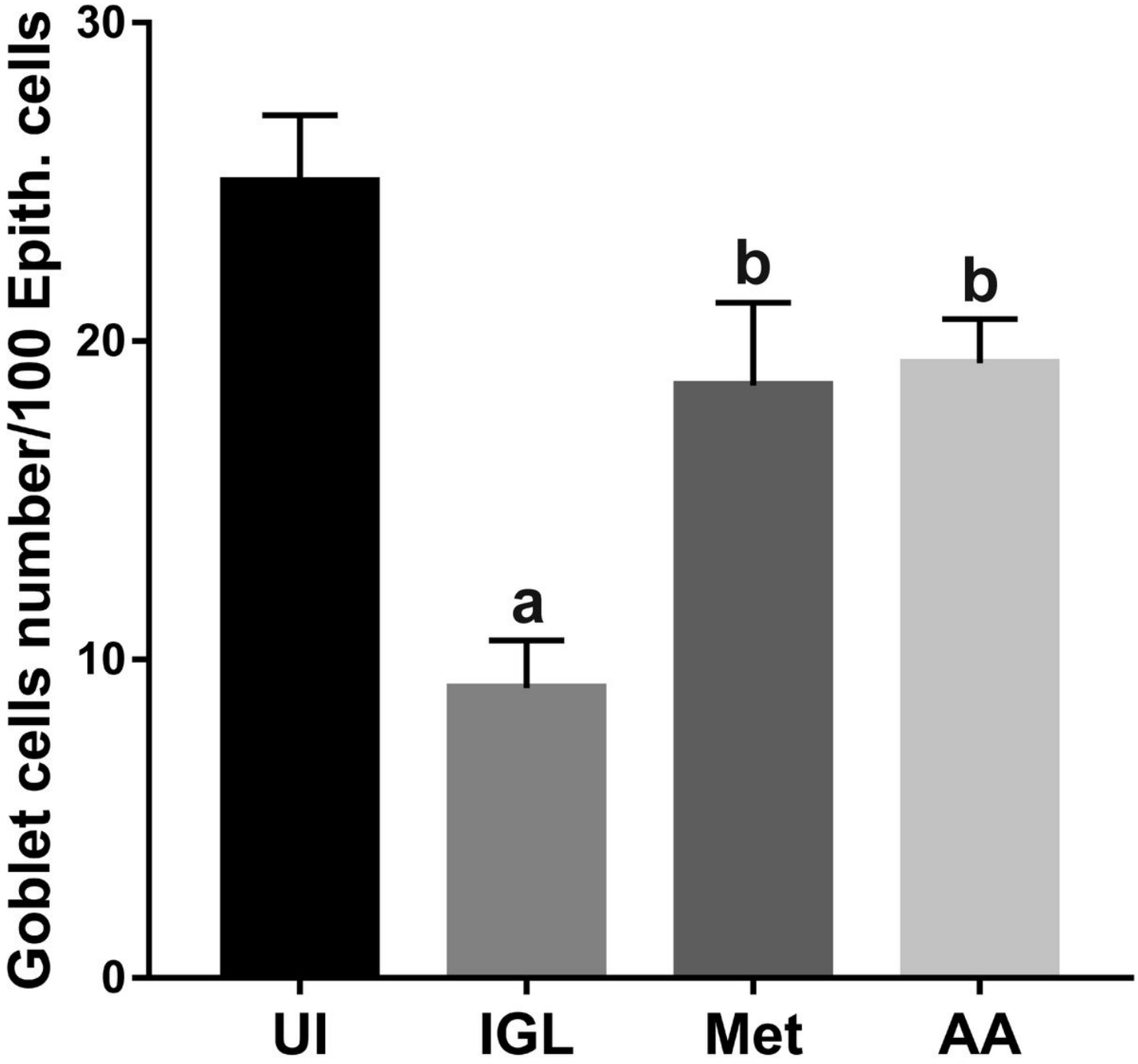

Figure 8

Goblet cell number in small intestine of gerbils belonging to different groups. Images stained with PAS and hematoxylin were used for assessment of this parameter. Artemisia annua extracts treatment of infected animals significantly increased the goblet cell number compared to infected untreated animals. The effect of Artemisia annua extracts was comparable to that of metronidazole treatment. a significant difference versus UI group. b significant difference versus IGL. ($p<0.001$). Data were analyzed using ANOVA test to compare the mean differences between groups and Bonferroni corrections as a post hoc test. Data are Means ± SDs. (n=3). UI uninfected group. IGL infected with giardia lamblia. Met infected and treated with metronidazole. AA infected and treated with Artemisia annua extracts.

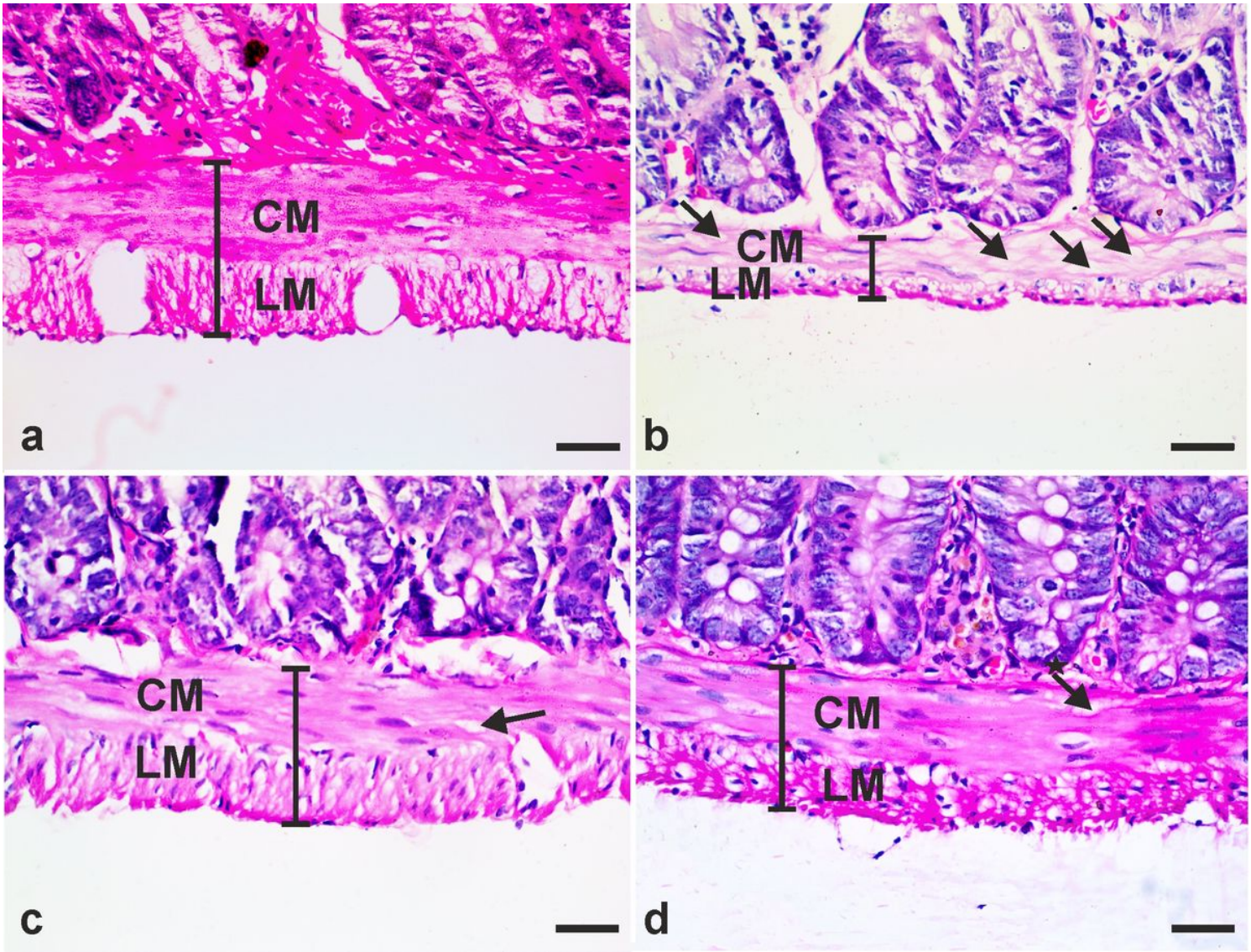

Figure 9

Representative photomicrographs of small intestine stained with hematoxylin and eosin showing the muscularis externa. (A) A section of uninfected animals showing well-formed muscularis externa composed of smooth muscle fibers arranged in two layers; inner circular (CM) and outer longitudinal (LM) layers. b showing a section of infected untreated gerbil with extensively vacuolated muscle fibers (arrows). Note, decreased thickness of muscularis externa. c showing a section of small intestine of infected animals and treated with metronidazole. . Note, few muscle fibers with vacuolation were observed (arrows). (d) A small intestine section taken from animals infected and treated with Artemisia annua extract showing well-formed muscularis externa layers. Note, few fibers with vacuolations were observed (arrows). In all panels, the vertical lines with brackets indicate the muscularis externa thickness. Scale bar = 30 μm.

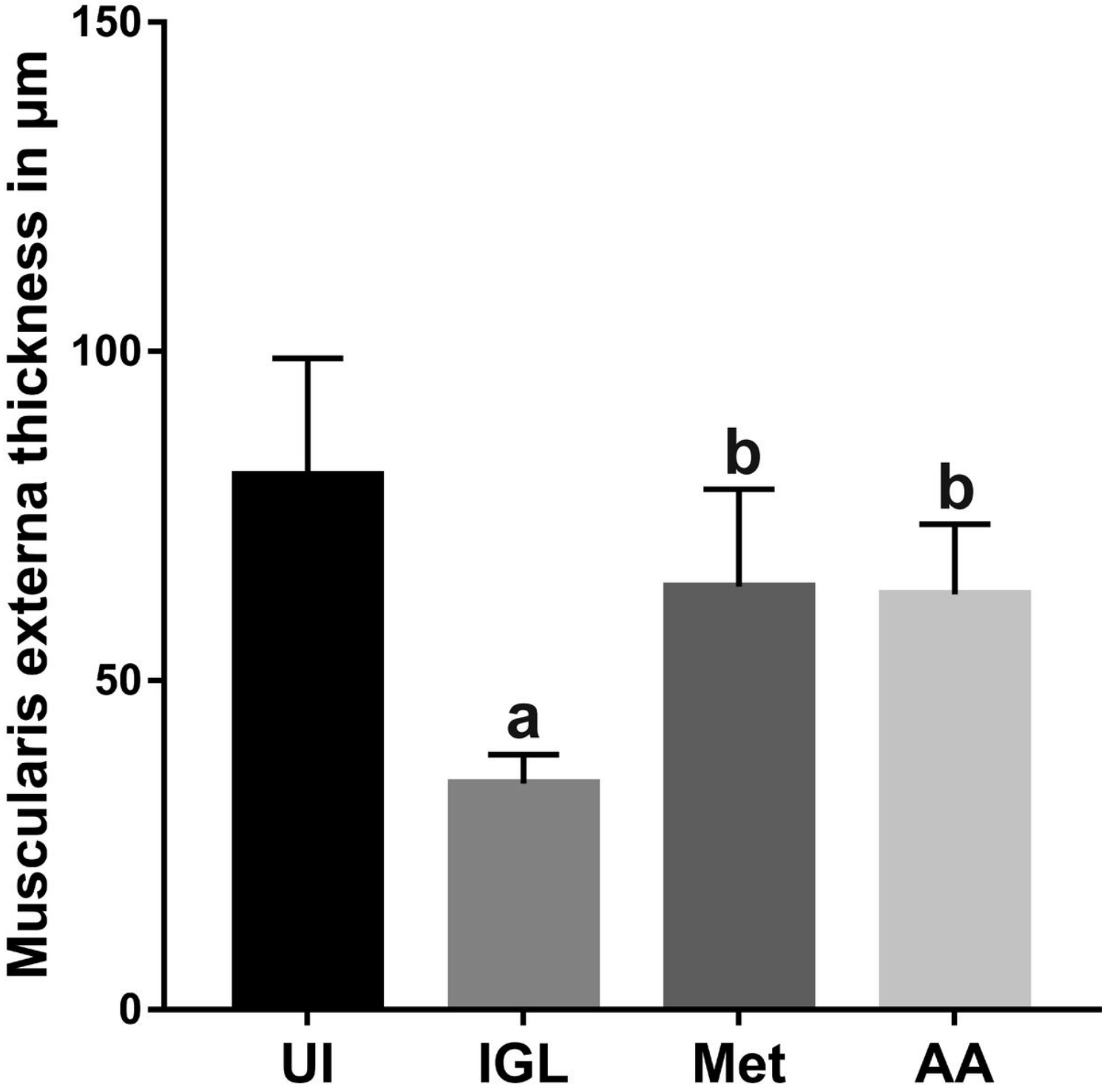

Figure 10

Graphical representation of the mean muscularis externa thickness. Infection of gerbils with giardia trophozoites significantly decreased the mean muscularis externa thickness compared to uninfected animals. Treatment of infected gerbils with Artemisia annua extracts significantly reduced the mean muscularis externa thickness compared to infected untreated animals. The effect of Artemisia annua extracts treatment on the mean muscularis thickness was comparable to that of metronidazole. a significant difference versus UI group. b significant difference versus IGL. ($p<0.001$). Data were analyzed

using ANOVA test to compare the mean differences between groups and Bonferroni corrections as a post hoc test. Data are Means ± SDs. (n=3). UI uninfected group. IGL infected with giardia lamblia. Met infected and treated with metronidazole. AA infected and treated with Artemisia annua extracts.

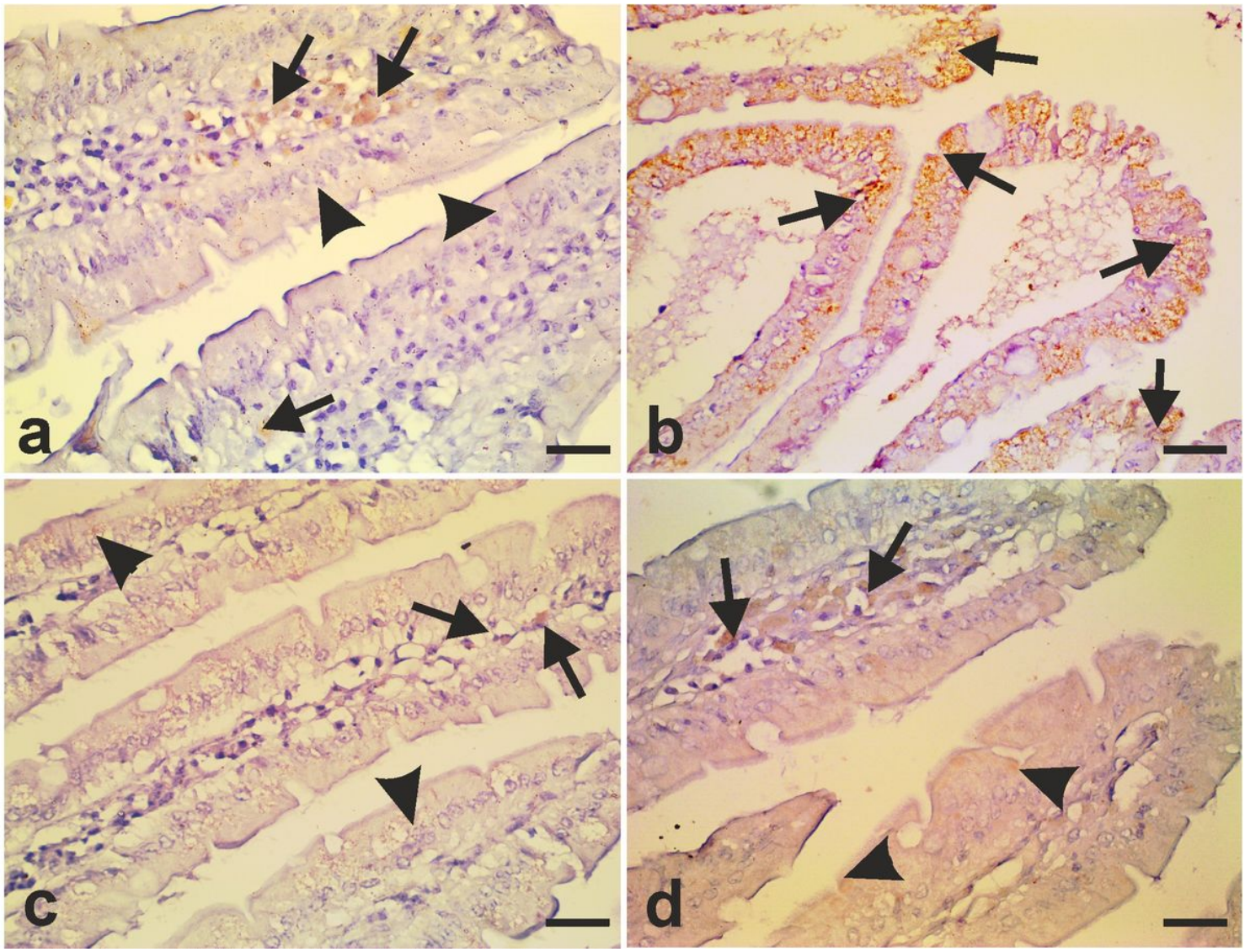

Figure 11

Representative micrographs of iNOS expression in small intestinal tissues. (A) iNOS expression is localized in core cells of infected untreated animals (arrows). Note; no iNOS immunoreactivity in enterocytes. b showing intense iNOS immunopositivity in enterocytes of infected untreated animals (arrowheads). c showing moderate iNOS immunoreactivity in cores cells (arrow) as well as enterocytes (arrowheads) of animals infected and treated with metronidazole. (d) low iNOS expression by villi-core mononuclear cells after treating infected gerbils with Artemisia annua extracts (arrows). Arrowheads depict barely seen iNOS signals in villi epithelial cells. Scale bar= 30 μm.

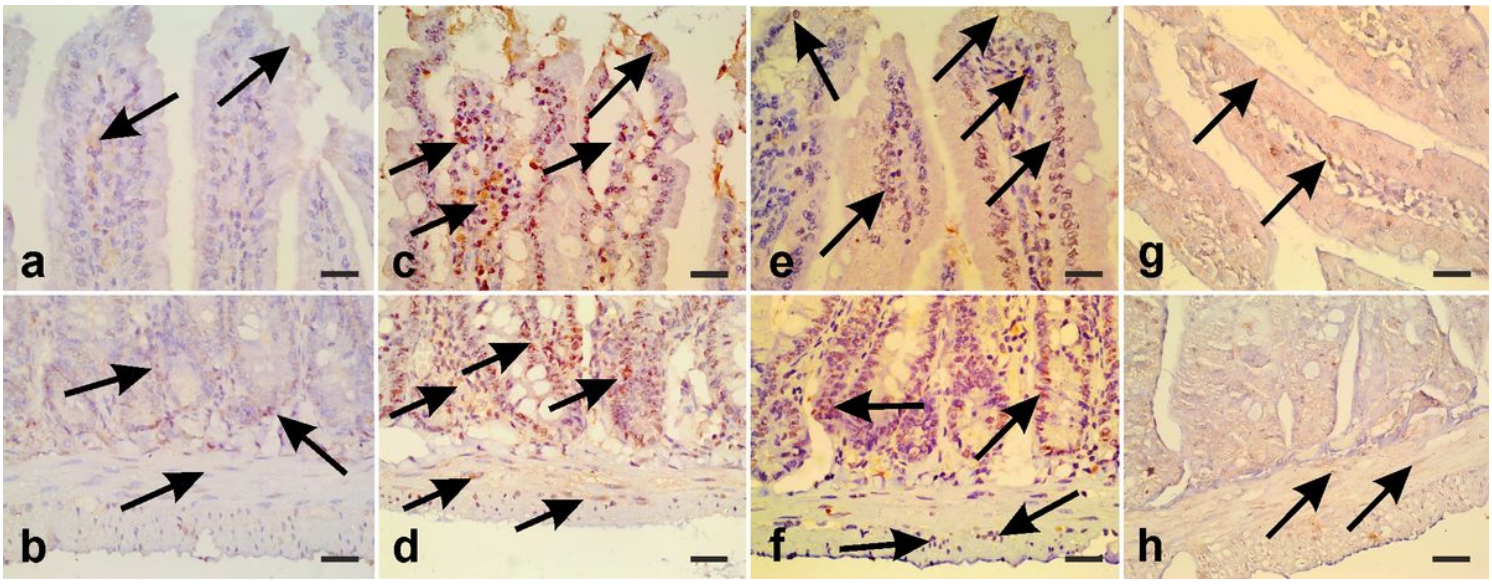

Figure 12

Representative micrographs of small intestinal sections illustrating expression of caspase-3 by immunohistochemistry. (A and B) Sections of small intestine of uninfected gerbils. Arrows depicts weak caspase-3 signals. c showing strong caspase-3 signals in enterocytes and lamina propria cells (arrows) while d represents cells of crypts and muscularis externa markedly immunostained with caspase-3 antibodies (arrows). e showing a moderate expression of caspase-3 in the enterocytes and villi core cells of small intestinal sections of animals infected with giardia trophozoites and treated with metronidazole (arrows). f A moderate caspase-3 staining pattern in crypt cells and muscularis externa of animals as in e. g and h showing a low caspase-3 expression pattern in tissue of animals infected with giardia trophozoites and treated with Artemisia annua. Scale bar= 30 μm.

Supplementary Files

This is a list of supplementary files associated with this preprint. Click to download.

- Graphicalabstract.tif