

Venous Thromboembolism and Ovarian Torsion-detorsion in Pregnancy: a Case Report and Systematic Review of the Literature

Peng Zhao (✉ zhaopeng0622@zju.edu.cn)

Zhejiang University School of Medicine Women's Hospital

Ying Zhao

Zhejiang University School of Medicine the Forth affiliated hospital

Quan Zhang

Zhejiang university school of medicine the forth affiliated hospital

Zhu Zhou

Zhejiang university school of medicine the forth affiliated hospital

Jianhong Zhou

Zhejiang University School of Medicine Women's Hospital

Fei Ruan

Zhejiang University School of Medicine Women's Hospital

Case report

Keywords: Adnexal torsion, Ovarian torsion, Detorsion, Venous thromboembolism, Pulmonary embolism, Low molecular weight heparin

Posted Date: December 1st, 2020

DOI: <https://doi.org/10.21203/rs.3.rs-114658/v1>

License: © ⓘ This work is licensed under a Creative Commons Attribution 4.0 International License.

[Read Full License](#)

Abstract

The safety of adnexal detorsion in pregnant women is debatable as the hypercoagulable state during pregnancy intensifies the risk of thromboembolism. The diagnosis and treatment is challenging because its rarity and complexity due to the foetal health. Here we presented a rare case of venous thromboembolism (VTE) after ovarian detorsion during early pregnancy and conducted a review of the literature. VTE after ovarian torsion-detorsion in pregnancy is an infrequent event and is more likely to occur in the first and second trimester. The diagnosis depends mainly on the clinical manifestation, D-dimer level and imaging tests such as compression ultrasonography and computed tomography pulmonary angiogram. Low-molecular-weight heparin remains the drug of choice for both prophylactic measurement and therapeutic strategy. With prompt diagnosis and immediate treatment, VTE after ovarian torsion-detorsion is usually uneventful.

Introduction

Ovarian torsion during pregnancy, although fairly uncommon, is a well-recognized gynaecological emergency. It has been assumed that venous thromboembolism (VTE), being the leading cause of maternal death, was associated with ovarian torsion-detorsion. In order to avoid the release of emboli from the thrombotic vessels in the twisted adnexa, salpingo-oophorectomy without unwinding the adnexa was once the preferred surgical strategy [1]. However, in recent years, researchers have been advocating adnexal detorsion in place of salpingo-oophorectomy with the claim that infarcted adnexa were rarely attributed to VTE [2–5]. As a result, adnexal detorsion has now taken over as the mainstay of treatment for adnexal torsion to preserve ovarian function in young women. Even so, the safety of adnexal detorsion in pregnant women is still debatable as the hypercoagulable state during pregnancy intensifies the risk of thromboembolism. Consequently, we presented a case report of VTE after ovarian detorsion in pregnancy and conducted a systematic review of the literature.

Case Report

A 28-year-old women, gravida 1, para 0, in the 7th week of gestation was admitted to our hospital, complaining of lower abdominal pain and vomiting. Bimanual examination showed a pelvic mass and a point of tenderness in the right lower abdominal quadrant. Laboratory results revealed that the white blood cell count, C-reactive protein, hepatic enzymes and urine analysis were within normal ranges. Transvaginal ultrasound showed one intrauterine gestational sac with a viable embryo. The left adnexa were normal whereas the right ovary was enlarged, measuring 8.5*7.3*5.3 cm and a 6.9*5.8*4.8 ovarian cyst could be appreciated with an absence of vascular flow. The kidneys, pancreases, gall bladder and appendix showed no signs of abnormalities. In view of the above-mentioned findings, an explorative laparotomy was performed and an ischemic oedematous ovary was noted, containing a haemorrhagic corpus luteum cyst, around two thirds of which was dark bluish in colour and twisted for 1080 degree.

Detorsion of the twisted adnexa was done and re-colouration of the adnexa was noted during the observation period. Therefore, ovarian cystectomy was performed. The post-operative pathology report described a corpus luteum cyst. The necessary measures to prevent thrombosis were taken. For instance, early ambulation and anti-embolism stockings were encouraged. Nevertheless, on the third post-operative day, the patient complained of calf pain in her right leg. Palpation of the affected limb showed Neuhof's sign positive. Ultrasonography revealed an extensive thrombosis within the deep veins of her right leg. An elevated D-dimer of 2.4 mg/l was noted. The patient commenced on low weight molecular heparin (LWMH, Nadropin calcium) 4100 IU twice daily subcutaneously for 14 days. By the 10th day of treatment, the level of D-dimer dropped to 0.55 mg/l. Moreover, the follow-up ultrasonography performed at her 3 months review showed that the deep vein thrombosis in her right leg had completely disappeared. The patient eventually delivered a healthy infant at 39 weeks of gestation. Prophylactic administration of low-molecular-weight heparin (LMWH) was initiated after the delivery and the postpartum ultrasound examinations showed no signs of any further venous thrombosis.

Discussion

One may argue that the current study is a case of ovarian torsion simultaneously with an event of VTE; however, we believe there is no need to debate as it is virtually impossible to confirm the relationship between ovarian torsion and VTE. The clinical significance of this study is to remind physicians that 1) VTE could occur after ovarian detorsion during pregnancy; 2) Early ambulation and anti-embolism stockings may not prevent VTE and therefore 3) the epidemiology, diagnosis and treatment regimens should be reviewed due to its rarity and complexity regarding to foetal health during pregnancy.

Current research status

About 10–22% of adnexal torsion occurred during pregnancy [6, 7]. It is more likely to occur between the 10th week and the 17th week of gestation with an ovarian mass larger than 4 cm in diameter [8]. The venous thromboembolism risk was reported to be 0.03% in pregnant women, which is increased by 5 folds as compared to non-pregnant women [9, 10]. The above-mentioned data were mainly focused on the population of pregnant women. In addition to that, to the best of our knowledge, the subgroup of pregnancies with VTE after ovarian torsion-detorsion has seldom been evaluated. A comprehensive search was performed in Embase and PubMed. The search strategies were designed using controlled vocabulary and plain language without language restrictions (Supplementary material). As a result, there has been only one case of VTE and three cases of pulmonary embolism (PE) in patients with adnexal torsion in the literature across the globe. Three of four cases received adnexal resection without detorsion and all of the three cases were complicated with PE. One of four cases received cystectomy with detorsion and developed postoperative DVT. However, none of the cases occurred during pregnancy [Table 1]. Therefore, we are the first to present a case of an ovarian torsion in a pregnant woman which has been complicated with VTE after the surgical intervention with ovarian detorsion.

Table 1
Reports of venous thromboembolism after adnexal torsion

Author, year	age	Pregnant/non-pregnant	Torsion site	Surgery	Thromboembolic event
Jauch,1922(15)	19	non-pregnant	Fallopian tube	Salpingectomy without detorsion	Pulmonary embolism
McGovern,1999(11)	38	non-pregnant	Fallopian tube	Salpingectomy without detorsion	Pulmonary embolism
McGovern,1999(11)	16	non-pregnant	Left ovarian torsion	Detorsion + Cystectomy	deep vein thrombosis (right iliac vein)
McGovern,1999(11)	44	non-pregnant	Right adnexal torsion	Right salpingo-oophorectomy without detorsion	Pulmonary embolism

Epidemiology

In order to evaluate the epidemiological characteristics of pregnancies with post-detorsion VTE, we reviewed all of the medical records of our hospital from September 1991 to September 2019. Consequently, there were totally 256086 deliveries, out of which 260 cases had adnexal torsion and 17 cases had isolated fallopian tube torsion, amounting to an incidence of 0.11% and 0.007%, respectively. Of the 260 cases, 223 had ovarian tumour and 1 case developed VTE after the surgical detorsion, giving an incidence of 0.38% (Fig. 1 flow diagram).

Evaluation and diagnosis

The diagnosis of VTE after ovarian torsion-detorsion during pregnancy mainly depends on the clinical symptoms, physical examination and imaging tests. Patients with deep vein thrombosis (DVT) may present with calf pain, swelling and tenderness in the leg and a positive Neuhof's sign. On the other hand, those who develop iliac vein thrombosis may complain of inguinal, pelvic, or abdominal pain, and experience swelling of the entire leg. Pregnant women with a high suspicion of DVT should undergo a D-dimer test and compression ultrasonography (CUS). If the initial CUS is negative, repeat CUS must be performed when there is a high index of suspicion. In comparison with DVT, PE is more challenging to diagnose as the clinical presentation may be non-specific. One should be cautious of PE when the patient complains of weakness and faintness, which is usually considered as the normal recovery process after the surgical detorsion and is therefore neglected. Some may experience tachycardia and tachypnea [11]. Under such circumstances, a computed tomography pulmonary angiogram (CTPA) is highly recommended [12]. CUS should be performed after the confirmation of PE as DVT and PE are usually

associated. In our study, the patient presented with calf pain and soreness of the lower limb and the diagnosis was established with an elevated D-dimer level and CUS. We did not perform further test for PE as the patients showed no clinical signs of any respiratory or cardiovascular diseases.

Treatment

The prophylactic measurements after surgical detorsion during pregnancy are early ambulation, anti-embolism stockings and intermittent pneumatic compression devices. It should be noted that the prophylactic measurements may not be able to prevent VTE. As in our case, VTE occurred although early ambulation and anti-embolism stockings were applied. Unfractionated heparin (UFH) and LMWH are both safe during pregnancy as neither will cross the placenta. However, administration of anticoagulants need careful considerations as heavy bleeding has been reported in 1.98% of pregnancies [13]. In clinical practice, LMWH is the drug of choice for it is relatively easy to use and doses not require tedious monitoring. Guideline from the Royal College of Obstetricians and Gynaecologists [14] suggests that thromboprophylactic doses for antenatal LMWH should be based on weight with the most frequently used LMWH being Enoxaparin, Dalteparin and Tinzaparin. LMWH is recommended in therapeutic doses once daily or twice daily in the management of acute VTE in pregnancy. Nevertheless, for pregnant women with PE or severe VTE, LMWH should be initiated with therapeutic doses twice daily [12]. In the current study, we started the treatment with therapeutic doses twice daily, and the complete resolution of emboli occurred in two weeks.

Conclusion

In conclusion, VTE after ovarian torsion-detorsion in pregnancy is an infrequent event and is more likely to occur in the first and second trimester. The thrombotic events, compromising of DVT and PE, are life-threatening conditions and their diagnosis depends mainly on the clinical manifestation, D-dimer and imaging tests such as CUS and CTPA. LMWH remains the drug of choice for both prophylactic measurement and therapeutic strategy. With prompt diagnosis and immediate treatment, VTE after ovarian torsion-detorsion is usually uneventful.

Abbreviations

LMWH

low weight molecular heparin; UFH:Unfractionated heparin; VTE:Venous thromboembolism; PE:Pulmonary embolism; DVT:Deep vein thrombosis; CUS:compression ultrasonography; CTPA:Computed tomography pulmonary angiogram ;

Declarations

Authors' contributions

Study design: Peng Zhao, Jianhong Zhou, Fei Ruan; Literature search: Peng Zhao, Ying Zhao; Acquisition of data: Quan Zhang, Zhu Zhou; Data Synthesis and analysis: Ying Zhao, Quan Zhang, Zhu Zhou; Drafting of the manuscript: Peng Zhao, Ying Zhao, Quan Zhang, Zhu Zhou; Peng Zhao, Jianhong Zhou and Fei Ruan critically revised the manuscript for critical content.

Funding Information

None

Availability of data and materials

Not applicable

Ethics approval and consent to participate

This study was approved by the ethics committee of Women's Hospital, Zhejiang University School of Medicine.

Consent for publication

Written informed consent for publication was obtained from the patient.

Conflict of Interest

The authors declared no potential conflicts of interest with respect to the research, authorship, and/or publication of this article.

Author details

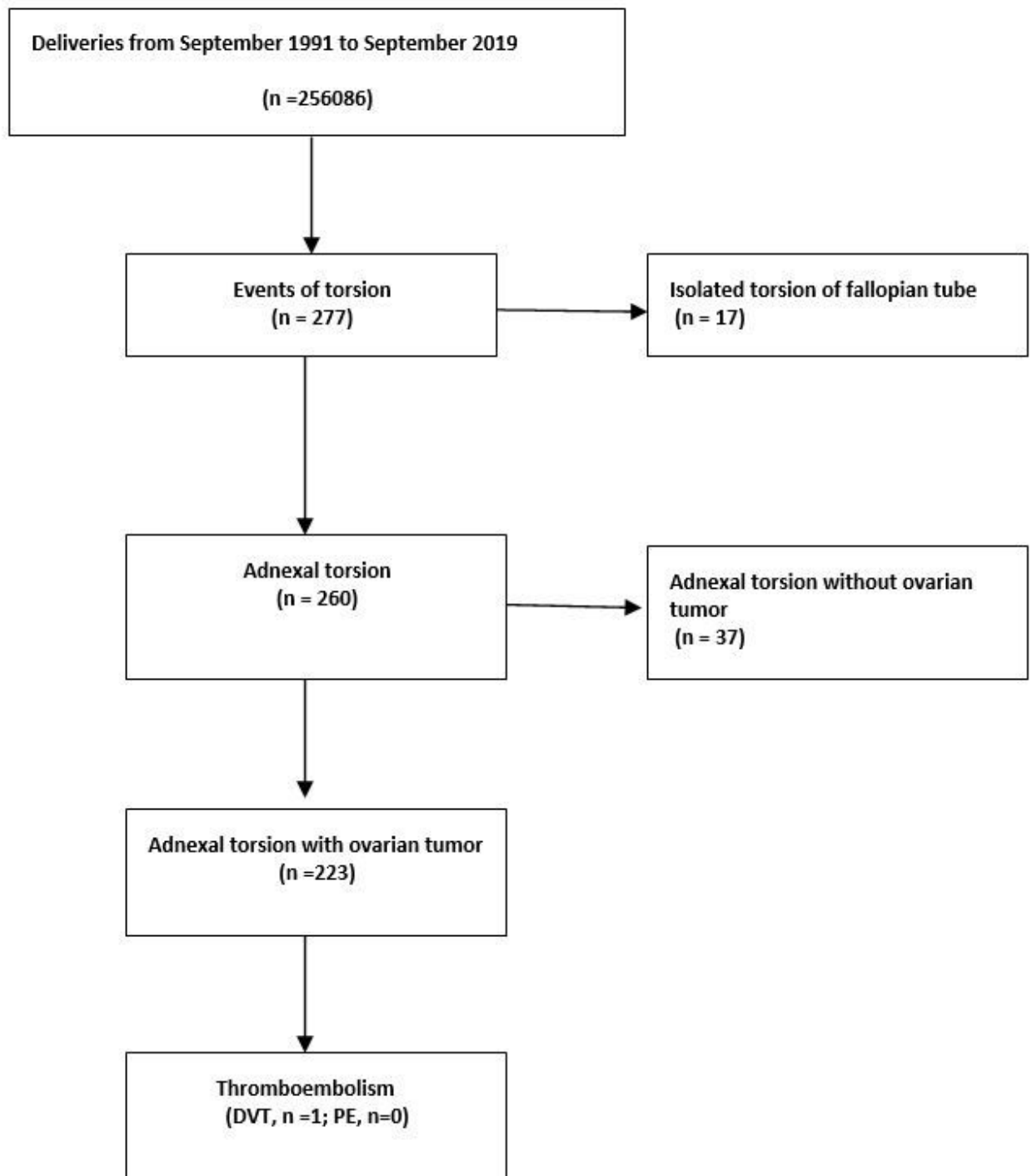
1. Department of Obstetrics, Women's Hospital, Zhejiang University School of Medicine, Hangzhou, China; 2. Department of Obstetrics and Gynecology, the Fourth Affiliated Hospital, Zhejiang University School of Medicine, Yiwu, China; 3. Department of Gynecology, Women's Hospital, Zhejiang University School of Medicine, Hangzhou, China.

References

1. Hibbard LT: **Adnexal torsion**. *AM J OBSTET GYNECOL* 1985, **152**(4):456-461.
2. Oelsner G, Bider D, Goldenberg M, Admon D, Mashiach S: **Long-term follow-up of the twisted ischemic adnexa managed by detorsion**. *FERTIL STERIL* 1993, **60**(6):976-979.
3. Zweizig S, Perron J, Grubb D, Mishell DJ: **Conservative management of adnexal torsion**. *AM J OBSTET GYNECOL* 1993, **168**(6 Pt 1):1791-1795.

4. Taskin O, Birincioglu M, Aydin A, Buhur A, Burak F, Yilmaz I, Wheeler JM: **The effects of twisted ischaemic adnexa managed by detorsion on ovarian viability and histology: an ischaemia-reperfusion rodent model.** *HUM REPROD* 1998, **13**(10):2823-2827.
5. Hasiakos D, Papakonstantinou K, Kontoravdis A, Gogas L, Aravantinos L, Vitoratos N: **Adnexal torsion during pregnancy: report of four cases and review of the literature.** *J Obstet Gynaecol Res* 2008, **34**(4 Pt 2):683-687.
6. Huang C, Hong MK, Ding DC: **A review of ovary torsion.** *Ci Ji Yi Xue Za Zhi* 2017, **29**(3):143-147.
7. Seo SK, Lee JB, Lee I, Yun J, Yun BH, Jung YS, Chon SJ: **Clinical and pathological comparisons of adnexal torsion between pregnant and non-pregnant women.** *J Obstet Gynaecol Res* 2019, **45**(9):1899-1905.
8. Robertson JJ, Long B, Koyfman A: **Myths in the Evaluation and Management of Ovarian Torsion.** *J EMERG MED* 2017, **52**(4):449-456.
9. Friedman AM, Ananth CV, Prendergast E, Chauhan SP, D'Alton ME, Wright JD: **Thromboembolism incidence and prophylaxis during vaginal delivery hospitalizations.** *AM J OBSTET GYNECOL* 2015, **212**(2):221.
10. Greer IA: **Thrombosis in pregnancy: updates in diagnosis and management.** *Hematology Am Soc Hematol Educ Program* 2012, **2012**:203-207.
11. McGovern PG, Noah R, Koenigsberg R, Little AB: **Adnexal torsion and pulmonary embolism: case report and review of the literature.** *OBSTET GYNECOL SURV* 1999, **54**(9):601-608.
12. McLintock C, Brighton T, Chunilal S, Dekker G, McDonnell N, McRae S, Muller P, Tran H, Walters BN, Young L: **Recommendations for the diagnosis and treatment of deep venous thrombosis and pulmonary embolism in pregnancy and the postpartum period.** *Aust N Z J Obstet Gynaecol* 2012, **52**(1):14-22.
13. Greer IA, Nelson-Piercy C: **Low-molecular-weight heparins for thromboprophylaxis and treatment of venous thromboembolism in pregnancy: a systematic review of safety and efficacy.** *BLOOD* 2005, **106**(2):401-407.
14. Gynaecologists RCOG (ed.): **Green-Top Guideline No. 37b. Reducing the risk of thrombosis and embolism during pregnancy and the puerperium.** London: Royal College of Obstetricians and Gynaecologists; 2015.
15. Jauch FJ. **Acute torsion of a hydrosalpinx.** *Br Med J* 1922, **2**:83-84.

Figures



DVT, Deep Vein Thrombosis; PE, pulmonary embolism

Figure 1

Flow diagram

Supplementary Files

This is a list of supplementary files associated with this preprint. Click to download.

- [Supplementarymaterial.Searchstrategy.doc](#)