

The Effects of EMMPRIN/CD147 on Late Function and Histopathological Lesions of the Renal Graft

Magdalena Nalewajska

Pomorski Uniwersytet Medyczny w Szczecinie

Martyna Opara-Bajerowicz

Pomorski Uniwersytet Medyczny w Szczecinie

Krzysztof Safranow

Pomorski Uniwersytet Medyczny w Szczecinie

Andrzej Pawlik

Pomorski Uniwersytet Medyczny w Szczecinie

Kazimierz Ciechanowski

Pomorski Uniwersytet Medyczny w Szczecinie

Sebastian Kwiatkowski

Pomorski Uniwersytet Medyczny w Szczecinie

Ewa Kwiatkowska (✉ ewakwiat@gmail.com)

Pomeranian Medical University <https://orcid.org/0000-0002-9847-6589>

Research article

Keywords: EMMPRIN, CD147, renal transplantation, renal function, fibrosis

Posted Date: November 24th, 2020

DOI: <https://doi.org/10.21203/rs.3.rs-112164/v1>

License:   This work is licensed under a Creative Commons Attribution 4.0 International License.

[Read Full License](#)

Version of Record: A version of this preprint was published at Biology on February 1st, 2022. See the published version at <https://doi.org/10.3390/biology11020232>.

Abstract

Background/Aims:

Chronic kidney disease is associated with renal fibrosis, develops with the participation of fibroblasts and myofibroblasts from epithelial-to-mesenchymal transition (EMT). In cancer research, the key role of the glycoprotein EMMPRIN/CD147 in EMT has been proven. We evaluate how CD147/EMMPRIN affects long-term renal graft function and renal biopsy specimen lesions.

Patients and methods:

49 renal graft recipients who had a renal biopsy within the last 18 months were retrospectively reviewed. The mean period after kidney transplantation (Tx) was 70 months. At their most recent appointments, their concentrations of CD147/EMMPRIN were evaluated. Renal function at their most recent appointment was assessed, and so was the occurrence of delayed graft function (DGF) and estimated glomerular filtration rate (eGFR) at 1 year and the subsequent years of the follow-up period. Renal biopsy specimen lesions, mainly those related to renal fibrosis and tubular atrophy, were evaluated.

Results:

EMMPRIN concentration correlated positively with eGFR at the most recent appointment and with eGFR at 1 and 2 years after Tx, with $p < 0.05$, $R = 0.69$, $R = 0.39$ and $R = 0.40$, respectively. CD147/EMMPRIN levels correlated positively with urine protein concentrations, with $p < 0.05$ and $R = 0.73$. A positive correlation was found with the severity of renal biopsy specimen lesions such as CI, CT, CG, MM and AH ($p < 0.05$, $R = 0.39$, $R = 0.29$, $R = 0.41$, $R = 0.32$ and $R = 0.40$, respectively). Patients with a history of DGF had higher CD147/EMMPRIN concentrations ($p < 0.05$).

Conclusions:

EMMPRIN/CD147 is a glycoprotein that is linked to poorer long-term renal graft function. Also, its high concentration is associated with exacerbated IF/TA lesions and proteinuria.

Introduction

Despite different clinical causes of chronic kidney disease, each case is associated with the damaging effects of fibrosis. [1] Also, loss of renal graft function is linked to its fibrosis, followed by secondary tubular atrophy. The main cause of renal fibrosis is identified to be the activation and accumulation of fibroblasts and myofibroblasts in the interstitium, where they are surrounded by increased amounts of extracellular matrix (ECM). Renal myofibroblasts emerge de novo during renal fibrosis and represent the phenotype of fibroblasts that result from differentiation caused by cellular stress. [2] This type of fibroblasts or myofibroblasts come from the so-called residential quiescent tissue fibroblasts and vascular pericytes, or originate in epithelial-to-mesenchymal transition (EMT) and in bone marrow. [3] In EMT, epithelial cells transform into collagen-producing mesenchymal stem cells. The role of EMT in CKD

progression is commonly recognized. Many reports on cancers, their infiltration and the development of metastasis caused by EMT have attributed a considerable role to a glycoprotein known as cluster of differentiation 147 (CD147) or extracellular matrix metalloproteinase inducer (EMMPRIN). It is acknowledged as a marker for acute kidney injury. Its role in chronic kidney injury, however, is little known, while there are almost no reports on its activity in the renal graft. This paper evaluates how the serum concentration of CD147/EMMPRIN affects long-term renal graft function and renal biopsy specimen lesions related to its chronic injury in the form of interstitial fibrosis/tubular atrophy (IF/TA).

Patients And Methods

Patients

49 renal graft recipients who were in the care of the Clinical Department of Nephrology, Transplantology and Internal Medicine, Pomeranian Medical University, Szczecin, Poland were retrospectively reviewed. The study included patients who reported within a two-week period in 2019 for a standard follow-up appointment. As inclusion criteria, the patients were expected to have received their kidney transplant at least 1 year before, and have had a renal biopsy specimen taken within the last 12 to 18 months. The patients were after renal transplantation for an average of 70 months (ME). After kidney transplantation, all the patients received triple immunosuppressive therapy with glucocorticosteroids, a calcineurin inhibitor – tacrolimus or cyclosporin, and mycophenolate mofetil. In some of the patients the steroid therapy was discontinued during the long-term follow-up. The tested parameters were the highest value of eGFR (ZENITH GFR) achieved within the first 6 months post Tx, creatinine concentration and eGFR at the most recent appointment (when urine was being sampled for EMMPRIN determinations), and creatinine concentration and eGFR at 1, 2, 3, 4, 5 and 10 years post Tx. The GFR was estimated using the MDRD formula. Also, the occurrence of delayed graft function (DGF), defined as the need for hemodialysis within the first week after transplantation, was evaluated. Urinalysis was carried out with a focus on the presence of urine protein (mg/dL). At the most recent appointment, the plasma concentration of CD147/EMMPRIN was evaluated. The renal biopsy specimens were examined for such irregularities as interstitial inflammation (I), tubulitis (T), glomerulitis (G), peritubular capillaritis (PTC), the presence of C4D, interstitial fibrosis (CI), tubular atrophy (CT), vascular fibrous intimal thickening (CV), double contours of the GBM (CG), mesangial matrix expansion (MM), arteriolar hyalinosis (AH) and hyaline arteriolar thickening (AAH). Such recipient characteristics as age, sex, time from Tx, the BMI at the time of Tx and at the most recent appointment, PRA, CIT, and the numbers of mismatches for different types of HLAs, were evaluated. Donor characteristics, such as age, sex, creatinine concentration, eGFR and serum sodium concentration prior to organ procurement, were evaluated, as well. Patient details are presented in Table 1.

Methods

Plasma samples were centrifuged at 4,000 rpm for 10 minutes, and sediment-free plasma was stored at a temperature of -80 °C awaiting analysis. EMMPRIN concentration was assessed according to the

manufacturer's instructions using customized magnetic bead-based multiplex Luminex screening immunoassay kits (R&D Systems). The patients involved in the study were treated in line with the Declaration of Helsinki and the Declaration of Istanbul. The local ethics committee of the Pomeranian Medical University, Szczecin, Poland approved the study protocol – KB-0012/23/18 (05FEB2018).

Statistical analysis

We used Statistica 11 software (StatSoft, Tulsa, USA) for statistical analysis. The Shapiro-Wilk test was used to study the distribution. The distribution of EMMPRIN was significantly different from normal ($p < 0.05$). We used a nonparametric Mann-Whitney U test to compare the two groups. Spearman's rank correlation test was used to study correlations. Data that were not normally distributed were shown as the median [minimum-maximum]. P-values were significant if < 0.05 .

Results

The plasma concentration of EMMPRIN correlated positively with eGFR at the most recent appointment at 1 and 2 years post transplantation ($p < 0.05$, $R = 0.69$, $R = 0.39$, $R = 0.40$, respectively). EMMPRIN concentration correlated positively with urine protein levels ($p < 0.05$, $R = 0.73$), as shown in Figures 1, 2 and 3. A positive correlation with the exacerbation of renal biopsy specimen lesions, such as CI, CT, CG, MM, AH, was found ($p < 0.05$, $R = 0.39$, $R = 0.29$, $R = 0.41$, $R = 0.32$, $R = 0.40$, respectively), as shown in Figures 4 and 5.

The study group was divided into one group of patients with a history of DGF and another one of those with immediate renal graft function. It was established that the DGF group had significantly higher EMMPRIN levels ($p < 0.05$), as shown in Table 2.

Discussion

EMMPRIIN/CD147

EMMPRIIN, currently referred to as CD147 or EMMPRIN/CD147, is a membrane glycoprotein, which was originally discovered in various animal tissues and thus received different names. The name EMMPRIN (extracellular matrix metalloproteinase inducer) was given to its human equivalent, and it has been kept in use in order to underline its significant role in regulating metalloproteinases. It has been proven to stimulate MMP-1, MMP-2 and MMP-3. Its role in acute kidney injury (AKI) secondary to ischemia and in CKD progression has been observed. It is found in the kidney on the basolateral side of tubular epithelial cells. [4]

CD147/AKI

Ischemia-reperfusion injury (IRI) of the renal allograft is the main cause of delayed graft function (DGF). In an experimental study, IRI induced in murine models deprived of the gene coding for CD147 led to a

considerable reduction in the infiltration by neutrophils and macrophages and, consequently, a substantial drop in the degree of tubulointerstitial injury than in the models carrying that gene. [5] This experiment proved EMMPRIN's key role in exacerbating the inflammatory infiltration in this type of injury. By pharmacologically inhibiting CD147, Seizer prevented infiltration by neutrophils and macrophages/monocytes following myocardial infarction. [6] Its proinflammatory activity may be associated with some interaction with cyclophilin A (a ligand of CD147), which plays a crucial role in regulating inflammation. This mechanism has been proven to take place in numerous in vivo experiments in sepsis-induced AKI, bronchial asthma, lipopolysaccharide-induced lung injury and collagen-induced arthritis. [7] There are no reports on CD147 in the context of renal graft IRI, but its role in spreading inflammation can be deduced from the native kidney IRI model. Elevated CD147 concentrations have been shown to be present in acute kidney injury. [8] Moreover, its concentration has been observed to positively correlate with creatinine levels. Serum CD147 originates in soluble CD147 from leukocytes, and urine CD147 is related to tubular injury. Based on clinical research, this compound is believed to be the first candidate for a biomarker allowing for diagnosing AKI.[5,8] The occurrence of DGF is associated with a 2.9-times higher risk of renal allograft failure in the long-term follow-up, hence its importance as a prognostic factor. Also, some authors have reported that DGF increases the incidence of acute kidney rejection episodes. [9] In this study, patients with DGF during the early post-transplantation period had far higher CD147/EMMPRIN concentrations in the late post-transplantation period. This phenomenon could be associated with the activation of CD147 and its maintained increased expression in the kidney transplant in the long-term follow-up. In acute renal reperfusion injury, fibrotic processes due to EMT begin in the kidney, where CD147 plays the major role.

CKD vs EMT

Although there are various clinical causes of chronic kidney disease, progression in each case is associated with the damaging effects of fibrosis. [1] Renal fibrosis is characterized by tubulointerstitial fibrosis, glomerulosclerosis and destruction of renal structure. The main cause of renal fibrosis is found to be the activation and interstitial accumulation of fibroblasts and myofibroblasts surrounded by excessive amounts of extracellular matrix (ECM). Renal myofibroblasts emerge de novo during renal fibrosis and represent the phenotype of fibroblasts that result from differentiation caused by cellular stress. [2] This type of fibroblasts or myofibroblasts come from the so-called residential quiescent tissue fibroblasts and vascular pericytes, or originate in epithelial-to-mesenchymal transition (EMT) and in bone marrow. [3] In EMT, epithelial cells transform into mesenchymal stem cells. They acquire the capability to produce collagen. For EMT to develop fully, the basement membrane to which the epithelial cells adhere must be injured and the cells must migrate to the interstitium. EMT is the fundamental mechanism by which the kidney becomes fibrotic during the CKD process. It is also present in such physiological situations as embryogenesis. In pathological states, its main role consists in causing organ (mostly lung) fibrosis in the course of inflammation, and initiating cancer infiltration and metastasis. [10] The sort of EMT related to inflammation is a type of wound healing and scar formation and is referred to as type 2 EMT. If the inflammation induced by injury persists, fibroblast numbers are up dramatically and the organ's structure is damaged, which state is referred to as chronic type 2 EMT. [10] As mentioned above,

basement membrane damage is one of the main stages of EMT, as it allows the transformed cells to migrate to the interstitium. Matrix metalloproteinase-2 (MMP-2) is the key compound responsible for this phenomenon. [10] Since EMT was first discovered by Elizabeth Hay in 1960, many authors have proven its leading role in renal fibrosis and destruction in animal and human biopsy specimens. [10]

EMT vs CD147/EMMPRIN

It is known that CD147 abundant in the renal tubules is a very strong activator of MMP-2 – the basement membrane-degrading metalloproteinase required for EMT to take place. [11] An in vitro experiment showed that in renal tubular epithelial cells CD147, together with MMP, induces the production of hyaluronic acid, which participates in the differentiation of the tubular epithelial cells into myofibroblasts in response to TGF- β . Hyaluronan promotes the emergence of proteins typical of fibroblasts on the surface of the transforming cells. [12] Similarly to acute kidney injury, CD147's role in stimulating inflammatory infiltration by macrophages and monocytes in chronic kidney injury has been proven. [13] CD147 is thought to exacerbate fibrosis following three mechanisms: hyaluronan induction, MMP (particularly MMP-2) induction and inflammatory infiltration. Our study showed that the concentration of CD147 correlated negatively with eGFR at the time of sampling – 70 months post Tx on average. The level of CD147 at the end of the follow-up period correlated negatively with eGFR at 1 and 2 years post Tx, as well. These results prove that its high activity is most apparently linked to worse renal graft function since the very beginning – the early post-transplantation period and at 1 and 2 years post Tx. Kemmner et al. came to similar conclusions after they analyzed the presence of CD147 in biopsy specimens collected from renal graft recipients (50 months post Tx on average) in the context of renal graft function and chronic histopathological lesions in the form of IF/TA. They found that abundant CD147 in the biopsy specimen was associated with more pronounced FT/TA lesions, poorer renal graft function evaluated using eGFR values, and an unfavorable change of renal graft function over time. [11] Another researcher, Yoshiko Mori et al., monitored the correlation of urine and plasma CD147 concentrations with renal graft function in patients with different kidney diseases. [14] There is very little information available on EMMPRIN expression in the renal tissue, especially in renal grafts. Most research into this compound is related to cancer and cancer invasion. [15] In many cancers, the effect of EMMPRIN on EMT processes linked to cancer invasion has been proven. [15] EMMPRIN plays a proven role in lung fibrosis secondary to inflammatory diseases. [16] Similarly to Kemmner's results, in our study EMMPRIN correlated positively with IF/TA histopathological lesions. Interstitial fibrosis (CI) demonstrated 4 degrees of lesion severity (0: \leq 5%, 1: 6-25%, 2: 26-50%, 3: $>$ 50%), similarly to tubular atrophy CT (0: no atrophy, 1: \leq 25%, 2: 26-50%, 3: $>$ 50%). The more severe interstitial fibrosis and tubular atrophy, the higher CD147 concentration. Corresponding results were obtained by Shiren Sun et al., who studied the severity of IF/TA lesions in renal biopsy specimens collected from IgA nephropathy patients and found that an increased expression of CD147 was associated with more severe chronic lesions. Additionally, CD147 levels correlated positively with creatinine concentrations and negatively with eGFR. [17] One experimental study on murine models established that mice deprived of the gene coding for CD147 had far less fibrotic lesions in the kidneys at 14 days after bilateral ureteral occlusion. Also, no expression of MMP-2, an element of key importance to EMT, was found in the models. [18] CD147 is a strong stimulator of MMP-2, an enzyme

that in children persists at increased levels since the beginning of renal injury and during its progression correlates with the concentration of TGF- β , the main stimulator of fibrosis. MMP-2 is believed to be an indicator of exacerbated cellular damage, inflammation and elevated proteolytic processes in children with CKD. [19] The positive correlation between EMMPRIN levels and mesangial matrix expansion (MM) lesions in the glomeruli that was found in our study reflected the effect of CD147 on increased ECM amounts in the glomerular spaces between the mesangial cells. This effect may be exerted by a decreased activity of metalloproteinases. Other histopathological lesions that CD147 correlates with, namely double contours of the GBM (CG) and arteriolar hyalinosis (AH), do not lend themselves to easy interpretation. CG may be present in the picture of many pathologies, such as chronic or chronic active humoral rejection, thrombotic microangiopathy, hypertension-related glomerulopathy and glomerulonephritis. According to BANFF classification criteria from 1997, as updated, (AH) is a lesion of „uncertain significance”. [20] The positive correlation between CD147 levels and urine protein concentrations is an important aspect of our results. Proteinuria is a known marker for kidney diseases. Anti-proteinuria treatment improves the prognosis for renal function. Apart from being a marker, however, proteinuria is also a factor contributing to the progression of renal failure. [21.22,23] By exacerbating kidney injury, CD147 increases proteinuria, which has an additional exacerbating effect on the progression of renal allograft failure. Similar results were obtained by Yoshiko et al., who established a positive correlation between urine CD147 levels and urine protein concentrations. [14]

Conclusions

EMMPRIN/CD147 is a glycoprotein that is associated with poorer long-term renal graft function. Its high concentrations are also linked to more pronounced IF/TA lesions and the degree of proteinuria.

Declarations

Ethics approval and consent to participate:

The patients involved in the study were treated in line with the Declaration of Helsinki and the Declaration of Istanbul. All participants gave their written informed consent. The local ethics committee of the Pomeranian Medical University, Szczecin, Poland approved the study protocol – KB-0012/23/18 (05FEB2018).

Availability of data and materials:

The datasets during and/or analysed during the current study available from the corresponding author on reasonable request.

Funding acknowledgment:

This research received no specific grant from any funding agency in the public, commercial, or not-for-profit sectors.

Author Contributions:

"Conceptualization, 1,7; methodology, 1,7.; software, 3,4,6.; validation, 5.; formal analysis, 5,7.; investigation, 1,7.; resources, 1,2,3,7.; data curation, 3,7.; writing—original draft preparation, 1,2,7.; writing—review and editing, 5,6,7.; visualization, 1,6,7.; supervision, 5,6,7.; project administration, 1,7.; All authors have read and agreed to the published version of the manuscript

Competing interests:

"The authors declare that they have no competing interests" in this section.

Acknowledgements:

Not applicable

References

1. Dong Zhou, Youhua Liu. Renal Fibrosis in 2015: Understanding the Mechanisms of Kidney Fibrosis. *Nat Rev Nephrol* 2016 Feb;12(2):68-70
2. Sun YB, Qu X, Caruana G, Li J. The origin of renal fibroblasts/myofibroblasts and the signals that trigger fibrosis. *Differentiation*. 2016 Sep;92(3):102-107
3. Grass DG, Tool BP. How, with whom and when: an overview of CD147-mediated regulatory networks influencing matrix metalloproteinase activity. *Biosci Rep*. 2016; 36(1):e00283.
4. Kato N, Yuzawa Y, Kosugi T et al. The E-selectin ligand basigin/CD147 is responsible for neutrophil recruitment in renal ischemia/reperfusion. *J Am Soc Nephrol*. 2009 Jul;20(7):1565-76.
5. Seizer P, Ochmann C, Schönberger T et al. Disrupting the EMMPRIN (CD147)-cyclophilin A interaction reduces infarct size and preserves systolic function after myocardial ischemia and reperfusion. *Arterioscler Thromb Vasc Biol*. 2011 Jun;31(6):1377-86.
6. Kosugi T, Maeda K, Sato W et al. CD147 (EMMPRIN/Basigin) in kidney diseases: from an inflammation and immune system viewpoint. *Nephrol Dial Transplant*. 2015 Jul;30(7):1097-103.
7. Nagaya H, Kosugi T, Maeda-Hori M et al. CD147/basigin reflects renal dysfunction in patients with acute kidney injury. *Clin Exp Nephrol*. 2014 Oct;18(5):746-54.
8. Mannon RB. Delayed graft function: The AKI of Kidney Transplantation. *Nephron* 2018;140(2)94-98.
9. Cruz-Solbes AS, Youker K. Chapter 13 – Epithelial to Mesenchymal Transition (EMT) and endothelial to Mesenchymal Transition (EndMt): Role and implication in Kidney fibrosis. *Kidney Development and Disease, Results and Problems in Cell Differentiation*. Springer International Publishing AG 2017. DOI 10.1007/978-3-319-51436-9_13
10. Kemmner S, Schulte C, von Weyhern CH et al. EMMPRIN expression is involved in the development of interstitial fibrosis and tubular atrophy in human kidney allografts. *Clin Transplant*. 2016 Mar;30(3):218-25.

11. Arora K, Gwinn WM, Bower MA et al. Extracellular cyclophilins contribute to the regulation of inflammatory responses. *J Immunol*. 2005 Jul 1;175(1):517-22.
12. Lange-Sperandio B, Cachat F, Thornhill BA et al. Selectins Mediate Macrophage Infiltration in Obstructive Nephropathy in Newborn Mice. *Kidney Int*. 2002 Feb;61(2):516-524.
13. Mori Y, Masuda T, Kosug T et al. The Clinical Relevance of Plasma CD147/basigin in Biopsy-Proven Kidney Diseases. *Clin Exp Nephrol*. 2018 Aug;22(4):815-824.
14. Wu J, Ru NY, Zhang Y et al. HAb18G/CD147 Promotes Epithelial-Mesenchymal Transition Through TGF- β Signaling and Is Transcriptionally Regulated by Slug. *Oncogene*. 2011 Oct 27;30(43):4410-27.
15. Guillot S, Delaval P, Brinchault G et al. Increased Extracellular Matrix Metalloproteinase Inducer (EMMPRIN) Expression in Pulmonary Fibrosis. *Exp Lung Res*. Mar-Apr 2006;32(3-4):81-97
16. Sun S, Zhao A, Li R et al. CD147 Renal Expression as a Biomarker for Progressive IgAN. *J Nephrol*. 2015 Jun;28(3):307-14.
17. Qu X, Wang C, Zhang J et al. Roles of CD147 and/or Cyclophilin A in Kidney Diseases. *Mediators of Inflammation* 2014. ID 728673. doi.org/10.1155/2014/728673
18. Zakiyanov O, Kalousova M, Zima T et al. Matrix Metalloproteinases in Renal Diseases: A Critical Appraisal. *Kidney Blood Press Res* 2019;44:298–330.
19. Roufosse C, Simmonds N, Clahsen-van Groningen M et al. A 2018 Reference Guide to the Banff Classification of Renal Allograft Pathology. *Transplantation* 2018;102:1795-1814
20. Webster AC, Nagler EV, Morton RL et al. Chronic Kidney Disease. *Kidney Int* 2004;65:1870–6. *Lancet*. 2017 Mar 25;389(10075):1238-1252
21. Zhong J, Yang H CH, Fogo AB. A perspective on chronic kidney disease progression. *Am J Physiol Renal Physiol*. 2017 Mar 1; 312(3): 375–384.
22. Naesens M, Lerut E, Emonds MP et al. Proteinuria as a Noninvasive Marker for Renal Allograft Histology and Failure: An Observational Cohort Study. *J Am Soc Nephrol*. 2016 Jan;27(1):281-92.

Tables

Table 1.

Clinical characteristics of the study group

	N	ME	MIN	MAX
Time from Tx (months)	49	69	12	182
Recipient age (years)	49	42	24	71
BMI on Tx	49	23.8	16.1	34.8
BMI at last appointment	49	25.4	18.1	34
eGFR at last appointment (mL/min/1.73m ²)	49	36	15	89
Urine protein (mg/dL)	49	0	0	865.7
Time of dialysis prior to Tx (month)	49	15	6	102
CIT (min)	49	1,260	72	2,100
PRA(%)	49	3	0	56
ZENITH eGFR (mL/min/1.73m ²)	49	31.0	98.0	118.0
eGFR at 1 year (mL/min/1.73m ²)	49	45	12	96.0
eGFR at 2 years (mL/min/1.73m ²)	48	49	15	85
eGFR at 3 years (mL/min/1.73m ²)	43	47	17	87
eGFR at 4 years (mL/min/1.73m ²)	38	46	19	98
eGFR at 5 years (mL/min/1.73m ²)	35	41	17	109
eGFR at 10 years	13	44	23	82

(mL/min/1.73m ²)				
EMMPRIN	49	6,623.2	643.36	59,861.6
(pg/mL)				
Sex	49	W21	M28	

Tx-renal transplantation, Time from Tx – time from renal transplantation, BMI on Tx – body mass index at the time of transplantation, eGFR at last recent appointment – estimated glomerular filtration rate (estimated using the by MDRD formula) at the most recent appointment, ZENITH eGFR – the highest estimated glomerular filtration rate within the first 6 months post renal transplantation (estimated using the MDRD formula), time after Tx – time after renal transplantation.

Table 2.

EMMPRIN values in in DGF POSITIVE and DGF NEGATIVE groups.

	DGF POSITIVE		MIN	MAX	DGF NEGATIVE		MIN	MAX	p
	ME				ME				
EMMPRIN (pg/mL)	7,729.9		643.4	29,709.5	5,348.1		897.4	59,861.6	p<0.05

Figures

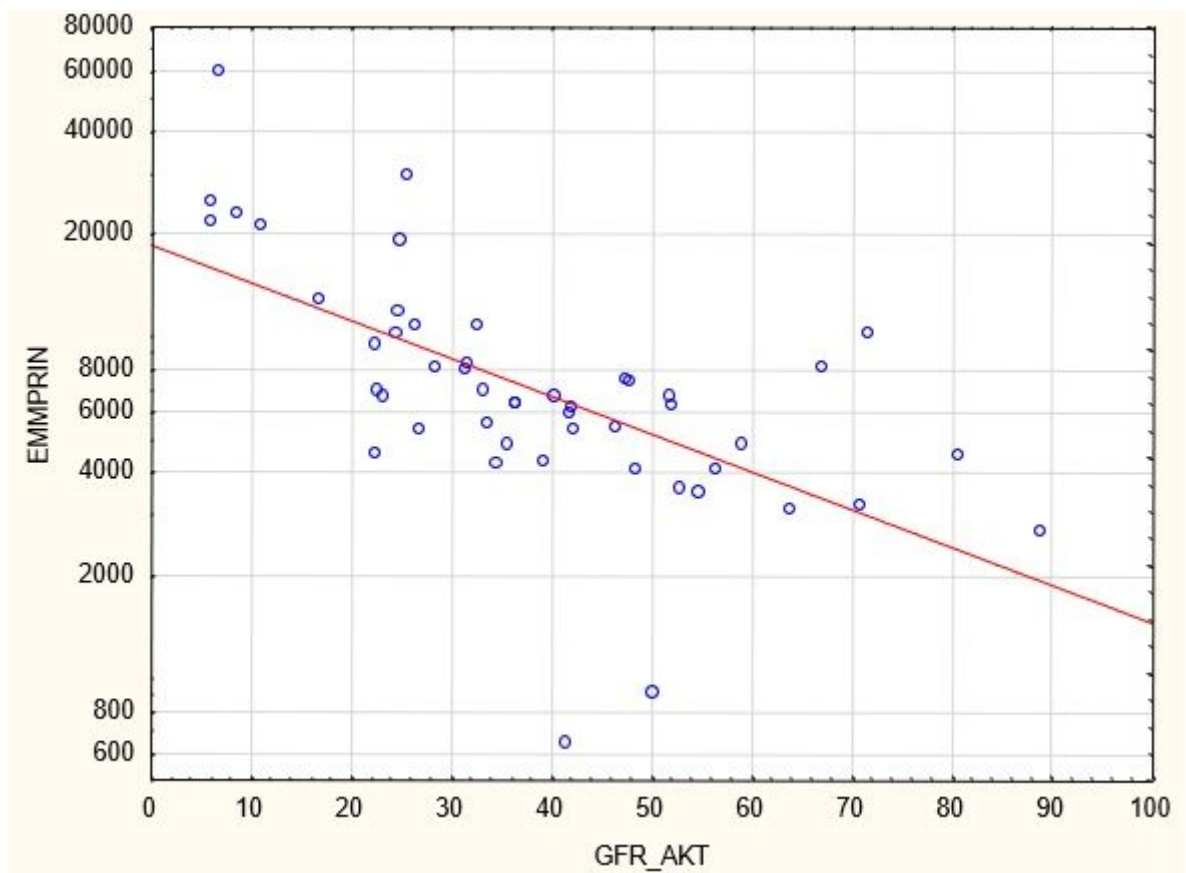


Figure 1

Negative correlation between EMMPRIN/CD147 concentration and eGFR at the most recent appointment (ME 70 months)

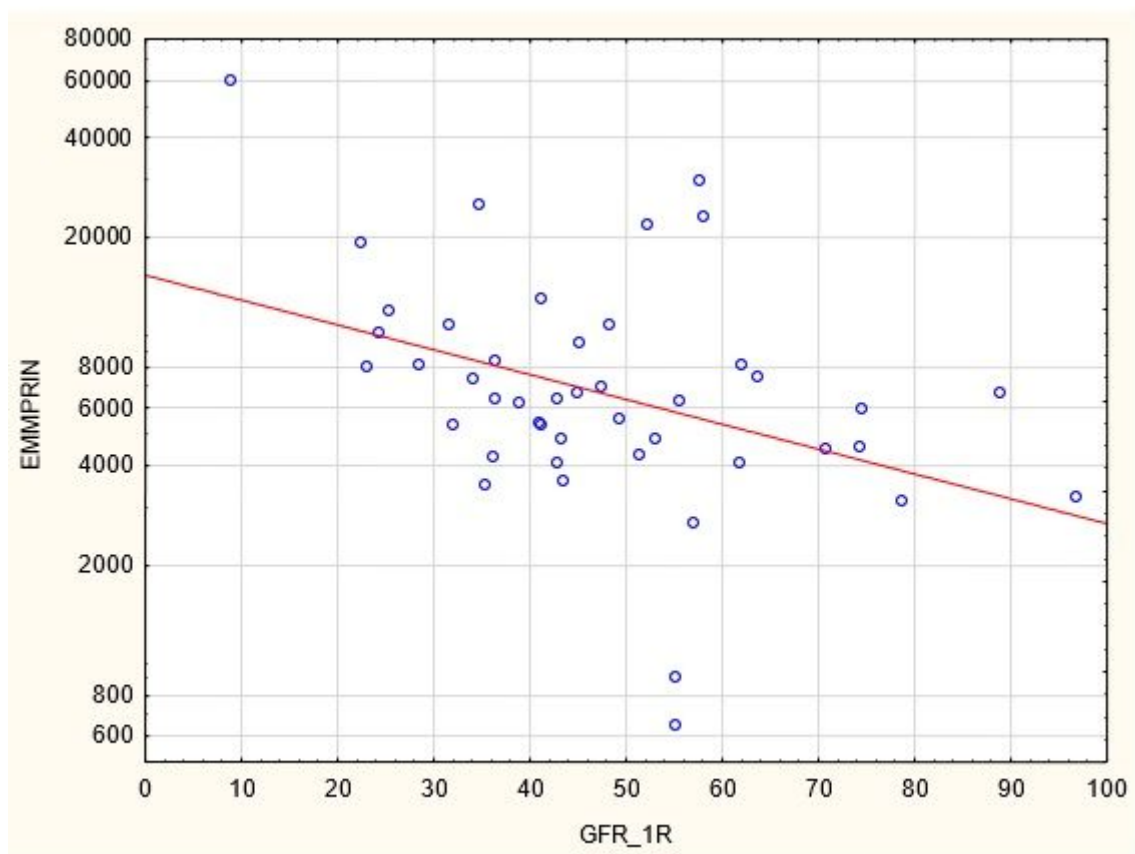


Figure 2

Negative correlation between EMMPRN/CD147 concentration and eGFR at 1 year after renal transplantation

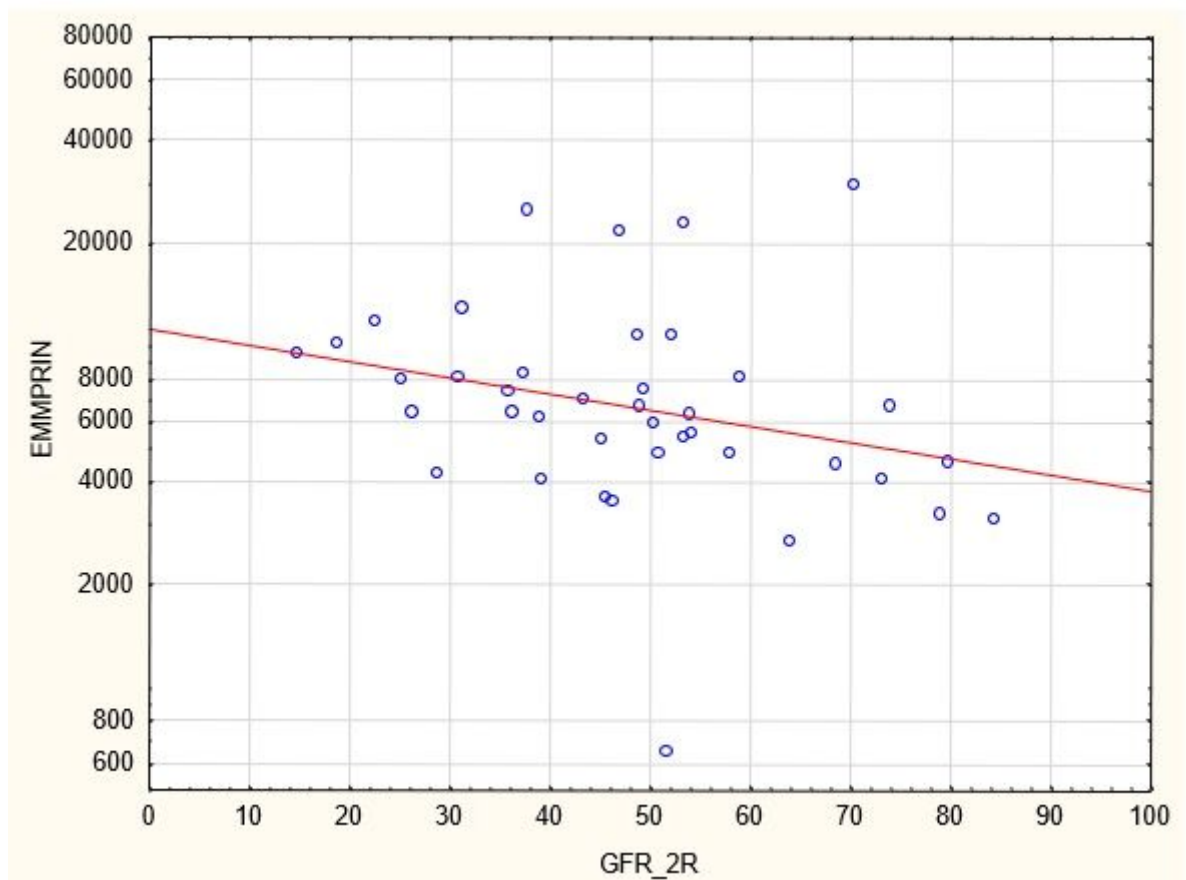


Figure 3

Positive correlation between EMMPRIN/CD147 concentration and severity of biopsy specimen lesions such as CI, CT, CG, MM and AH

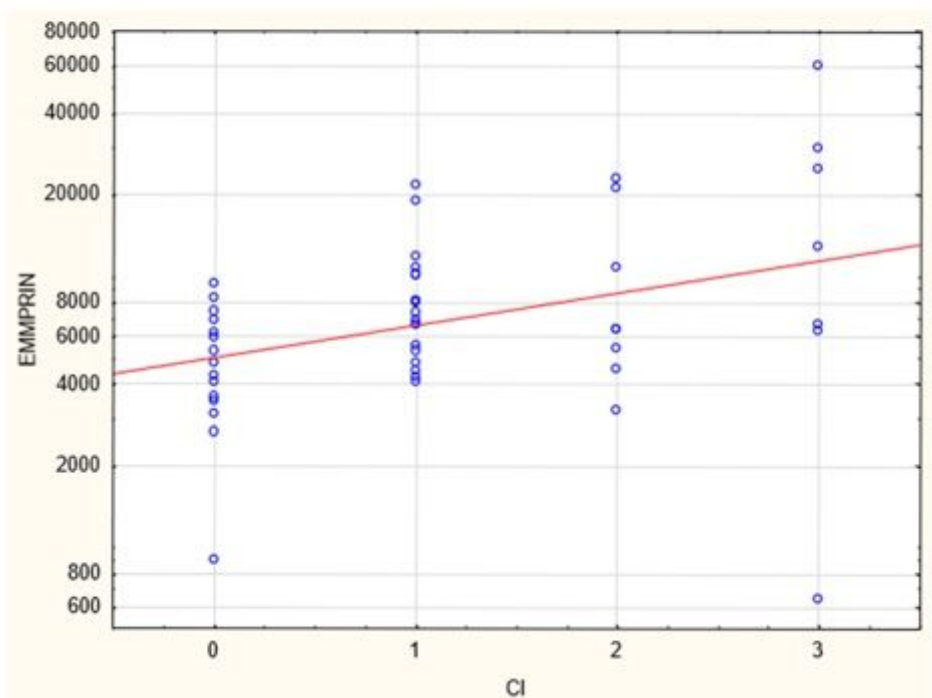
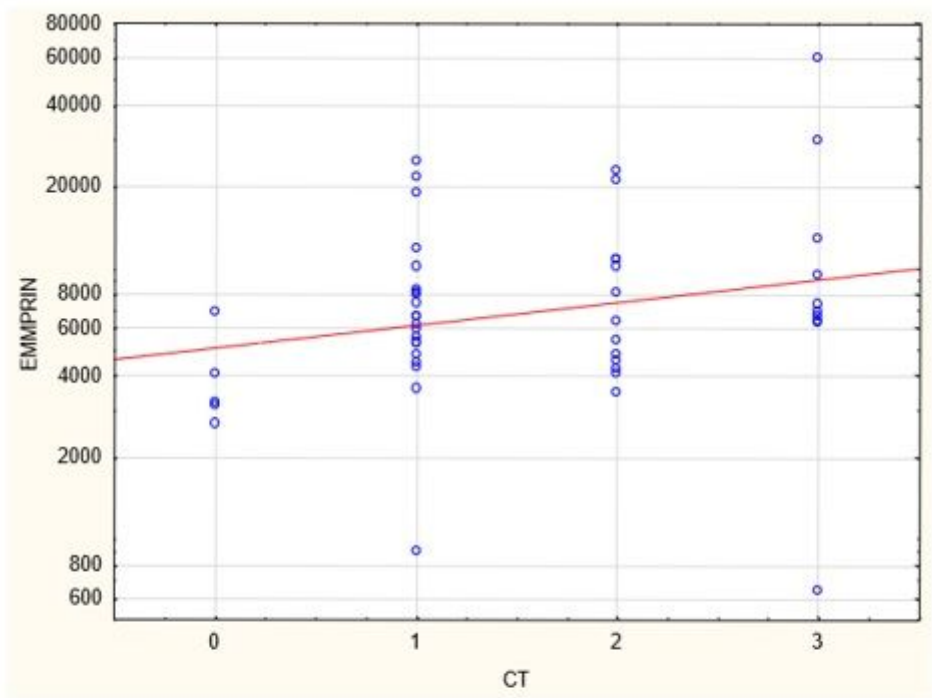


Figure 4

Positive correlation between EMMPRIN/CD147 concentration and severity of biopsy specimen lesions such as CI and CT

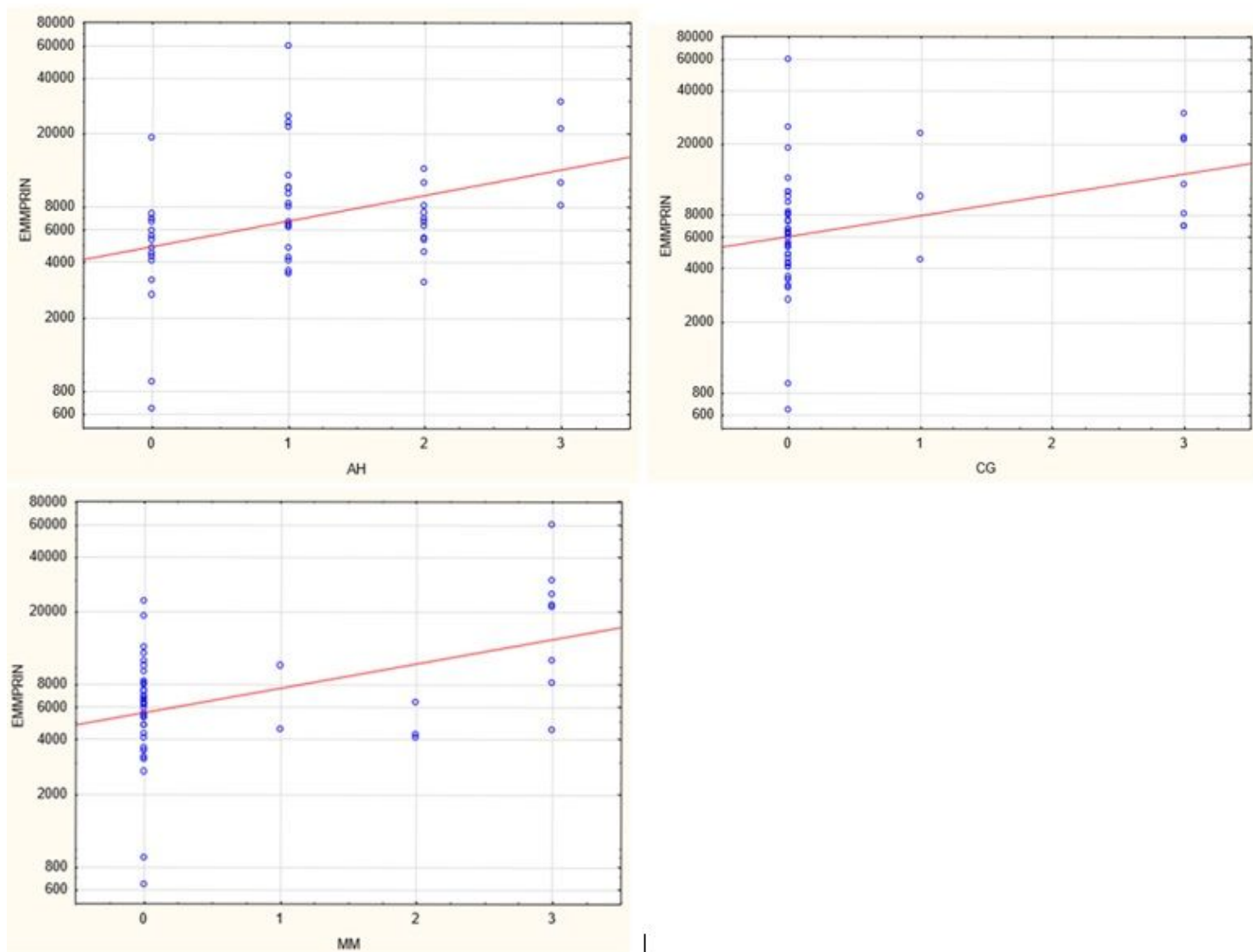


Figure 5

Positive correlation between EMMPRIN/CD147 concentration and severity of biopsy specimen lesions such as CG, MM and AH