

Weekly Trastuzumab Therapy Cannot Prevent Severe Trastuzumab-induced Thrombocytopenia: A Case Report

Xin Wang

Kunming Medical University

Xiaoli Zhu

Kunming Medical University

Jieya Zou

The Third Affiliated Hospital of Kunming Medical University: Yunnan Cancer Hospital

Xia Zhang

Kunming Medical University

Xuemei Wu

Kunming Medical University

Jianyun Nie (✉ kmmutfh@sina.com)

The Third Affiliated Hospital of Kunming Medical University Postal address: 519 Kunzhou Road, Xishan District, Kunming City, Yunnan Province, China <https://orcid.org/0000-0003-4573-2793>

Case report

Keywords: breast cancer, human epidermal growth factor receptor-2, trastuzumab, thrombocytopenia, platelet

Posted Date: November 20th, 2020

DOI: <https://doi.org/10.21203/rs.3.rs-111285/v1>

License: © ⓘ This work is licensed under a Creative Commons Attribution 4.0 International License.

[Read Full License](#)

Abstract

Background: Trastuzumab can significantly prolong the survival of patients with positive human epidermal growth factor receptor-2 breast cancer. Until now, trastuzumab has been used by millions of people, and trastuzumab-induced thrombocytopenia is rare. There is no report of acute grade 4 thrombocytopenia after weekly trastuzumab therapy. We report a breast cancer patient with severe thrombocytopenia due to trastuzumab (8mg/Kg) who experienced a recurrence of severe thrombocytopenia after attempting weekly trastuzumab therapy (4mg/Kg).

Case presentation—A 52-year-old woman with positive human epidermal growth factor receptor-2 breast cancer developed acicular rash with dense skin all over the body and gingival bleeding within 24 hours of trastuzumab infusion (8mg/Kg) and was confirmed to have severe thrombocytopenia, which was quickly recovered after high-dose corticosteroid pulse therapy. When the platelet count recovered, we tried weekly trastuzumab therapy (4mg/kg), Unfortunately, thrombocytopenia recurred within 24 hours. No third trastuzumab treatment was attempted.

Conclusion: We are the first report to try weekly trastuzumab therapy after thrombocytopenia induced by first trastuzumab. The patient showed that reducing the dose of trastuzumab was ineffective in preventing trastuzumab-induced thrombocytopenia.

Background

Breast cancer has become the number one killer-cancer threatening women around the world, of which about 20%-30% of breast cancer patients had overexpression of human epidermal growth factor receptor-2. The results of NCCTG N9831/ NSABP B31 study(1), showed that trastuzumab combined with chemotherapy reduced the risk of recurrence by about 40% and the risk of death by 37% in breast cancer patients with human epidermal growth factor receptor-2 amplification. For trastuzumab monotherapy, the hematological side effects were rare, the incidence of NCI-CTCAE grade 3 thrombocytopenia was less than 1%, and grade 4 thrombocytopenia rarely occurred. So far, there is no report of acute grade 4 thrombocytopenia after weekly trastuzumab therapy. We report a breast cancer patient who developed grade 4 thrombocytopenia after the first load dose of trastuzumab (8mg/Kg) and developed acute grade 4 thrombocytopenia again after first weekly trastuzumab treatment (4mg/Kg).

Case Presentation

A 52-year-old woman was admitted to the Department of Breast surgery in our hospital in October 2018. The biopsy showed invasive ductal carcinoma of the right breast. Immunohistochemical staining showed: negative for estrogen and progesterone receptors but positive for human epidermal growth factor receptor-2 (3+ positivity, the result of Fluorescence in situ hybridization test was positive), KI-67 35%. She completed 8 cycles of chemotherapy with EC-T regimen (epirubicin 140mg, cyclophosphamide 800mg, sequential docetaxel 140mg) and modified radical mastectomy. During chemotherapy, we did not

observe the occurrence grade 3/4 leukopenia, and the platelet count was in the normal range. The patient did not receive any treatment after chemotherapy. Three and a half months later, she was expected to receive radiotherapy. During the period, the platelet count was still in the normal range. On August 1, 2019, after 17 times of radiation exposures, she started the targeted therapy with 8mg/kg loading dose of single trastuzumab (never used heparin). The second day, she developed acicular rash with dense skin all over the body and gingival bleeding (Figure 1). We considered that this may be caused by radiotherapy, so we didn't review the platelet count, just stopped the radiotherapy immediately, therefore, the gingival bleeding and rash persisted. The first blood routine examination was performed on 5th day after trastuzumab treatment, investigation revealed all the indexes were in the normal range, but platelet count of 1000/mm³. After administration of etamsylate high-dose corticosteroid pulse therapy and platelet transfusion, the platelets gradually recovered (Figure 2). During this period, a bone marrow biopsy was obtained. It showed low megakaryocytopoiesis and no sign of infiltration by tumor. Blood film showed platelet count decreased significantly. 7 days after corticosteroid therapy, her platelet count was close to normal and she was discharged. Half a month later, the patient continued to receive radiation exposures, trastuzumab was not administered. During this period, platelet count remained stable in the normal range. So we considered the severe thrombocytopenia caused by trastuzumab instead of radiotherapy.

One and a half months after the end of the radiotherapy, we tried to reduce the dose to prevent trastuzumab-induced thrombocytopenia. Because the interval of trastuzumab exceeded the half-life, so she received 4mg/kg weekly trastuzumab monotherapy (Load-dose). One day after the infusion, her platelet count was 35000/mm³, and after etamsylate intravenous infusion of high-dose methylprednisolone sodium succinate thrombopoietin (TPO) and platelet transfusion therapy, the trend of platelet decline was more stable than before. Two days after the infusion, her platelet count was 16000/mm³. Because of the treatment timely, there was no spontaneous bleeding or rash. Finally, her platelet count recovered to 108000/ mm³ on the 6th day after corticosteroid therapy (Figure 2). Because the patient still had grade 4 thrombocytopenia with low-dose trastuzumab, therefore, she was not treated with trastuzumab again.

Discussion

The mechanism of severe thrombocytopenia induced by trastuzumab is still unclear. Take trastuzumab emtansine (T-DM1) for example which is a conjugate of trastuzumab and the cytotoxic agent DM1, and its most common side effect is thrombocytopenia. However, Current studies(2, 3) suggest that the endocytosis of DM1 by megakaryocytes affects the differentiation of megakaryocytes and causes thrombocytopenia, rather than trastuzumab. Until now, there are mainly three reasons of drug-induced thrombocytopenia(4, 5): classic drug-induced immune-mediated thrombocytopenia heparin induced thrombocytopenia (HIT) and induction of specific anti-idiotypic antibodies (glycoprotein IIb/ IIIa inhibitors). In our case, radiotherapy alone did not cause thrombocytopenia, therefore, it was certain that the thrombocytopenia was directly attributed to trastuzumab. Her platelet count recovered quickly after high-dose corticosteroid pulse therapy and decreased again after low-dose trastuzumab infusion. The

above phenomena suggested that trastuzumab-induced thrombocytopenia might be classic drug-induced immune-mediated thrombocytopenia.

In the clinic, when a drug causes side effects, we often reduce the dose of the drug to reduce/prevent these side effects. However, there is no reported case to try low-dose trastuzumab treatment after first trastuzumab-induced thrombocytopenia. When the patient's platelet returned to normal and drug elution, we tried weekly trastuzumab therapy (4mg/kg). Unfortunately, thrombocytopenia recurred within 24 hours, moreover, high-dose corticosteroid pulse therapy, thrombopoietin (TPO) and platelet transfusion therapy were effective in treating thrombocytopenia, and the platelet recovery curve was similar to the first trastuzumab treatment (Figure 2). These phenomena reminded us: 1) Weekly trastuzumab therapy was still not suitable for patients with trastuzumab-induced thrombocytopenia. The process of thrombocytopenia was rapid and dangerous, and our attempt showed that trastuzumab-induced immune-mediated thrombocytopenia was independent of dose or concentration, therefore, reducing trastuzumab dose could not prevent trastuzumab-induced thrombocytopenia; 2) Trastuzumab-induced thrombocytopenia could be treated with high-dose corticosteroid pulse therapy, thrombopoietin (TPO) and platelet transfusion, meantime, the treatment cycle was approximately 6 to 7 days, which was consistent with some reported cases(6-8). Immunoglobulin has also been shown to have a good effect in some reported cases(6, 7, 9-11). Mantzourani et al. ⁽⁹⁾ believed that the trastuzumab-induced thrombocytopenia might be a self-limited disease, but this view did not apply to our patient. When no treatment was given, the decrease of her platelet count did not stop, and dropped to 1000/mm³ on the 5th day after trastuzumab treatment. It suggested that trastuzumab-induced thrombocytopenia might not be a self-limited disease and must be treated quickly, otherwise it might increase the risk of spontaneous bleeding and death.

Conclusion

Trastuzumab is the basis of the treatment of positive human epidermal growth factor receptor-2 breast cancer. Therefore, despite the grade 4 thrombocytopenia that occurred after the first trastuzumab treatment, weekly trastuzumab therapy was still attempted, and none of the previously reported cases had tried the treatment. Our case showed that reducing the dose of trastuzumab was ineffective in preventing trastuzumab-induced thrombocytopenia. As for positive human epidermal growth factor receptor-2 patients with trastuzumab-induced thrombocytopenia, we can try tyrosine kinase inhibitors (TKI) to continue anti-HER-2 targeted therapy such as lapatinib(12).

Declarations

Ethics approval and consent to participate: Not applicable.

Consent for publication: The patient agrees to issue and sign the informed consent.

Availability of data and materials: The datasets used or analyzed during the current study are available from the corresponding author on reasonable request.

Competing interests: The authors do not have any possible conflicts of interest.

Funding: The paper was funded by the National Natural Science Foundation of China. ID: 81960479.

Author contributions: Professor Nie Jianyun contributed to the conception of the case report and patient's data; Docter Wang Xin wrote the manuscript and made chart; Zou Jieya **contributed to manuscript preparation**; Zhu Xiaoli□Zhang Xia□Wu Xuemei participated in the review and editing of the paper.

Acknowledgements: The case report would not have been possible without the consistent and valuable reference materials that I received from docter Li Zhen, whose insightful guidance and enthusiastic encouragement in the course of my shaping this thesis definitely gain my deepest gratitude.

References

1. Perez EA, Romond EH, Suman VJ, et al. Trastuzumab plus adjuvant chemotherapy for human epidermal growth factor receptor 2-positive breast cancer: planned joint analysis of overall survival from NSABP B-31 and NCCTG N9831[J]. *J Clin Oncol*. 2014;32(33):3744-52.
2. Uppal H, Doudement E, Mahapatra K, et al. Potential mechanisms for thrombocytopenia development with trastuzumab emtansine (T-DM1)[J]. *Clin Cancer Res*. 2015;21(1):123-33.
3. Zhao H, Gulesserian S, Ganesan SK, et al. Inhibition of Megakaryocyte Differentiation by Antibody-Drug Conjugates (ADCs) is Mediated by Macropinocytosis: Implications for ADC-induced Thrombocytopenia[J]. *Mol Cancer Ther*. 2017;16(9):1877-86.
4. Aster RH, Bougie DW. Drug-induced immune thrombocytopenia[J]. *The New England journal of medicine*. 2007;357(6):580-7.
5. Warkentin TE. Drug-induced immune-mediated thrombocytopenia—from purpura to thrombosis[J]. *The New England journal of medicine*. 2007;356(9):891-3.
6. Cathomas R, Goldhirsch A, von Moos R. Drug-induced immune thrombocytopenia[J]. *The New England journal of medicine*. 2007;357(18):1870-1; author reply 1.
7. Pino MS, Angiolini C, Fioretto L. Severe thrombocytopenia after trastuzumab retreatment: a case report[J]. *BMC research notes*. 2013;6:400.
8. Luo Q, Guo Z, Ye C. Thrombocytopenia Induced by Herceptin[J]. *The American surgeon*. 2019;85(4):e222-e4.
9. Mantzourani M, Gogas H, Katsandris A, et al. Severe thrombocytopenia related to trastuzumab infusion[J]. *Medical science monitor : international medical journal of experimental and clinical research*. 2011;17(7):Cs85-7.
10. Jara Sanchez C, Olier Garate C, Garcia-Donas Jimenez J, et al. Drug-induced thrombocytopenia induced by trastuzumab: a special challenge in a curable disease[J]. *Ann Oncol*. 2009;20(9):1607-8.
11. Parikh O, Neave F, Palmieri C. Severe thrombocytopenia induced by a single infusion of trastuzumab[J]. *Clin Breast Cancer*. 2008;8(3):285-6.
12. Cathomas R, von Moos R. Severe drug-induced thrombocytopenia after treatment with trastuzumab but not with lapatinib[J]. *Ann Oncol*. 2009;20(9):1606-7.

Figures

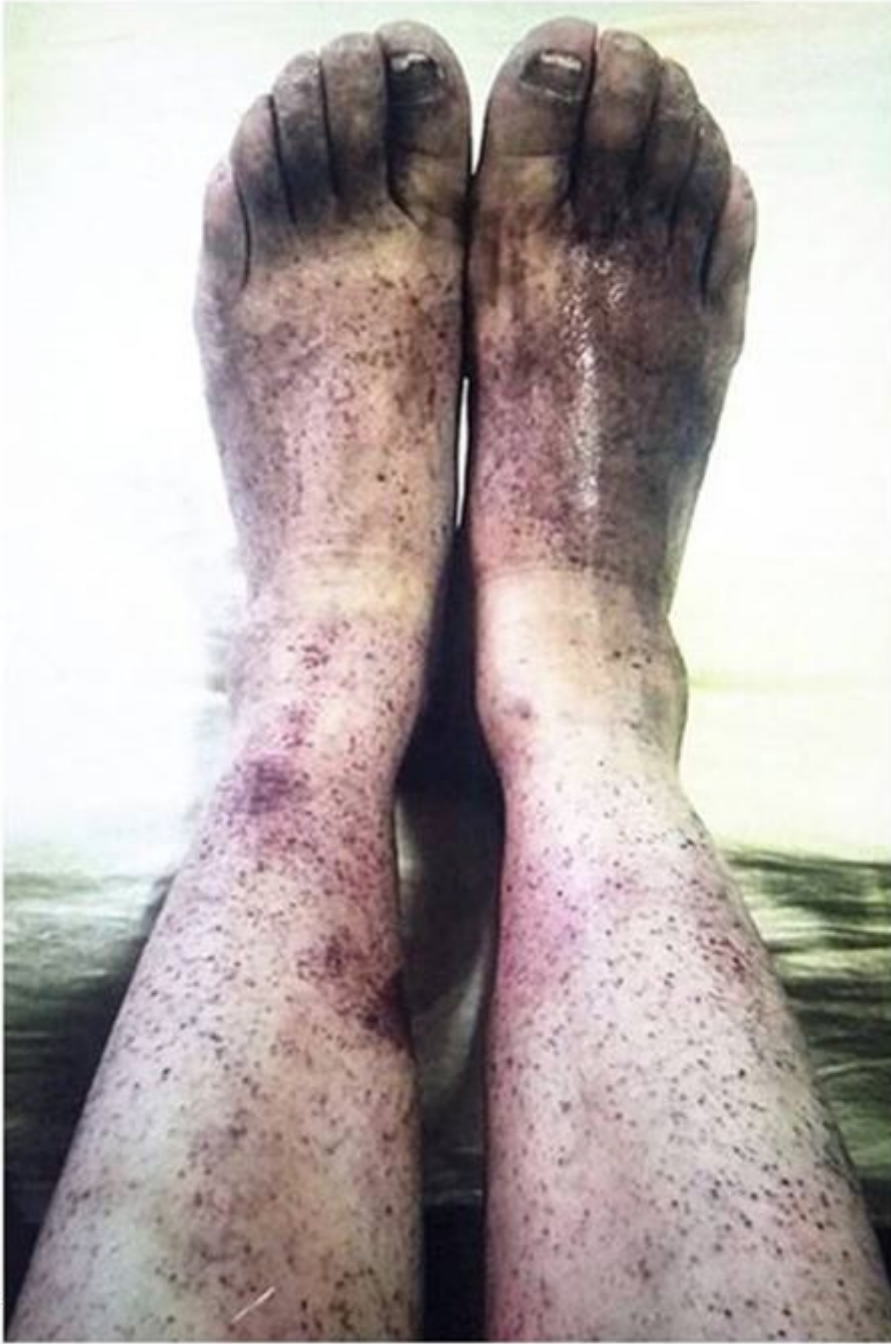

Figure 1

Within 24 hours after trastuzumab infusion, acicular rash with dense skin was observed.

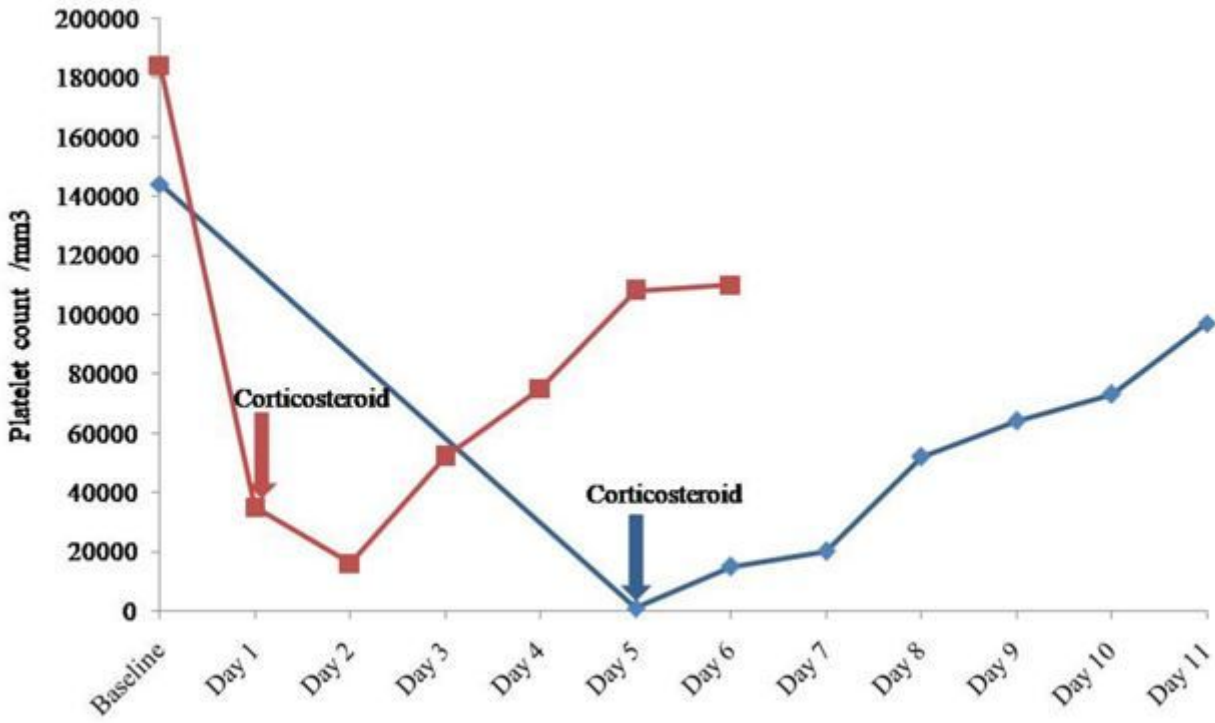


Figure 2

Platelet count before and after corticosteroid treatment 8 mg/ kg Trastuzumab 4 mg/ kg Trastuzumab