

Intra- and Inter-observer Reliability of Implant Positioning Evaluation on a CT-based Three-dimensional Postoperative Matching System for Total Knee Arthroplasty.

Shotaro Watanabe

Chiba University <https://orcid.org/0000-0002-1146-1991>

Ryuichiro Akagi (✉ rakagi@chiba-u.jp)

Chiba University <https://orcid.org/0000-0002-7057-0936>

Yuki Shiko

Chiba University

Yoshimasa Ono

Chiba University

Yohei Kawasaki

Chiba University

Toshihiro Ohdera

Fukuoka Orthopaedic Hospital

Seiji Ohtori

Chiba University

Takahisa Sasho

Chiba University

Research article

Keywords: Total knee arthroplasty, Implant position, Postoperative evaluation, 3D-CT image matching, Intra-observer reliability, Inter-observer reliability

Posted Date: November 19th, 2020

DOI: <https://doi.org/10.21203/rs.3.rs-108526/v1>

License:   This work is licensed under a Creative Commons Attribution 4.0 International License.

[Read Full License](#)

Version of Record: A version of this preprint was published at BMC Musculoskeletal Disorders on April 17th, 2021. See the published version at <https://doi.org/10.1186/s12891-021-04228-2>.

Abstract

Introduction: The evaluation of postoperative total knee arthroplasty (TKA) alignment mainly relies on measurement data obtained from plain radiographs. The aim of this retrospective observational study was to document the intra- and inter-observer reliability in assessment of TKA component positioning after surgery using a three-dimensional (3D) computed tomography (CT) image matching system.

Materials and Methods: Fourteen knees from 14 patients who received primary TKA were included, and images were analyzed by blinded readers not associated with the surgeries. The examiner digitized the reference points according to defined landmarks, and the designated size component was superimposed to the 3D reconstructed CT model for measurement. In addition to the evaluation of implant position against the coronal and sagittal lower limb mechanical axes that were defined based on bony landmarks, implant position against axes connecting implant-based reference points that are easier to indicate was evaluated.

Results: The overall intra- and inter-observer reliabilities determined by the intraclass correlation coefficients (ICC) of the implant alignment measurement for both femoral and tibial components were good for both mechanical and implant-based axes. The difference between implant alignment measurements according to the traditional mechanical axis and the implant-based axis ranged between means of 0.08° and 1.70° and were statistically significantly different.

Conclusions: The postoperative evaluation of implant position in the coronal and sagittal planes using 3D-CT image matching is reliable and has good reproducibility. The measured implant position according to the traditional mechanical axis and the implant-based axis were slightly but significantly different.

Introduction

Malposition of the prosthesis can negatively affect the clinical outcomes and extended survivorship after total knee arthroplasty (TKA)[1, 2]. The majority of the cases can achieve successful results in accurately positioning the prosthesis by traditional surgical techniques using intra- and extra-medullary guides. However, some do not necessarily result in enough accuracy, with errors occurring for multiple reasons such as the patients' anatomical variation, the surgical procedure, or the surgeon's determination of anatomical landmarks[3–5]. As many as 20–30% of patients may deviate from preoperative planning by more than three degrees of error [6–8]. Many ancillary techniques and devices have been proposed to align the prosthesis accurately and reduce outliers. Among them, computer-assisted intraoperative navigation has gained more attention during the last decade, with many authors describing significant improvement in implant positioning[7, 8]. The accuracy and effectiveness of portable accelerometer-based guidance systems that allow the surgeon to validate resection in real-time during surgery also have been evaluated previously with encouraging results[8, 9]. The limitation of these previous reports is that the evaluation of postoperative alignment mainly relies on measurement data obtained from plain

radiographs [1, 9, 10], and the correlation of outcomes to postoperative alignment may be affected by the type of radiographs used to measure alignment [1].

Recent studies report greater accuracy by using three-dimensional (3D) computed tomography (CT)-based imaging techniques compared to conventional radiography-based methods for preoperative planning of TKA[11]. Some of these 3D-CT techniques can be applied to postoperative CT images as well to evaluate implant alignment after surgery. However, since this evaluation method measures the implant position by superimposing the computer-aided-design (CAD) model onto the implanted prosthesis on the postoperative CT, there is a potential concern of measurement error due to difficulties of matching the CAD model on CT images. There is currently limited information on the intra- and inter-observer reliability of 3D-CT based systems in evaluating postoperative TKA positioning, but reliability estimates are essential to assess the clinical relevance of studies using the evaluation method.

Traditionally, the mechanical axis of the lower limb has been defined as the axis connecting the center of the hip and the center of knee joint for the femur, and the center of the knee and ankle joints for the tibia[12]. However, as some of the reference points are difficult to identify on CT scans obtained after TKA, we measured another axis that uses the center of the femoral and tibial component as a reference point to define the axes, in addition to the mechanical axis. These two axes, the traditional mechanical axis and the implant-based axis, are similar but not equal. The postoperative measurement and evaluation of implant alignment accuracy may be slightly different between these two axes.

In this observational study, we aimed to (1) document the intra-observer and inter-observer reliabilities in evaluating TKA component positioning after surgery by the 3D-CT evaluation system, and (2) analyze the difference between implant position against the traditional mechanical axis and the implant-based axis. Our hypotheses were that the postoperative evaluation using 3D-CT image matching is reliable with good reproducibility and that there would be a substantial difference in the measured postoperative implant alignment between the traditional mechanical axis and the implant-based axis.

Materials And Methods

This study was conducted by evaluating a series of anonymized images collected after TKA in a multicenter prospective study. The research protocol for the study was approved by the institutional review board, and written informed consent was obtained from each patient at the time of inclusion in the study. The study was conducted following the guidelines for reporting reliability and agreement studies[13].

Patients and surgical technique

Patients who received primary TKA between August 2017 and September 2019 and participated in the multicenter study were included in this study. Images of the first sequential 14 knees from 14 patients were analyzed by blinded readers not associated with the surgeries. Patient demographic data, including sex and age, were not provided to the readers since they were considered unnecessary for this study. The

Persona™ Knee (Zimmer Biomet, Warsaw, Indiana, USA) was used in all cases with cement fixation. The surgeons decided whether to use posterior-stabilized (PS) or cruciate-retaining (CR) types of component, according to their preferences.

Image acquisition

All patients underwent a CT scan six months after surgery. Images were acquired sequentially from the hip joint to the ankle joint, with a slice thickness of 1.25 millimeters. Images were exported as anonymized digital imaging and communications in medicine (DICOM) data format and sent to the independent evaluation organization.

Image reconstruction and measurement

Image data were imported into a CT-based 3D preoperative planning and postoperative evaluation system (ZedView™, LEXI Co., Ltd., Tokyo Japan) for reconstruction and evaluation. Three orthopaedic surgeons with more than six years of experience in knee arthroplasty and reading of musculoskeletal images independently evaluated the images, blinded to each other's measurements. All examiners were blinded to the surgical technique, but information on the implant size and type of prosthesis (PS or CR) was provided. Multiplanar reconstruction images in the sagittal and coronal planes were automatically created from the axial plane CT images. The examiner digitized the reference points according to defined landmarks[11] (Table 1), and a 3D reconstruction model was created. The tip of the medial epicondyle was chosen for the reference point at the distal femur since the groove of the medial epicondyle was challenging to define on the CT images in some cases. After the halation of the implant was minimized using the software, the CAD model of the designated size component was superimposed onto the CT scan image by matching the outer rim, peg of the femoral component, and stem on the tibial component.

Table 1

Bony landmarks as reference points for 3D-CT digitizing to define the traditional mechanical axis.

Reference point	Description
Center of the femoral head	Four points were set on the surface of the femoral head (three in the sagittal or coronal plane, and another point in the axial plane). A ball that contacts all four points was automatically created to approximate the femoral head. The center of the ball was defined as the center of the femoral head.
Medial/lateral epicondyle of the femur	The tip of the medial/lateral epicondyle was marked on the axial plane, by referring to the coronal plane at the same time.
Proximal/distal center of the tibia	Three points were set in the axial plane inside the medullary canal of the tibia at the proximal/distal one-third of the tibia. The center of the circle that contacted all three points was defined as the center of the proximal/distal tibia.

Measurements were performed on two different reference axes. In addition to the evaluation of implant position against the traditional lower limb mechanical axis[14] in the coronal and sagittal planes, implant

position against the implant-based axis was evaluated. Traditional lower limb mechanical alignment was defined as the axis connecting the center of the femoral head and the center between the medial and lateral epicondyles of the femur (Fig. 1a), and the axis connecting the center of the upper and lower one-third of the medullary canal of the tibia (Fig. 1b). As mentioned above, the tip of the medial epicondyle was registered at the distal femur. We did not intend to assess the rotational alignment in this study, and the difference between the center of the anatomical and the surgical trans-epicondylar axis was considered to be negligible in defining the coronal and sagittal femoral axis.

The implant-based femoral axis was defined as the axis connecting the center of the femoral head and the center of the femoral component at the base of the anterior chamfer (Fig. 2a). The implant-based tibial axis was defined as the axis connecting the center of the tibial tray and the center of the ankle joint. To define the center of the tibial tray, the center of the transverse diameter of the tibial tray was marked as the center of the anterior end of the dovetail. Next, in the sagittal plane that passes through the center of the transverse point, the center of the anteroposterior diameter of the tibial tray was defined as the center of the tibial tray (Fig. 2b). The center of the ankle joint was defined as the center of the line connecting the center of the articular surface of the medial malleolus and lateral malleolus at the level of the tibial plafond. This point corresponded to the center of the line connecting the medial and lateral peaks of the talar dome.

The sagittal and coronal inclination of both femoral and tibial components were measured according to each axis. The angles were recorded in positive values when the coronal plane inclination was in varus. In the sagittal plane, the values were recorded positive when the femoral component was in a flexed position, or the tibial component had a posterior slope. Each examiner independently performed the measurement twice for all images, with at least four weeks between measurements. The whole process, including the digitizing of the reference point, was repeated from the beginning of the second measurement.

Sample size and statistical analysis

The intraclass correlation coefficient (ICC) for inter-observer reliability in assessment of the femoral valgus angle on a 3D-CT system has been reported to be 0.807[11]. Therefore, we calculated the sample size according to the expected ICC (inter-observer reliability) = 0.80 with a 95% confidence interval of 0.4 rated by three examiners. Based on these assumptions, the required sample size was 14 in this study[15].

The ICCs with a 95% confidence interval (95% CI) were calculated for intra- and inter-observer reliability in assessment of TKA component alignment after surgery using the 3D-CT system. An ICC value of 1 was considered perfect, > 0.80 very good, > 0.60 good, and > 0.40 moderate reliability [16]. Implant alignment measurements were compared using paired t-tests between two groups (the traditional mechanical axis and the implant-based axis). A two-sided test result of $p < 0.05$ was considered statistically significant. All results were analyzed using SAS version 9.4 for Windows (SAS Institute, Cary, NC, USA).

Results

Intra-observer reliability

The ICCs representing intra-observer reliabilities for measurement of the position of the components on 3D-CT images are presented in Table 2. The overall ICC of the implant alignment measurement for both femoral and tibial components was very good for both the traditional mechanical axis and the implant-based axis.

Table 2
The ICCs for intra-observer reliability

Index	Component	Alignment	Rater	ICC	95%CI
Traditional mechanical axis	Femoral	Varus - Valgus	1	0.92	0.78–0.97
			2	0.98	0.94–0.99
			3	0.87	0.66–0.95
		Flexion - Extension	1	0.49	0.00–0.79
			2	0.80	0.51–0.93
			3	0.80	0.51–0.93
	Tibial	Varus - Valgus	1	0.78	0.47–0.92
			2	0.88	0.69–0.96
			3	0.93	0.81–0.98
		Anterior - Posterior Slope	1	0.91	0.76–0.97
			2	0.94	0.83–0.98
			3	0.91	0.76–0.97
Implant-based axis	Femoral	Varus - Valgus	1	0.93	0.81–0.98
			2	0.97	0.92–0.99
			3	0.85	0.62–0.95
		Flexion - Extension	1	0.50	0.02–0.79
			2	0.72	0.36–0.89
			3	0.75	0.41–0.91
	Tibial	Varus - Valgus	1	0.86	0.64–0.95
			2	0.86	0.64–0.95
			3	0.94	0.83–0.98
		Anterior - Posterior Slope	1	0.93	0.81–0.98
			2	0.95	0.86–0.98
			3	0.89	0.71–0.96
CI, confidence interval.					

Inter-observer reliability

The ICCs representing inter-observer reliability for measurement of the position of the components on 3D-CT images are presented in Table 3. The overall ICC of the implant alignment measurement for both femoral and tibial components was very good for both the traditional mechanical axis and the implant-based axis.

Table 3
The ICCs for inter-observer reliability

Index	Component	Alignment	ICC	95%CI
Traditional mechanical axis	Femoral	Varus – Valgus	0.97	0.94–0.99
		Flexion - Extension	0.89	0.78–0.95
	Tibial	Varus - Valgus	0.90	0.80–0.95
		Anterior - Posterior Slope	0.94	0.88–0.97
Implant-based axis	Femoral	Varus - Valgus	0.96	0.92–0.98
		Flexion - Extension	0.82	0.65–0.91
	Tibial	Varus - Valgus	0.74	0.52–0.87
		Anterior - Posterior Slope	0.96	0.92–0.98
CI, confidence interval.				

Comparison of implant positioning measurements for the traditional mechanical axis and the implant-based axis

The results of implant alignment measurements according to the traditional mechanical axis and implant-based axis are presented in Table 4. The gap between the two values varied from 0.08° to 1.70° on average, and all measurements reached statistical difference. A larger difference in measured alignment was observed in the sagittal plane compared to the coronal plane for the femoral component positioning, while the difference was larger in the coronal plane than the sagittal plane for the tibial component position.

Table 4

Differences of components' alignment between measurements using the traditional mechanical axis or the implant-based axis

Component	Plane	Traditional mechanical axis (degrees)	Implant-based axis (degrees)	Difference		p value
				Mean	Range	
Femoral	Coronal*	-0.28	-0.19	0.08	-0.55, 0.27	< 0.001
	Sagittal†	1.42	3.11	1.70	-2.44, -0.36	< 0.001
Tibial	Coronal*	1.03	1.60	0.56	-2.11, 1.04	< 0.001
	Sagittal‡	3.18	3.38	0.19	-1.64, 1.22,	0.0055
*Positive values for varus alignment. †Positive values for flexion alignment. ‡Positive values for posterior slope.						

Discussion

Our results confirmed the good reproducibility of the 3D-CT based postoperative evaluation system in measuring TKA component positioning. We were able to demonstrate a small but significant difference between measurements based on the traditional mechanical axis and those based on the implant-based axis.

Appropriate limb alignment after TKA has been discussed for many years. The optimal position to obtain satisfactory outcomes both in the short and long term is still debated[8, 17]. Nevertheless, regardless of the underlying theory, surgeons try to position the implant in the manner they believe is "optimal" as the accuracy of implant positioning is essential to obtain positive surgical outcomes. Evaluation methods applied in previous studies to assess TKA positioning after surgery typically include plain anteroposterior and lateral radiographs or two-dimensional CT images[12, 17–19]. Many studies do not report the accuracy of the evaluation technique itself [20], yet the accuracy and reproducibility of the measuring technique are critical factors that may bias the results. 3D-CT-based imaging techniques can be expected to provide better accuracy in the evaluation. Franceschi et al. evaluated the reproduction of 3D-CT preoperative planning by comparing it to the postoperative CT image by superimposing pre- and postoperative CT scans and reported good reproducibility[21]. However, no validation of the intra- and inter-observer reliability of the postoperative evaluation method was reported.

A limited number of studies report the use of 3D-CT analysis for component position measurements after TKA[22, 23]. These reports used the method reported by Hirschmann et al.,[24] which has a high inter- and intra-observer reliability for component position evaluation[25, 26]. However, the method to determine the component position was not described in detail. The accuracy and reproducibility of evaluation could be influenced not only by the imaging methods[17], but also by how the reference points and the axis were

determined by the raters. Validation is required for each technique. In the present study, we validated the intra- and inter-observer reliability in evaluating TKA component positioning after surgery by a 3D-CT evaluation system. The system we used in this study is one of the most common validated methods used to perform preoperative planning[11], and also can be used for postoperative evaluation. Our results demonstrate the good reproducibility of the system, both for intra- and inter-observer reliability, confirming its usefulness in postoperative assessment.

The position of the implant is mainly determined by how the bone is resected during surgery. Conventional intra- and extra-medullary guides determine the resection plane by setting the cutting block to a preoperatively planned angle against the rod, which is either inserted in the medullary canal or aligned outside the canal according to anatomical landmarks. Therefore, the precision of the surgery reflected by the postoperative alignment of TKA components, ideally should be evaluated by measuring the angle against the mechanical axis. However, it is sometimes difficult to evaluate the traditional mechanical axis due to difficulty in identifying the anatomical landmarks on the postoperative CT. By minimizing the halation of the implant itself, the sharp edges of the component provide easier reference points to digitize and possibly provide a more accurate measurement. Our results show that both measurement methods, referring to the traditional mechanical axis or the implant-based axis, provide reliable and reproducible evaluation. Thus, the implant-based axis may be utilized in situations in which the anatomical landmarks of the traditional mechanical axis are difficult to identify. Still, the slight difference between the two axes should be considered in interpretation of the results.

This study has several limitations. First, the results we obtained cannot be generalized to all 3D-CT based systems as we did not compare the results from different platforms. However, it was not possible to test all systems. The system used in this study is a commonly used system in this region and the measurements were proved to be reliable and reproducible based on standard anatomical reference points. Thus, we believe that these results could be applied to other similar systems. Second, we did not assess the rotational alignment of the implanted components. The ability to evaluate the rotational alignment is a major advantage of 3D-CT imaging systems against two-dimensional imaging modalities. However, the primary purpose of this study was to analyze the accuracy of implant positioning in the coronal and sagittal planes. Furthermore, unlike the implant position in the coronal and sagittal planes, there is currently no standard reference axis to evaluate the rotational alignment of both femoral and tibial components after TKA[27].

Conclusions

The postoperative evaluation of implant position in the coronal and sagittal planes using 3D-CT image matching is reliable with good reproducibility. There was a small but significant difference between the measured implant position according to the traditional mechanical axis and the implant-based axis, with the sagittal alignment of the femoral component having the largest difference.

Abbreviations

total knee arthroplasty, TKA

three-dimensional, 3D

computed tomography, CT

computer-aided-design, CAD

posterior-stabilized, PS

cruciate-retaining, CR

digital imaging and communications in medicine, DICOM

intraclass correlation coefficient, ICC

confidence interval, CI

Declarations

- **Ethical approval / Consent to participate**

The research protocol for the study was approved by the institutional review board, and written informed consent was obtained from each patient at the time of inclusion in the study.

- **Availability of data and materials**

The datasets used and/or analysed during the current study are available from the corresponding author on reasonable request.

- **Conflict of interest**

Ryuichiro Akagi and Toshihiro Odera financially supported by Zimmer Biomet Inc. (Warsaw).

- **Funding**

The study was financially supported by Zimmer Biomet Inc. (Warsaw).

- **Author's contributions**

All authors contributed to the study conception and design. Material preparation, data collection and analysis were performed by Shotaro Watanabe, Ryuichiro Akagi, and Yoshimasa Ono. Yuki Shiko and Yohei Kawasaki carried out statistical analysis of data and drafted the manuscript. Toshihiro Ohdera mainly performed the surgery and provided the data for the analysis. The first draft of the manuscript was written by Shotaro Watanabe and all authors commented on previous versions of the manuscript.

Seiji Ohtori and Takahisa Sasho mentioned constructive comments for the manuscript and revised the manuscript. All authors read and approved the final manuscript.

- **Acknowledgements**

The authors thank Takaaki Shibuya, Nobukazu Okamoto, Eiichi Shiigi, Nobuyuki Shirakawa, Kunihiro Hosaka, Masahiro Matsuda, Kosuke Tsuda, and Fuyuki Tominaga for performing the surgery and providing their CT data.

References

1. Lee BS, Cho HI, Bin S II, Kim JM, Jo BK. Femoral Component Varus Malposition is Associated with Tibial Aseptic Loosening after TKA. *Clin Orthop Relat Res*. 2018;476:400–7.
2. Ritter MA, Faris PM, Keating EM, Meding JB. Postoperative alignment of total knee replacement. Its effect on survival. *Clin Orthop Relat Res*. 1994;153–6.
3. Yuan FZ, Wang SJ, Zhou ZX, Yu JK, Jiang D. Malalignment and malposition of quadriceps-sparing approach in primary total knee arthroplasty: A systematic review and meta-analysis. *J Orthop Surg Res*. 2017;12:1–7.
4. Meric G, Gracitelli GC, Aram LJ, Swank ML, Bugbee WD. Variability in Distal Femoral Anatomy in Patients Undergoing Total Knee Arthroplasty: Measurements on 13,546 Computed Tomography Scans. *J Arthroplasty*. 2015;30:1835–8.
5. Maestro A, Harwin SF, Sandoval MG, Vaquero DH, Murcia A. Influence of intramedullary versus extramedullary alignment guides on final total knee arthroplasty component position: A radiographic analysis. *J Arthroplasty*. 1998;13:552–8.
6. Dennis DA, Channer M, Susman MH, Stringer EA. Intramedullary versus extramedullary tibial alignment systems in total knee arthroplasty. *J Arthroplasty*. 1993;8:43–7.
7. Pang CH, Chan WL, Yen CH, Cheng SC, Woo SB, Choi ST, et al. Comparison of total knee arthroplasty using computer-assisted navigation versus conventional guiding systems: a prospective study. *J Orthop Surg (Hong Kong)*. 2009;17:170–3.
8. Jones CW, Jerabek SA. Current Role of Computer Navigation in Total Knee Arthroplasty. *J Arthroplasty*. 2018;33:1989–93.
9. Shoji H, Teramoto A, Suzuki T, Okada Y, Watanabe K, Yamashita T. Radiographic assessment and clinical outcomes after total knee arthroplasty using an accelerometer-based portable navigation device. *Arthroplast Today*. 2018;4:319–22. doi:10.1016/j.artd.2017.11.012.
10. Pfitzner T, Abdel MP, von Roth P, Perka C, Hommel H. Small Improvements in Mechanical Axis Alignment Achieved With MRI versus CT-based Patient-specific Instruments in TKA: A Randomized Clinical Trial. *Clin Orthop Relat Res*. 2014;472:2913–22.
11. Miura M, Hagiwara S, Nakamura J, Wako Y, Kawarai Y, Ohtori S. Interobserver and Intraobserver Reliability of Computed Tomography–Based Three-Dimensional Preoperative Planning for Primary

- Total Knee Arthroplasty. *J Arthroplasty*. 2018;33:1572–8. doi:10.1016/j.arth.2017.12.035.
12. Cretu BS, Dragosloveanu C, Dragosloveanu S, Cristea S. Radiographic Evaluation of Alignment Following Total Knee Arthroplasty - a Systematic Review. Part II. *Maedica (Buchar)*. 2018;13:105–11.
 13. Kottner J, Audige L, Brorson S, Donner A, Gajewski BJ, Hróbjartsson A, et al. Guidelines for Reporting Reliability and Agreement Studies (GRRAS) were proposed. *Int J Nurs Stud*. 2011;48:661–71.
 14. Paley D, Herzenberg JE, Tetsworth K, McKie J, Bhav A. Deformity planning for frontal and sagittal plane corrective osteotomies. *Orthop Clin North Am*. 1994;25:425–65.
 15. Lew. Design Based on Intra-Class Correlation Coefficients. *Am J Biostat*. 2010.
 16. Walter SD, Eliasziw M, Donner A. Sample size and optimal designs for reliability studies. *Stat Med*. 1998.
 17. Nam D, Vajapey S, Nunley RM, Barrack RL. The Impact of Imaging Modality on the Measurement of Coronal Plane Alignment After Total Knee Arthroplasty. *J Arthroplasty*. 2016;31:2314–9.
 18. Schmitt J, Hauk C, Kienapfel H, Pfeiffer M, Efe T, Fuchs-Winkelmann S, et al. Navigation of total knee arthroplasty: Rotation of components and clinical results in a prospectively randomized study. *BMC Musculoskelet Disord*. 2011;12:16.
 19. Koch PP, Müller D, Pisan M, Fucentese SF. Radiographic accuracy in TKA with a CT-based patient-specific cutting block technique. *Knee Surgery, Sport Traumatol Arthrosc*. 2013;21:2200–5.
 20. Dobbe JGG, Kievit AJ, Schafoth MU, Blankevoort L, Streekstra GJ. Evaluation of a CT-based technique to measure the transfer accuracy of a virtually planned osteotomy. *Med Eng Phys*. 2014;36:1081–7. doi:10.1016/j.medengphy.2014.05.012.
 21. Franceschi JP, Sbihi A. 3D templating and patient-specific cutting guides (Knee-Plan®) in total knee arthroplasty: Postoperative CT-based assessment of implant positioning. *Orthop Traumatol Surg Res*. 2014;100:S281–6. doi:10.1016/j.otsr.2014.04.003.
 22. Schiapparelli FF, Amsler F, Hirschmann MT. The type of approach does not influence TKA component position in revision total knee arthroplasty – A clinical study using 3D-CT. *Knee*. 2018;25:473–9. doi:10.1016/j.knee.2018.02.008.
 23. Schiapparelli FF, Amsler F, Hirschmann MT. Medial parapatellar approach leads to internal rotation of tibial component in total knee arthroplasty. *Knee Surgery, Sport Traumatol Arthrosc*. 2018;26:1564–70.
 24. Hirschmann MT, Iranpour F, Konala P, Kerner A, Rasch H, Cobb JP, et al. A novel standardized algorithm for evaluating patients with painful total knee arthroplasty using combined single photon emission tomography and conventional computerized tomography. *Knee Surgery, Sport Traumatol Arthrosc*. 2010;18:939–44.
 25. Rasch H, Falkowski AL, Forrer F, Henckel J, Hirschmann MT. 4D-SPECT/CT in orthopaedics: A new method of combined quantitative volumetric 3D analysis of SPECT/CT tracer uptake and component position measurements in patients after total knee arthroplasty. *Skeletal Radiol*. 2013;42:1215–23.

26. Hirschmann MT, Konala P, Amsler F, Iranpour F, Friederich NF, Cobb JP. The position and orientation of total knee replacement components: a comparison of conventional radiographs, transverse 2D-CT slices and 3D-CT reconstruction. *J Bone Joint Surg Br.* 2011;93:629–33.
27. Saffarini M, Nover L, Tandogan R, Becker R, Moser LB, Hirschmann MT, et al. The original Akagi line is the most reliable: a systematic review of landmarks for rotational alignment of the tibial component in TKA. *Knee Surgery, Sport Traumatol Arthrosc.* 2019;27:1018–27.

Figures

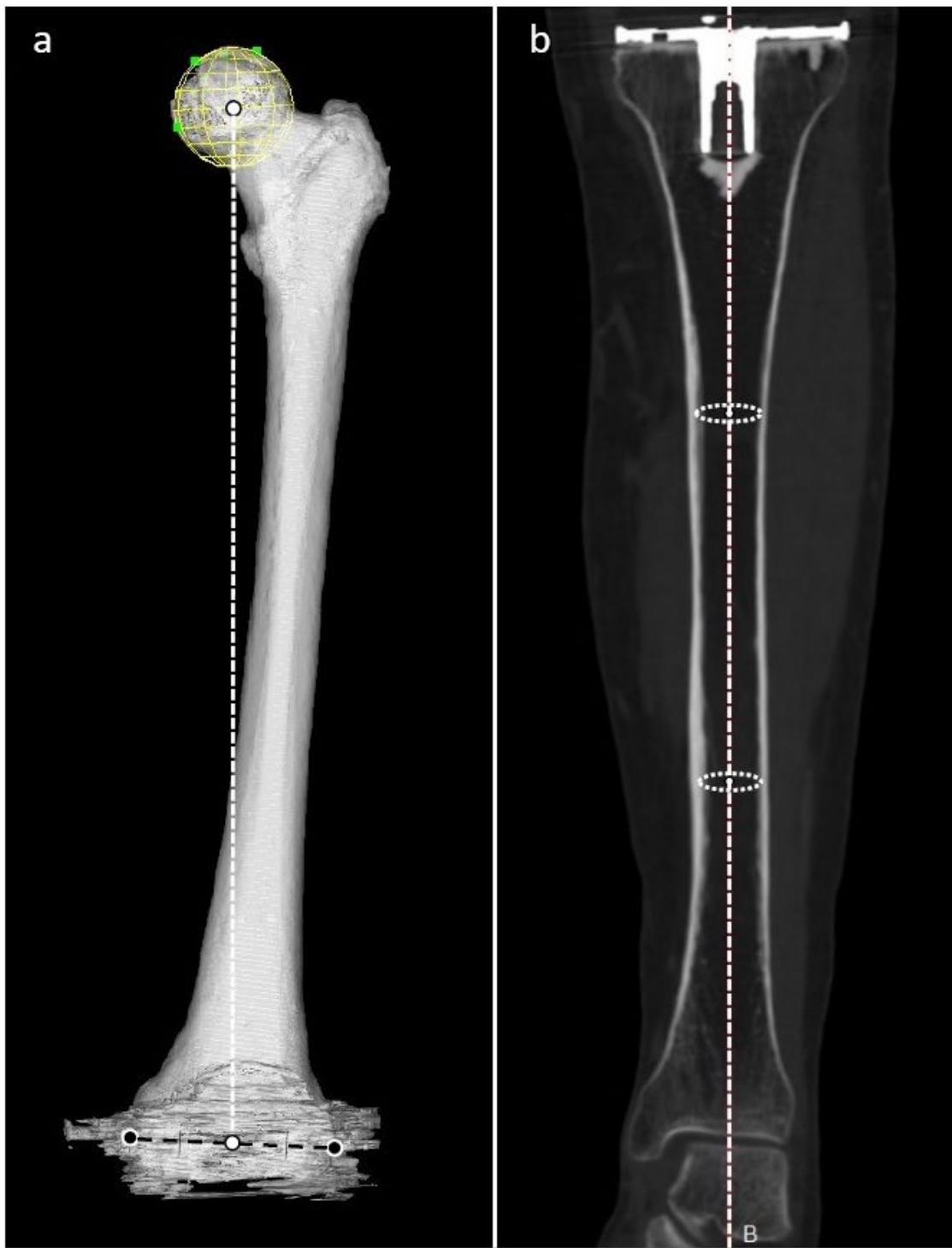


Figure 1

Reference points of the traditional mechanical axis. a: Three-dimensional image of the femur from the anterior aspect. The traditional mechanical axis of the femur was defined as the line connecting the white dots, which indicates the center of the femoral head and the center of the medial and lateral epicondyles (black dots). b: Multi-planar reconstruction coronal image of the tibia. Traditional mechanical alignment

of the tibia was defined as the axis connecting the center of the circles drawn inside the upper and lower one-third of the medullary canal of the tibia.

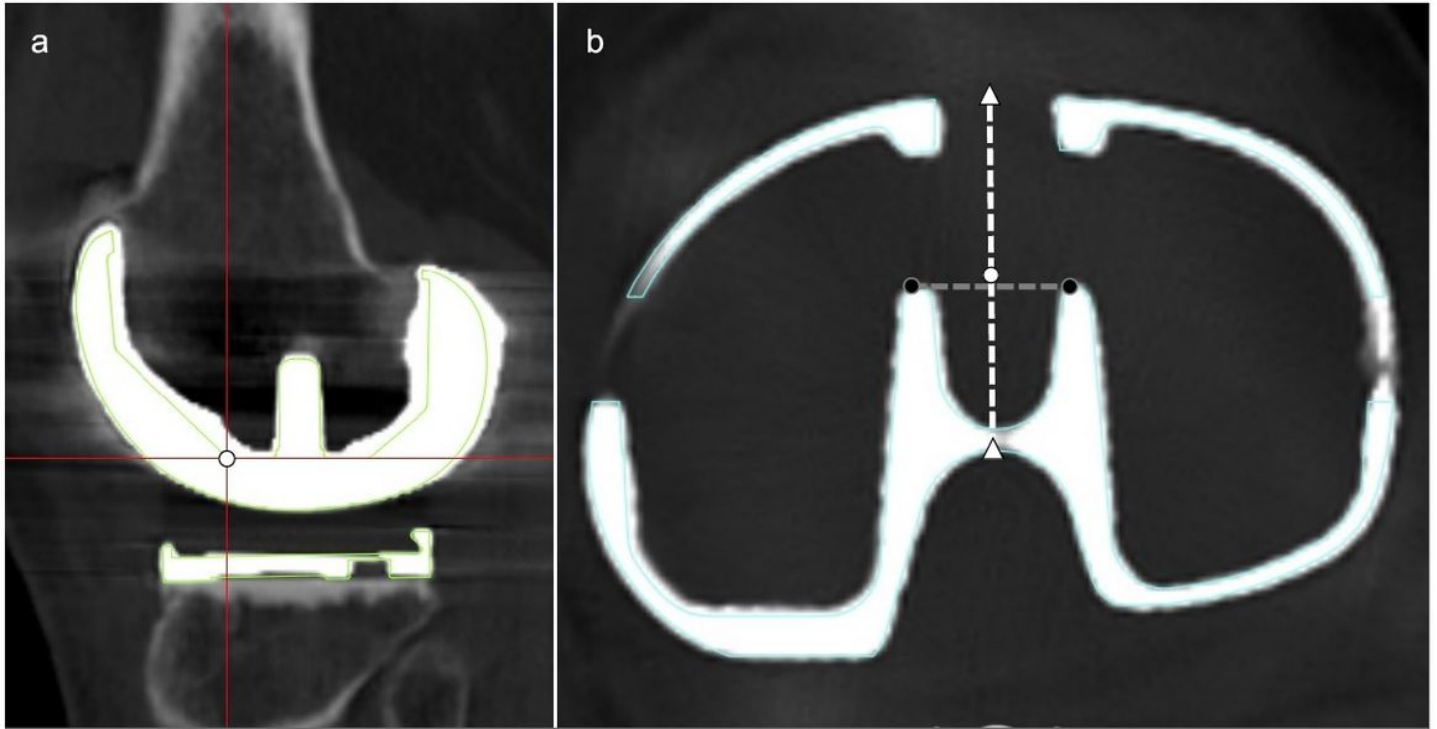


Figure 2

Reference points of the implant-based axis. a: Multi-planar sagittal reconstruction image of the femoral component. The mediolateral center at the distal end of the anterior chamfer was defined as the center of the femoral component. b: Multi-planar reconstruction axial image of the tibial tray. A perpendicular bisector of a line segment connecting the anterior end of the dovetails (black dots) and the center of the anteroposterior edges of the tibial tray (white triangles) was defined as the center of the tibial tray (white dot).