

# Assessment of anterior chamber configuration changes after phacoemulsification with swept-source optical coherence tomography

**Man Hu**

Wenzhou Medical University School of Optometry and Ophthalmology

**Qian Zheng**

Wenzhou Medical University School of Optometry and Ophthalmology

**Zhangliang Li**

Wenzhou Medical University School of Optometry and Ophthalmology

**Pingjun Chang**

Wenzhou Medical University School of Optometry and Ophthalmology

**Yun-e Zhao** (✉ [zyehzeye@126.com](mailto:zyehzeye@126.com))

Wenzhou Medical University School of Optometry and Ophthalmology <https://orcid.org/0000-0002-4535-318X>

---

## Research article

**Keywords:** Anterior chamber parameters, phacoemulsification, shallow anterior chamber, normal anterior chamber, anterior segment swept-source optical coherence tomography

**Posted Date:** May 27th, 2019

**DOI:** <https://doi.org/10.21203/rs.2.9863/v1>

**License:**  This work is licensed under a Creative Commons Attribution 4.0 International License.

[Read Full License](#)

---

# Abstract

**Background** To assess the changes of anterior chamber angle in patients with shallow anterior chamber and normal anterior chamber after phacoemulsification and intraocular lens implantation (IOL) using anterior segment swept-source optical coherence tomography (AS-SS-OCT). **Methods** This was a prospective case control study; 60 eyes of 60 patients who underwent cataract surgery. Based on anterior chamber depth (ACD) and gonioscopy findings, the eyes were classified into two groups, shallow anterior chamber group (30 eyes) and normal anterior chamber group (30 eyes). AS-SS-OCT was used to measure ACD and angle parameters angle opening distance (AOD), angle recess area (ARA), trabecular iris space area (TISA), and trabecular iris angle (TIA). Serial changes in each group were measured before and 3 months after phacoemulsification and IOL, and the differences between the two groups were compared. **Results** All angle parameters including ACD, AOD, ARA, TISA, and TIA in both groups at 3 months after cataract surgery were significantly different from the preoperative values ( $p < 0.01$ ). In addition, we found significant differences of all angle parameters between groups of shallow anterior chamber (SAC) and normal anterior chamber (NAC) (All  $P < 0.05$ ). Besides, the TISA750 in superior quadrant and anterior chamber volume (ACV) were significantly smaller in the group of SAC than those in the group of NAC ( $P = 0.041$  and  $0.002$ , respectively). **Conclusions** The parameters of anterior chamber increased significantly in both two groups but not increase to the same extent 3 months after phacoemulsification. Iris thickening may also be one of the narrow angle factors, not just age-related lens thickening.

## Introduction

In 2016, a multicenter randomized controlled trial published in Lancet by Azuara et al. found that clear-lens extraction showed greater efficacy and was more cost-effective than laser peripheral iridotomy, and should be considered as an option for first-line treatment of the primary angle-closure glaucoma [1]. Previous studies confirmed that cataract surgery with intraocular lens implantation (IOL) can deepen the anterior chamber and widen the anterior chamber angles. [2-7] The effect of cataract surgery on intraocular pressure (IOP) in glaucoma patients has been described in numerous studies in different subtypes of glaucoma [8, 9]. Cataract surgery may have improved anterior chamber angle parameters and decreased IOP in normal-tension glaucoma patients [10]. Therefore, more and more ophthalmologists tend to choose lens extraction for primary angle-closure glaucoma (PACG) and primary angle-closure glaucoma with increased IOP [2, 11].

Although the anterior chamber did deepen and the anterior chamber angle was widened after cataract surgery, whether the anterior chamber angle opening and anterior segment structure can reach the normal level of cataract patients with shallow anterior chamber and narrow angle after surgery remains to be studied.

Chinese individuals are at a high risk for angle closure. The 10-year cumulative incidence of any forms of primary angle closure (PAC) was 20.5% in an urban Chinese population aged 50 years and older. Small ocular dimensions and hyperopia at baseline were associated with the development of angle closure [12].

The purpose of the current study was to evaluate the effects of cataract surgery on anterior segment structure and angle parameters in Chinese population by using anterior segment swept-source optical coherence tomography (AS-SS-OCT) technique. By comparing the anterior chamber angle parameters of shallow narrow anterior chamber and normal anterior chamber before and 3 months after operation, to investigate the changes of anterior chamber depth and angle-related parameters after surgery. We hope to obtain more strong evidence from AS-SS-OCT to confirm whether there are any other factors affecting the anterior chamber angle structure other than lens.

## Methods

In this prospective study, we randomly selected patients who underwent cataract surgery at a tertiary referral center in Southeast China. The study was approved by the institutional review board and complied with the tenets of the Declaration of Helsinki. Informed consent was obtained from each patient.

Each patient received a comprehensive eye examination, including visual acuity, subjective refraction, slit-lamp evaluation, noncontact tonometry (TX-F; Cannon, Tokyo, Japan), gonioscopy, dilated fundus examination, and AS-SS-OCT.

Inclusion criteria were age-related cataract patients who were scheduled for elective phacoemulsification. Exclusion criteria included diagnosed primary angle closure with evidence of previous acute episode, established peripheral anterior synechias, established primary angle-closure glaucoma with glaucomatous damage of the optic nerve and visual field defects, ocular comorbidity other than cataract (eg, primary open angle glaucoma, normal tension glaucoma, uveitis, history of ocular surgery or injury), and intraoperative or postoperative complications (eg, posterior capsule tear, zonular dialysis, IOL tilting, subluxation or dislocation, prolonged postoperative inflammation).

Based on the ACD and gonioscopy findings, patients were divided into two groups: open-angle group and narrow-angle group. Open-angle group defined as:  $ACD > 2.68$  measured by the AS-SS-OCT<sup>[13]</sup> and angle  $>$  Shaffer 2 in four quadrants under gonioscope<sup>[14]</sup>; Narrow-angle group defined as:  $ACD \leq 2.68$  measured by the AS-SS-OCT<sup>[13]</sup> and angle  $\leq$  Shaffer 2 in four quadrants under gonioscope<sup>[14]</sup>.

### Anterior Chamber Measurement

AS-SS-OCT (SS-1000 CASIA; Tomey CO. Ltd, Nagoya, Japan) was performed preoperatively and 3 months postoperatively. For each patient, 3 consecutive measurements were done by a same technician without dilation in a light room. To avoid lid artifact, participants were instructed to pull down the lower lid against the lower orbital rim to expose the lower limbus while the technician elevated the upper lid against the upper orbital rim to expose the upper limbus<sup>[15]</sup>. The image with best exposure was analyzed.

ACD, anterior chamber volume (ACV) and angle parameters, including angle opening distance 750[ $\mu\text{m}$ ] (AOD750), anterior recess area at 750[ $\mu\text{m}^2$ ] (ARA750), trabecular iris space area 750[ $\mu\text{m}^2$ ]

(TISA750), trabecular iris angle 750 [deg] (TIA750), were measured and compared between the two groups. We repeated the measurements in each quadrant.

AOD750 was defined as the perpendicular distance measured from the trabecular meshwork at 750µm anterior to the scleral spur to the anterior iris surface<sup>[16]</sup>. ARA750 was the area bordered by the anterior surface of the iris, corneal endothelium and a line perpendicular to the corneal endothelium drawn from a point 750µm anterior to scleral spur to the iris surface<sup>[17]</sup>. TISA750 was an area bounded anteriorly by the AOD, posteriorly by a line drawn from the scleral spur perpendicular to the plane of the inner scleral wall to the opposing iris, superiorly by the inner corneoscleral wall, and inferiorly by the iris surface<sup>[16]</sup>. TIA 750 was calculated as an angle measured with the apex in the iris recess and the arms of the angle passing through a point on the trabecular meshwork 750µm from the scleral spur and the point on the iris perpendicularly opposite<sup>[18]</sup>.

## Results

A total of 60 eyes of 60 patients were recruited in our study. Table 1 showed the demographic characteristics. There were no significant differences of age, axial length (AL), corneal curvature, cornea diameter, IOP between groups of SAC and NAC ( $P > 0.05$ ). Only iris volume (IV) of the two groups has significant different ( $p < 0.0001$ ).

### *Preoperative Anterior Segment Comparison*

All the anterior segment parameters, including AOD750, ARA750, TISA750, TIA, and ACV, showed significant differences between groups of SAC and NAC before surgery (All  $P < 0.005$ ) (Figure 1 & Figure 2). ACV in group of SAC and NAC before surgery were 91.24(84.23,109.57) and 145.11(115.62,159.06) (Figure 2).

### *Postoperative Anterior Segment Comparison*

We found significant differences of AOD750, ARA750, TISA750, and TIA in nasal and inferior quadrants, between groups of SAC and NAC (All  $P < 0.05$ ). Besides, the TISA750 in superior quadrant and ACV were significantly smaller in the group of SAC than those in the group of NAC ( $P = 0.041$  and  $0.002$ , respectively) (Figure 2 & Figure 3). At 3 months after operation, ACV of SAC and NAC groups were  $161.37 \pm 19.47$  and  $178.26 \pm 20.30$  ( $p = 0.002$ ). (Figure 2).

## Discussion

As in previous cross-sectional studies, greater lens thickness, shallower ACD, narrower angle width and more hyperopic spherical equivalent at baseline were predictors for the development of angle closure<sup>[19]</sup>. Cataract surgery can deepen the anterior chamber and increase the width of anterior chamber angle.<sup>[18, 20-23]</sup> Hoy's study showed phacoemulsification led to anterior chamber deepening and lower IOP in eyes with occludable angles compares to eyes with open angles, which suggests it is an option for preventing

acute angle–closure attacks in eyes with occludable angle and cataract<sup>[24]</sup>. Kasai's research team also confirmed that cataract surgery increases ACD and all angle parameters early after the surgery. However, the degree of angle widening in narrow-angle eyes was not as much as that in open-angle eyes, suggesting that factors other than the lens influence the angle closure<sup>[25]</sup>. But there were several limitations and defects in the gonioscopy, ultrasound biomicroscopy (UBM) and even AS-OCT which they used to examine the anterior chamber. To the best of our knowledge, there is no comparative study on the fine structure of anterior chamber angle using anterior segment swept-source optical coherence tomography (AS-SS-OCT) before and after cataract surgery in Chinese population.

Further studies have been carried out to explore the changes of the angle structure of the anterior chamber after phacoemulsification by AS-OCT<sup>[1-12]</sup>. It has the advantage of allowing rapid cross-sectional imaging of the anterior chamber than UBM and does not require contact with the globe. However, AS-OCT can only detect the horizontal angle information, and cannot fully represent the 360-degree anterior chamber angle and the changes of the three-dimensional space of the anterior chamber. AS-SS-OCT was verified to be suitable for assessment of angle and angle-related parameters by some authors<sup>[15, 26-28]</sup>. With a substantial improvement in scan speed (30,000 A-scans per second), the anterior chamber angles can be imaged in 128 cross-sections (each with 512 A-scans) 360° around the anterior segment in 2.4 seconds<sup>[26]</sup>. Therefore, through the AS-SS-OCT examination, we can understand the anterior chamber and anterior chamber angles more comprehensively than previous studies.

In our study, cataract patients were divided into two groups by ACD and anterior chamber angle: shallow anterior chamber and normal anterior chamber. The ACV and other anterior chamber angle parameters of cataract patients before and 3 months (usually the stable period after surgery) after surgery were measured by AS-SS-OCT. The results obtained are basically consistent with previous studies. What is different from other studies is that our analysis showed that there were differences in anterior chamber depth, anterior chamber volume and angle openness between the two groups postoperatively, and the postoperative ACV in the shallow anterior chamber group were still relatively small. In recent years, only one research report has obtained similar results, but its application is the AS-OCT technology, and it only evaluates the anterior chamber angle parameters one day after operation. There is no long-term observation after operation.<sup>[25]</sup>

Our results showed that there was no significant difference in the preoperative axial length, corneal curvature and corneal diameter between the two groups, but the shallow anterior chamber group had a larger iris volume. It is speculated that the reason for the failure of ACD and ACV to return to normal anterior chamber group after shallow anterior chamber surgery may be related to the thicker iris. Whether there is ciliary body abnormalities at the same time remains to be further observed.

There are some limitations in this study. Firstly, as AS-SS-OCT could not measure the ciliary body as UBM or gonioscopy does, the data of ciliary body structure could not be obtained. Secondly, the sample size of this study was small.

## Conclusions

In this study, AS-SS-OCT was used to quantitatively evaluate the changes of anterior chamber morphology before and after cataract surgery in two groups. It was proved that cataract surgery can deepen anterior chamber and increase the width of anterior chamber angle in Chinese population, but the patients with narrow anterior chamber angle have not reached the level of normal people, presumably because of the thicker iris. Therefore, cataract surgery may not completely eliminate the risk of glaucoma in this group of people after surgery, it still needs close observation.

## Abbreviations

**IOL**: intraocular lens implantation; **AS-SS-OCT**: anterior segment swept-source optical coherence tomography; **ACD**: anterior chamber depth; **AOD**: angle opening distance; **ARA**: angle recess area; **TISA**: trabecular iris space area; **TIA**: trabecular iris angle; **IOP**: intraocular pressure; **PACG**: primary angle-closure glaucoma; **UBM**: ultrasound biomicroscopy; **AS-OCT**: anterior segment optical coherence tomography; **AOD500**: angle opening distance at 500[ $\mu\text{m}$ ]; **TISA500**: trabecular-iris space at 500 $\mu\text{m}$ ; **PAC**: primary angle closure; **ACV**: anterior chamber volume; **AOD750**: angle opening distance at 750[ $\mu\text{m}$ ]; **ARA750**: anterior recess area at 750[ $\mu\text{m}^2$ ]; **TISA750**: trabecular iris space area 750[ $\mu\text{m}^2$ ]; **TIA750**: trabecular iris angle 750 [deg]; **IV**: iris volume; **SAC**: shallow anterior chamber; **NAC**: normal anterior chamber

## Declarations

**Ethics approval and consent to participate**: This study has been performed in accordance with the Declaration of Helsinki and was approved by the Ethics Committee of the Eye Hospital, WenZhou Medical University.

**Consent for publication**: Written informed consents were obtained from all subjects.

**Availability of data and material**: All data generated or analyzed during this study are included in this published article

**Competing interests**: The authors declare that they have no competing interests

**Funding**: This work was supported by Provincial construction project of Zhejiang (Grant No. 2016147538), The Innovation Discipline of Zhejiang Province (Lens disease in children).

**Authors' contributions**: QZ performed the AS-SS-OCT examination, CPJ and ZLL analyzed and interpreted the patient data. MH was a major contributor in writing the manuscript. YEZ made substantial contributions to the conception design of the work and reviewed the manuscript. All authors read and approved the final manuscript.

**Acknowledgements**: Not applicable.

## References

- [1] Azuara-Blanco A, Burr J, Ramsay C, et al. Effectiveness of early lens extraction for the treatment of primary angle-closure glaucoma (EAGLE): a randomised controlled trial. *Lancet*. 2016. 388(10052): 1389-1397.
- [2] Friedman DS, He M. Anterior chamber angle assessment techniques. *Surv Ophthalmol*. 2008. 53(3): 250-73.
- [3] Kim M, Park KH, Kim TW, Kim DM. Anterior chamber configuration changes after cataract surgery in eyes with glaucoma. *Korean J Ophthalmol*. 2012. 26(2): 97-103.
- [4] Hayashi K, Hayashi H, Nakao F, Hayashi F. Changes in anterior chamber angle width and depth after intraocular lens implantation in eyes with glaucoma. *Ophthalmology*. 2000. 107(4): 698-703.
- [5] Altan C, Bayraktar S, Altan T, Eren H, Yilmaz OF. Anterior chamber depth, iridocorneal angle width, and intraocular pressure changes after uneventful phacoemulsification in eyes without glaucoma and with open iridocorneal angles. *J Cataract Refract Surg*. 2004. 30(4): 832-8.
- [6] Nolan WP, See JL, Aung T, et al. Changes in angle configuration after phacoemulsification measured by anterior segment optical coherence tomography. *J Glaucoma*. 2008. 17(6): 455-9.
- [7] Kucumen RB, Yenerel NM, Gorgun E, Kulacoglu DN, Dinc UA, Alimgil ML. Anterior segment optical coherence tomography measurement of anterior chamber depth and angle changes after phacoemulsification and intraocular lens implantation. *J Cataract Refract Surg*. 2008. 34(10): 1694-8.
- [8] Lam DS, Leung DY, Tham CC, et al. Randomized trial of early phacoemulsification versus peripheral iridotomy to prevent intraocular pressure rise after acute primary angle closure. *Ophthalmology*. 2008. 115(7): 1134-40.
- [9] Husain R, Gazzard G, Aung T, et al. Initial management of acute primary angle closure: a randomized trial comparing phacoemulsification with laser peripheral iridotomy. *Ophthalmology*. 2012. 119(11): 2274-81.
- [10] Lee W, Bae HW, KCY, Seong GJ. The change of anterior segment parameters after cataract surgery in normal-tension glaucoma. *Int J Ophthalmol*. 2017. 10(8): 1239-1245.
- [11] Masis M, Mineault PJ, Phan E, Lin SC. The role of phacoemulsification in glaucoma therapy: A systematic review and meta-analysis. *Surv Ophthalmol*. 2018. 63(5): 700-710.
- [12] Wang L, Huang W, Huang S, et al. Ten-year incidence of primary angle closure in elderly Chinese: the Liwan Eye Study. *Br J Ophthalmol*. 2018 .

- [13] Nongpiur ME, Haaland BA, Friedman DS, et al. Classification algorithms based on anterior segment optical coherence tomography measurements for detection of angle closure. *Ophthalmology*. 2013. 120(1): 48-54.
- [14] SHAFFER RN. Operating room gonioscopy in angle-closure glaucoma surgery. *AMA Arch Ophthalmol*. 1958. 59(4): 532-5.
- [15] Mak H, Xu G, Leung CK. Imaging the iris with swept-source optical coherence tomography: relationship between iris volume and primary angle closure. *Ophthalmology*. 2013. 120(12): 2517-2524.
- [16] Narayanaswamy A, Sakata LM, He MG, et al. Diagnostic performance of anterior chamber angle measurements for detecting eyes with narrow angles: an anterior segment OCT study. *Arch Ophthalmol*. 2010. 128(10): 1321-7.
- [17] Esaki K, Ishikawa H, Liebmann JM, Greenfield DS, Uji Y, Ritch R. Angle recess area decreases with age in normal Japanese. *Jpn J Ophthalmol*. 2000. 44(1): 46-51.
- [18] Pavlin CJ, Harasiewicz K, Foster FS. Ultrasound biomicroscopy of anterior segment structures in normal and glaucomatous eyes. *Am J Ophthalmol*. 1992. 113(4): 381-9.
- [19] George R, Paul PG, Baskaran M, et al. Ocular biometry in occludable angles and angle closure glaucoma: a population based survey. *Br J Ophthalmol*. 2003. 87(4): 399-402.
- [20] Nonaka A, Kondo T, Kikuchi M, et al. Angle widening and alteration of ciliary process configuration after cataract surgery for primary angle closure. *Ophthalmology*. 2006. 113(3): 437-41.
- [21] Nonaka A, Kondo T, Kikuchi M, et al. Cataract surgery for residual angle closure after peripheral laser iridotomy. *Ophthalmology*. 2005. 112(6): 974-9.
- [22] Memarzadeh F, Tang M, Li Y, Chopra V, Francis BA, Huang D. Optical coherence tomography assessment of angle anatomy changes after cataract surgery. *Am J Ophthalmol*. 2007. 144(3): 464-5.
- [23] Pereira FA, Cronemberger S. Ultrasound biomicroscopic study of anterior segment changes after phacoemulsification and foldable intraocular lens implantation. *Ophthalmology*. 2003. 110(9): 1799-806.
- [24] Shin HC, Subrayan V, Tajunisah I. Changes in anterior chamber depth and intraocular pressure after phacoemulsification in eyes with occludable angles. *J Cataract Refract Surg*. 2010. 36(8): 1289-95.
- [25] Kasai K, Takahashi G, Kumegawa K, Dogru M. Measurement of early changes in anterior chamber morphology after cataract extraction measured by anterior segment optical coherence tomography. *Graefes Arch Clin Exp Ophthalmol*. 2015. 253(10): 1751-6.
- [26] Liu S, Yu M, Ye C, Lam DS, Leung CK. Anterior chamber angle imaging with swept-source optical coherence tomography: an investigation on variability of angle measurement. *Invest Ophthalmol Vis Sci*.



2011. 52(12): 8598-603.

[27] Lai I, Mak H, Lai G, Yu M, Lam DS, Leung CK. Anterior chamber angle imaging with swept-source optical coherence tomography: measuring peripheral anterior synechia in glaucoma. *Ophthalmology*. 2013. 120(6): 1144-9.

[28] Baskaran M, Ho SW, Tun TA, How AC, Perera SA, Freidman DS, Aung T. Assessment of Circumferential Angle-Closure by the IriseTrabecular Contact Index with Swept-Source Optical Coherence Tomography . *Ophthalmology*. 2013 Nov;120(11):2226-31.

## Tables

Table 1. Demographic characteristics.			
	SAC	NAC	P
N. of eyes	30	30	
N. of patients	30	30	
Gender (Male/Female)	15/15	6/24	
Age (y)	63.6±10.8	68.4±8.4	0.107
AL (mm)	23.28±0.70	22.87±0.89	0.080
Corneal curvature (D)	7.35±0.03	7.33±0.03	0.076
Cornea diameter[mm]	11.62±0.05	11.60±0.06	0.501
IOP (mmHg)	10.2(8.7, 14.3)	11.9(9.5,14.6)	0.158
IV(mm <sup>3</sup> )	35.05±4.37	36.14±3.57	<0.0001
SAC = Shallow Anterior Chamber, NAC = Normal Anterior Chamber;			

## Figures

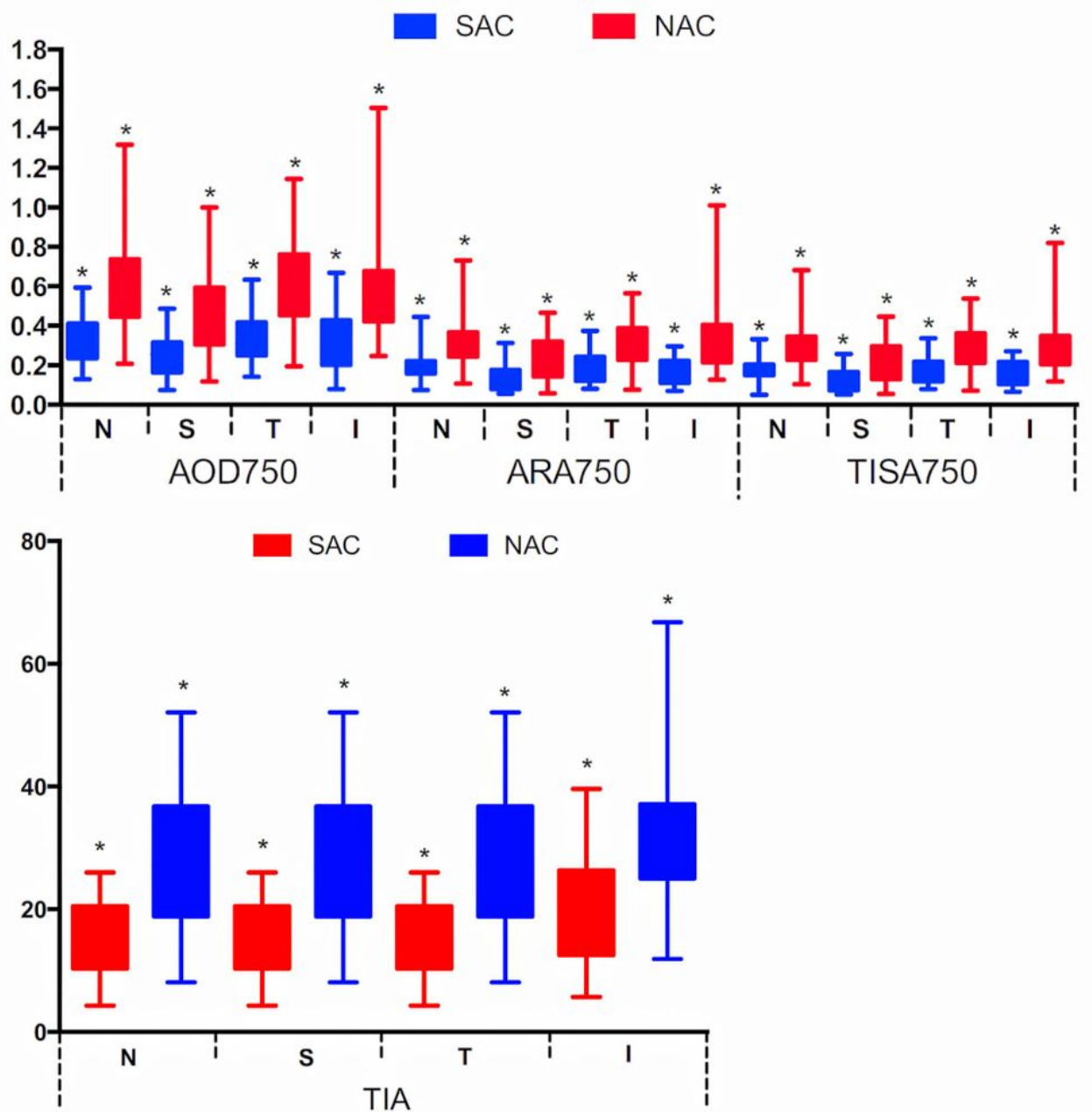


Figure1.

All the anterior segment parameters, including AOD750, ARA750, TISA750, TIA showed significant differences between groups of SAC and NAC before surgery(All  $P < 0.005$ )

Figure 1

All the anterior segment parameters, including AOD750, ARA750, TISA750, TIA showed significant differences between groups of SAC and NAC before surgery(All  $P < 0.005$ )

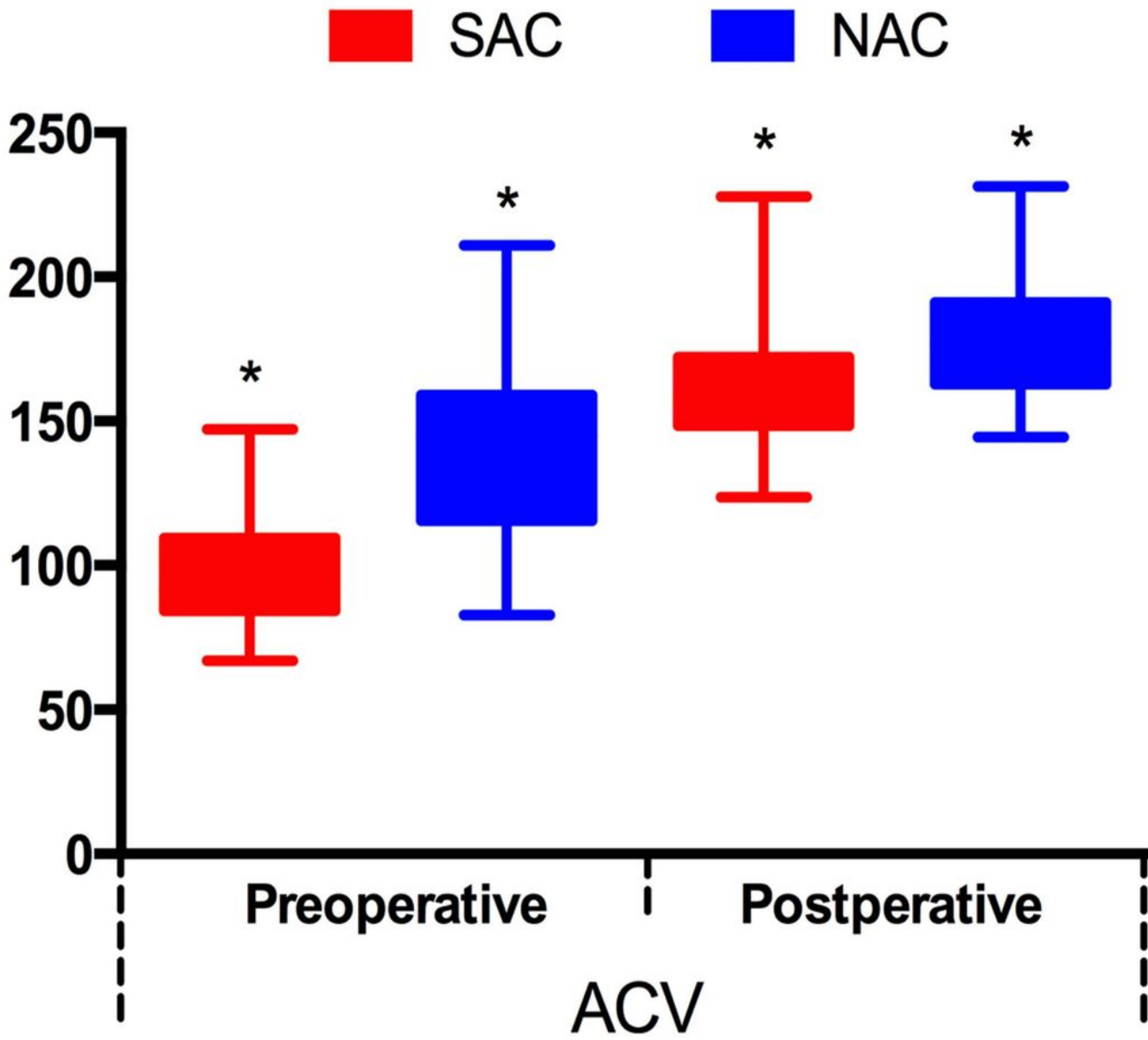


Figure2.

ACV of SAC and NAC groups before surgery were 91.24(84.23,109.57) and 145.11(115.62,159.06), At 3 months after operation, ACV of SAC and NAC groups were  $161.37 \pm 19.47$  and  $178.26 \pm 20.30$ . ACV was significantly smaller in the group of SAC than in the NAC ( $p=0.002$ ).

Figure 2

ACV of SAC and NAC groups before surgery were 91.24(84.23,109.57) and 145.11(115.62,159.06) At 3 months after operation, ACV of SAC and NAC groups were  $161.37 \pm 19.47$  and  $178.26 \pm 20.30$ . ACV was significantly smaller in the group of SAC than in the NAC ( $p=0.002$ ).

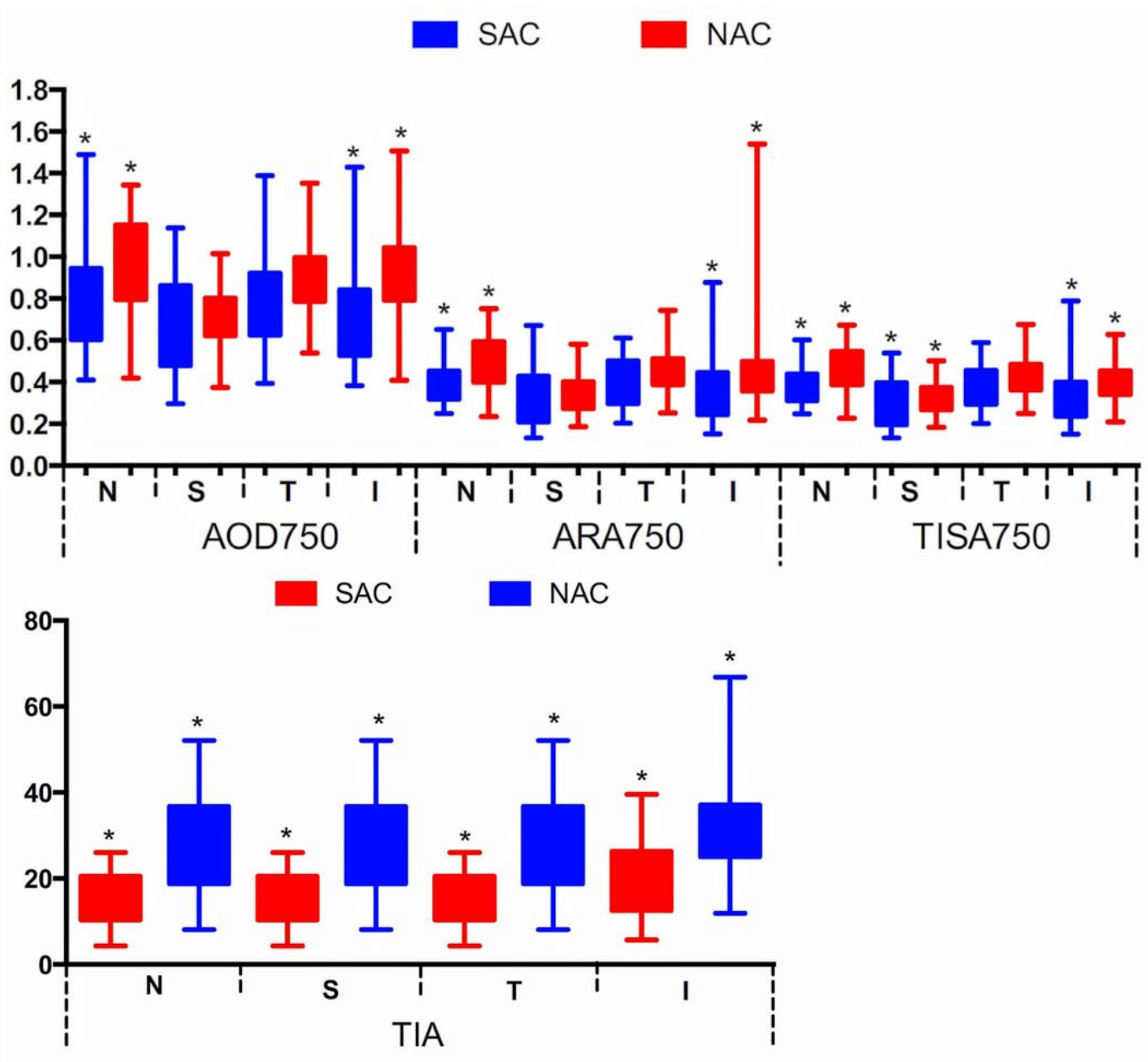


Figure3.

There were significant differences of AOD750, ARA750, TISA750, and TIA in nasal and inferior quadrants, between groups of SAC and NAC (All  $P < 0.05$ ). Besides, the TISA750 in superior quadrant were significantly smaller in the group of SAC than those in the group of NAC ( $P = 0.041$ ).

### Figure 3

There were significant differences of AOD750, ARA750, TISA750, and TIA in nasal and inferior quadrants, between groups of SAC and NAC (All  $P < 0.05$ ). Besides, the TISA750 in superior quadrant were significantly smaller in the group of SAC than those in the group of NAC ( $P = 0.041$ ).