

Redistribution of the Corneal Epithelium After Overnight Wear of Orthokeratology Contact Lenses for Myopia Reduction

Ju Zhang

Shandong Eye Hospital

Jing Li

Shandong Eye Hospital

Xiaofeng Li

Shandong Eye Hospital

Fengjie Li

Shandong Eye Hospital

Ting Wang (✉ Wt-ting@163.com)

Research Article

Keywords: orthokeratology, corneal epithelium, thickness, FD-OCT

Posted Date: January 4th, 2019

DOI: <https://doi.org/10.21203/rs.2.104/v2>

License:  This work is licensed under a Creative Commons Attribution 4.0 International License.

[Read Full License](#)

Version of Record: A version of this preprint was published at Contact Lens and Anterior Eye on June 1st, 2020. See the published version at <https://doi.org/10.1016/j.clae.2020.02.015>.

Abstract

Background: To investigate changes in the corneal epithelium topographic map in juvenile myopia after overnight wear of orthokeratology lenses (OK).

Methods: A total of 53 juveniles (53 right eyes) successfully wore OK and were reviewed in a timely manner from January 2016 to July 2017. Epithelial and corneal data were obtained by optical coherence tomography (OCT). Changes in uncorrected visual acuity, diopter, corneal refractive power, and epithelial and corneal thickness were analyzed before and after 1 day, 1 week, and 1 mo of overnight wear of OK.

Results: The corneal epithelium was reshaped after 1 day of OK; the myopia degree was reduced, and uncorrected visual acuity reached 0 logMAR at 1 week. The central (2-mm) average epithelial thickness was $52.04 \pm 2.35 \mu\text{m}$, $49.25 \pm 2.67 \mu\text{m}$, $45.91 \pm 2.80 \mu\text{m}$, and $47.53 \pm 3.44 \mu\text{m}$ before and after 1 day, 1 week, and 1 mo of OK, respectively ($t=10.122$, 10.782 , and 10.673 , respectively, $P \leq 0.001$). The central epithelium appeared to have a thinning trend, which was obvious at 1 week, when the average thinning of $6.13 \pm 1.67 \mu\text{m}$ accounted for approximately $11.78\% \pm 3.21\%$ of the total epithelium thickness. The epithelial thickness of the reverse curve zone was $51.83 \pm 2.49 \mu\text{m}$, $57.62 \pm 3.01 \mu\text{m}$, $59.43 \pm 3.19 \mu\text{m}$, and $60.22 \pm 2.75 \mu\text{m}$ before and after 1 day, 1 week, and 1 mo of OK, respectively, showing a significant increase over time ($t=5.325$, 6.177 , and 6.312 , respectively, $P \leq 0.001$).

Conclusion: In the early stage of OK, the corneal epithelium was redistributed very quickly. The central epithelium became thin, while the epithelium of the reverse curve zone correspondingly thickened and achieved a plateau at 1 mo. Epithelial redistribution guaranteed uncorrected visual acuity after removal of OK.

Background

The corneal epithelium, which is the most superficial layer of the cornea, not only has a good protective function but is also involved in corneal refractive function; in particular, the central corneal epithelium has an especially important function for corneal refraction [1, 2]. Overnight wear of OK is used to intentionally manipulate corneal shape, reduce refractive error and central corneal thickness, and effectively reduce and control myopia [3, 4]. Current research shows that OK mainly caused global epithelial and former stromal changes [5, 6]. However, how the corneal epithelium is redistributed in this process is less reported.

The advent of several imaging modalities, such as high frequency scanning ultrasound biomicroscopy, confocal microscopy through focusing, and optical coherence tomography (OCT), have facilitated measurement of corneal epithelial and corneal thickness. Among them, OCT has been reported as a repeatable and reproducible method with its advantages such as higher scanning speed and resolution [7, 8], it creates good conditions for further research on the cornea and epithelium. This study

continuously monitored the changes in the epithelial and corneal thickness in the central 6-mm area before and after lens wear by Fourier-domain OCT, monitoring measured including uncorrected visual acuity, eye diopter, corneal refractive power, and the epithelial Min-Max value (Difference between the thinnest and thickest corneal epithelium thickness within 5mm of central cornea). The results are reported as follows.

Materials And Methods

Clinical data

Fifty-three patients (53 right eyes) were included in this study from January 2016 to July 2017, wearing OK lenses overnight once the risks and benefits of OK wear had been explained. Fifty-three right eyes of all subjects were enrolled. All subjects had low to moderate myopia and with-the-rule refractive and corneal astigmatism of 1.50 diopters (D) or less. There were 31 male cases and 22 female cases, with an age range of 8-17 years and an average age of 12.3 ± 2.7 years. The diopter range was -0.75 D to -5.00 D, and the average spherical refractive error was -3.35 ± 1.09 D. The exclusion criteria included contraindications to ocular and systemic OK and was determined by routine examination. This research conforms to the Declaration of Helsinki and was approved by the ethics committee of the Shandong Eye Hospital. All subjects' guardians signed an informed consent form. This study is an observational study.

Lenses material and design

The AUTEK CHINA, INC. (Hefei, China) production of the rigid permeability OK lenses was adopted in this study. These lenses are made of Boston XO material, with a nominal total diameter of 10.4-10.8 mm, an optical zone diameter of 5.9-6.0 mm, and a reverse curve zone of 0.6 mm, giving a nominal oxygen transmissibility (Dk/t) of $100 \times 10^{-11} (\text{cm}^2/\text{s})$ ($\text{mlO}_2/\text{ml} \times \text{mmHg}$).

Lens Fitting and wearing methods

Dynamic requirements included lenses that fit above and below the cornea and moved approximately 1-2 mm with blinking and eye movement. When not blinking, the lenses would automatically return to the central cornea. Static requirements included clear fluorescein staining of the lenses corresponding to each segment and a 3-5-mm contact area in the central region of the cornea. Wearing methods included 8-10 hours of OK wear during nightly sleep. Upon opening the eyes in the morning, artificial tears without preservatives were applied, and the lenses were removed after 10 min.

Examinations

Patients wearing lenses were regularly examined at 1 day, 1 week, and 1 mo following the start of OK use. Routine examinations included location of OK lenses, uncorrected vision, corrected visual acuity, intraocular pressure, slit lamp microscope, conjunctiva, cornea, lens fitting, lens cleanliness and corneal tomography OCT (RTVue100-2OCT, Optovue companies in the United States). All examinations were done 2 hours after the removal of the lenses in the morning. The data for epithelial and corneal thickness in the

central 6-mm range for 17 regions were collected (see Figure 1). Average values in 17 areas were obtained: 1) one central zone within 0-2 mm diameter, 2) eight paracentral zones from 2-5 mm diameter, and 3) eight peripheral zones from 5-6 mm diameter. To reduce measurement error, OCT examinations were carried out by the same skilled physician. Each eye was scanned 3 times. The reverse curve zone on the corneal topographic map was marked and the thickness of the corneal epithelium and cornea at any one point in 8 regions was manually measured (see Figure 2). In the process, we compared the corneal topography with the OCT image of the corneal epithelium, manually marking the annular area where the curvature was significantly steeper and the corneal epithelium was significantly thickened, defined as the position of the reverse curve zone.

Statistical analysis

In this study, the average values of the epithelial and corneal thickness of the eight regions in the circle were used in the paracentral, peripheral and reverse curve zones. The research data is a normal distribution through the (Kolmogorov-Smirnov) test. Epithelial and corneal thickness before and after OK wear were compared with a paired t-test analysis by the SPSS 18 statistical software.

Results

1. The location of OK, visual acuity, diopter and corneal surface parameters on OCT pachymetry map before and after lenses wear

During lenses wear, 60.4% (32/53) of the patients had the lens centered, 39.6% of them had different degrees of decentration that were less than 1.0 mm, according to the classification method of Tsai et al[9]. Uncorrected visual acuity improved significantly after 1 day of lens wear. The uncorrected visual acuity tended to stabilize at 1 week. There were significant differences in uncorrected visual acuity, diopter, and corneal refractive power between different stages of lens wear. The corneal refractive power of the front surface decreased after 1 day of lens wear and gradually stabilized at 1 week. The corneal refractive power of the back surface exhibited little change at each point time, and compared to before lens wear, there was no significant difference. The min-max value obviously increased after lens wear and gradually stabilized at 1 week. There were significant differences between before and after lens wear (see Table 1).

2. Epithelial thickness comparison in different areas before and after lens wear

The corneal epithelial thickness of the central 2 mm became thinner after 1 day of lens wear and achieved the thinnest points at 1 week. The central epithelial thickness became thin, with a range of 5-13 μm and average thinning of $6.13 \pm 1.67 \mu\text{m}$. The paracentral 2-5-mm and peripheral 5-6-mm average corneal epithelial thickness changes varied over time but not significantly. After lens wear, the reverse curve zone epithelium thickened after 1 day and gradually became stable at 1 week. Compared with the thickness before lens wear, the thickness at each time point after lens wear was significant (see Table 2).

3. Corneal thickness comparison in different areas before and after lens wear

The corneal thickness of the central 2 mm became thinner 1 day after lens wear, while the peripheral 5-6-mm corneal thickness gradually increased with lens wear. There was an average thickening of $7.35 \pm 1.35 \mu\text{m}$ at 1 mo of lens wear, which was significant. Compared with the thickness before lens wear, there was an obvious thickening of the reverse curve zone of the cornea after 1 day of lens wear (see Table 3).

4. Central epithelial and corneal thickness change comparison after lens wear

We also analyzed the central epithelial and corneal thickness changes at different time points. The changes in central epithelial thickness were basically equivalent to the corneal thickness changes at 1 week of lens wear, but the corneal epithelial thinning range was less than the corneal thickness at 1 mo of lens wear (see Figure 3).

Discussion

OK can quickly, effectively and temporarily correct myopia by changing the shape of the cornea. The reshaping of the corneal epithelium plays an important role in this process [10]. Some authors [2, 11-13] found that the main change in corneal thickness was in the corneal epithelium after OK lens wear. However, there is still no internationally unified view on how the corneal epithelium is redistributed after lens wear [10, 14-17]. Lian Y [10] found central, horizontal, and vertical meridian epithelium thinning, horizontal meridian nasal temporal side paracentral epithelial thickening, and above vertical meridian paracentral epithelium thinning at 1 mo of lens wear by UHR-OCT. Chen R [14] found that the central epithelium thinned and the corneal stroma thickened at 1 day of lens wear. Nieto-Bona-A [15] observed that the central 2-mm corneal epithelium was thinning, while there was no obvious change in corneal stroma by confocal microscope. Qian Y [16] observed that the thinnest corneal epithelial point was in the temporal and inferior region of the paracentral area within 14 days of lens wear and that the thickest point was located in the superior and inferior region of the corneal peripheral area after 14 days of lens wear by FD-OCT. Previous studies focused mainly on corneal epithelial thickness of a fixed point or fixed zone, but this study first monitored the characteristics of corneal epithelial redistribution on the ring surface after OK wear. Thus, this study performed more overall observation of the corneal epithelial changes.

This study found that obvious thinning appeared within 2 mm of the central epithelium at 1 day of lens wear and was the most obvious at 1 week of lens wear. The average thickness value was $45.91 \pm 2.80 \mu\text{m}$, and the average thinning amplitude was $6.13 \pm 1.67 \mu\text{m}$, which accounted for approximately $11.78\% \pm 3.21\%$ of the total epithelial thickness. There was no significant difference in epithelial thickness between 1 week and 1 mo. The epithelium did not exhibit significant changes in the paracentral area of 2-5 mm or the peripheral area of 5-6 mm. There are two reasons for this lack of a change. The base curve zone of the lenses was designed for 5.9-6.0 mm, but each individual treatment area was approximately 3-5 mm after OK wear. The OK had specific activity at the cornea, and the reverse curve zone fluctuated in the range of 5 mm in diameter. Furthermore, the treatment area was greater than just in the optical center, not coincident with the corneal center. Hence, the reverse curve location and peripheral 5-6-mm rings have

a certain degree of deviation (see Figure 2, left). Therefore, the paracentral and peripheral epithelial thickness, after reshaping, had no obvious changes at any time points in this study. Getting rid of the lens position and scope of the individual reshaping area, we performed manual analysis of the reverse curve zone epithelial thickness before and after lens wear. We found that the corneal epithelium of the reverse curve zone became obviously thickened at 1 day ($t=5.325$, $P\leq 0.001$), gradually stable at 1 week, and thickened by an average amplitude of $7.60\pm 2.05\ \mu\text{m}$ at 1 week, which accounted for approximately $14.66\%\pm 3.96\%$ of the total epithelial thickness. We speculated that the closed loop pulling of the reverse curve zone and the pressure on the central cornea of the base curve zone may also induce corneal epithelial cell migration, leading to thickening of the peripheral epithelium[17]. Hui Ding [18] and Cheah PS [19] validated this speculation with similar results in animal experiments.

The cornea changed rapidly within 1 week, and the central corneal thickness became thin after 1 day, contrary to Zhong X [20]. Because the examinations were carried out 2 hours after removal of the lenses, corneal edema associated with overnight wear and the removal effect of the lenses were avoided. The corneal thickness gradually changed and was thinner than before lens wear. The corneal paracentral thickness did not significantly change at any time point after lens wear. The corneal thickness of the reverse curve zone was increased gradually after lens wear, and compared with before lens wear, there were significant differences. This change mainly occurred at 1 week to 1 mo of lens wear, and the average thickening amplitude was $27.05\pm 3.09\ \mu\text{m}$ at 1 mo.

In this study, we examined whether corneal and epithelial thickness are synchronously changed during OK wear. Through our data analysis, we found that the corneal and epithelial thickness of the central 2-mm area was synchronously changed from 1 day to 1 week. That is, epithelial changes led to corneal morphology change within 1 week. However, the changes in epithelial thickness were less than the corneal changes after 1 week; therefore, we speculated that the central corneal stroma gradually changed from stress or lack of oxygen. The epithelial and corneal thickness of the reverse curve zone increased gradually after lens wear, and the corneal thickening amplitude was greater than that in the epithelium. Therefore, we speculated that the corneal stromal changes in the peripheral cornea may have played a leading role.

Conclusion

In summary, at the early stages of OK wear, the corneal epithelium was redistributed very quickly by the pressure of the reverse geometry lenses and the closed loop pulling of the reverse curve zone. The central epithelium thinned, while the peripheral epithelium of the reverse curve zone thickened. These regular changes of the epithelium can form a concave lens effect, which ensures uncorrected vision after removal of the lenses. Corneal stroma occurred correspondingly with changes after epithelial changes, which may have been related to the mechanical stress of the lenses and the lack of oxygen in the long-term.

Declarations

Abbreviations

OK: orthokeratology contact lenses

UCVA: uncorrected visual acuity

Ethics approval and consent to participate

The research adhered to the tenets of the Declaration of Helsinki and was approved by the ethics committee of the Shandong Eye Hospital. All the patients and patients' guardians were adequately informed about the study and the guardians signed a consent form. It is available for review by the Editor of this journal if necessary.

Consent for publication

Details, images, or videos reported within the manuscript are consented for publication.

Availability of data and materials

The data analyzed during the current study are available from the corresponding author on reasonable request.

Competing interests

The authors declare that they have no competing interests.

Funding

This study was supported by Taishan Scholar Program Phase II (ts20150215), Shandong Province Key Research and Development Program (2015GGH318010). The funding organization had no role in the design or conduct of this research.

Authors' contributions

JZ was responsible for its design, collection of data, analysis and interpretation of results and wrote the first draft of the manuscript. TW participated in its design and revise of manuscript. JL helped revise of manuscript. XFL and FJL was involved in data collection. All authors have read and approved the final manuscript.

Acknowledgments The authors would like to thank Ms. Tong Liu for her editorial assistance.

References

1. Haque S, Jones L, Simpson T: **Thickness mapping of the cornea and epithelium using optical coherence tomography**. *Optometry & Vision Science Official Publication of the American Academy of Optometry* 2008, **85**(10):963-976.

2. Wang J, Fonn D, Simpson TL, Sorbara L, Kort R, Jones L: **Topographical Thickness of the Epithelium and Total Cornea after Overnight Wear of Reverse-Geometry Rigid Contact Lenses for Myopia Reduction.** *Invest Ophthalmol Vis Sci* 2003, **44**(11):4742-4746.
3. Cho P, Cheung SW, Edwards M: **The Longitudinal Orthokeratology Research in Children (LORIC) in Hong Kong: A Pilot Study on Refractive Changes and Myopic Control.** *Current Eye Research* 2005, **30**(1):71-80.
4. Chen C, Cheung SW, Cho P: **Myopia control using toric orthokeratology (TO-SEE study).** *Invest Ophthalmol Vis Sci* 2013, **54**(10):6510-6517.
5. Reinstein DZ, Gobbe M, Archer TJ, Couch D, Bloom B: **Epithelial, stromal, and corneal pachymetry changes during orthokeratology.** *Optometry & Vision Science* 2009, **86**(8):1006-1014.
6. Haque S, Fonn D, Simpson T, Jones L: **Epithelial thickness changes from the induction of myopia with CRTX RGP contact lenses.** *Investigative Ophthalmology & Visual Science* 2008, **49**(8):3345.
7. Ma XJ, Wang L, Koch DD: **Repeatability of corneal epithelial thickness measurements using Fourier-Domain Optical Coherence Tomography in normal and Post-LASIK eyes.** *Cornea* 2013, **32**(12):1544-1548.
8. Yang Y, Hong J, Deng SX, Xu J: **Age-Related Changes in Human Corneal Epithelial Thickness Measured With Anterior Segment Optical Coherence Tomography**Age-Related Changes of Corneal Epithelium by OCT. *Invest Ophthalmol Vis Sci* 2014, **55**(8):5032-5038.
9. Y Y T, J M L: **Ablation centration after active eye-tracker-assisted photorefractive keratectomy and laser in situ keratomileusis.** *Journal of Cataract & Refractive Surgery* 2000, **26**(1):28-34.
10. Lian Y, Shen M, Jiang J, Mao X, Lu P, Zhu D, Chen Q, Wang J, Lu F: **Vertical and horizontal thickness profiles of the corneal epithelium and Bowman's layer after orthokeratology.** *Investigative Ophthalmology & Visual Science* 2013, **54**(1):691-696.
11. Alharbi A, Swarbrick HA: **The effects of overnight orthokeratology lens wear on corneal thickness.** *Invest Ophthalmol Vis Sci* 2003, **44**(6):2518-2523.
12. Swarbrick HA, Wong G, O'Leary DJ: **Corneal response to orthokeratology.** *Optom Vis Sci* 1998, **75**(11):791-799.
13. RAH, Marjorie J, JACKSON, Mark J, JONES, Lisa A, MARSDEN, Harue J, BAILEY, Melissa D: **Overnight orthokeratology: Preliminary results of the Lenses and Overnight Orthokeratology (LOOK) study.** *Optom Vis Sci* 2002, **79**(9):598-605.
14. Chen R, Mao X, Jiang J, Shen M, Lian Y, Zhang B, Lu F: **The relationship between corneal biomechanics and anterior segment parameters in the early stage of orthokeratology: A pilot study.** *Medicine* 2017, **96**(19):6907.

15. Nietobona A, Gonzálezmesa A, Nietobona MP, Villacollar C, Lorentelázquez A: **Short-term effects of overnight orthokeratology on corneal cell morphology and corneal thickness.** *Cornea* 2011, **30**(6):646-654.
16. Qian Y, Xue F, Huang J, Qu X, Zhou X, Lanen-Wanek DV: **Pachymetry map of corneal epithelium in children wearing orthokeratology contact lenses.** *Current Eye Research* 2014, **39**(3):263-270.
17. Mcmonnies CW, Alharbi A, Boneham GC: **Epithelial responses to rubbing-related mechanical forces.** *Cornea* 2010, **29**(11):1223-1231.
18. Ding H, Pu A, He H, Xie RZ, Yang J, Liao A, Gao S, Zhong X: **Changes in corneal biometry and the associated histology in rhesus monkeys wearing orthokeratology contact lenses.** *Cornea* 2012, **31**(8):926-933.
19. Cheah PS, Norhani M, Bariah MA, Myint M, Lye MS, Azian AL: **Histomorphometric profile of the corneal response to short-term reverse-geometry orthokeratology lens wear in primate corneas: a pilot study.** *Cornea* 2008, **27**(4):461-470.
20. Zhong X, Chen X, Rz, Yang J, Li S, Yang X, Gong X: **Differences Between Overnight and Long-term Wear of Orthokeratology Contact Lenses in Corneal Contour, Thickness, and Cell Density.** *Cornea* 2009, **28**(3):271-279.

Tables

Table 1 UVA, diopter and corneal surface parameters on OCT pachymetry map before and after lenses wear

| Time | UCVA | diopter | Front surface (D) | Back surface (D) | total refractive power (D) | Min-max value (µm) |
|--------|------------|-------------|-------------------|------------------|----------------------------|--------------------|
| Before | 0.51±0.36 | -3.35±1.09 | 48.42±1.24 | -6.08±0.21 | 42.46±1.11 | -5.21±1.59 |
| 1d | 0.36±0.27* | -2.06±0.85* | 46.58±1.83* | -6.12±0.13 | 40.48±1.60* | -17.21±4.83* |
| 1w | 0±0.00* | -1.05±0.76* | 45.33±1.35* | -6.00±0.68 | 39.44±1.32* | -19.09±5.83* |
| 1m | 0±0.00* | -0.75±0.60* | 45.21±1.17* | -6.05±0.14 | 39.20±1.27* | -19.30±1.27* |

*Stand for compared with before lens wear, $P < 0.05$; UCVA: uncorrected visual acuity (logMAR); Min-max value: Difference between the thinnest and thickest corneal epithelial thickness within 5mm of central cornea.

Table 2 Epithelial thickness comparison in different areas before and after lenses wear (µm)

| Time | Central (2mm) | Paracentral (2-5mm) | Peripheral (5-6mm) | Reverse curve zone |
|--------|---------------|---------------------|--------------------|--------------------|
| Before | 52.04±2.35 | 51.86±2.18 | 51.81±2.02 | 51.83±2.49 |
| 1d | 49.25±2.67* | 51.47±1.86 | 52.19±1.83 | 57.62±3.01* |
| 1w | 45.91±2.80* | 49.45±2.61 | 52.38±3.73 | 59.43±3.19* |
| 1m | 47.53±3.44* | 50.56±3.13 | 52.72±3.70 | 60.22±2.75* |

* Stand for compared with before lens wear, P < 0.05

Table 3 Corneal thickness comparison in different areas before and after lenses wear (µm)

| Time | Central (2mm) | Paracentral (2-5mm) | Peripheral (5-6mm) | Reverse curve zone |
|--------|---------------|---------------------|--------------------|--------------------|
| before | 536.67±23.38 | 556.10±24.27 | 581.16±25.97 | 562.57±21.38 |
| 1d | 532.17±21.62* | 550.89±26.17 | 583.21±27.82 | 570.41±24.62* |
| 1w | 530.81±19.66* | 549.88±27.90 | 587.71±31.24 | 587.53±20.94* |
| 1m | 522.75±23.94* | 547.77±29.33 | 588.51± 27.32* | 589.62±23.47* |

* Stand for compared with before lens wear, P < 0.05

Figures

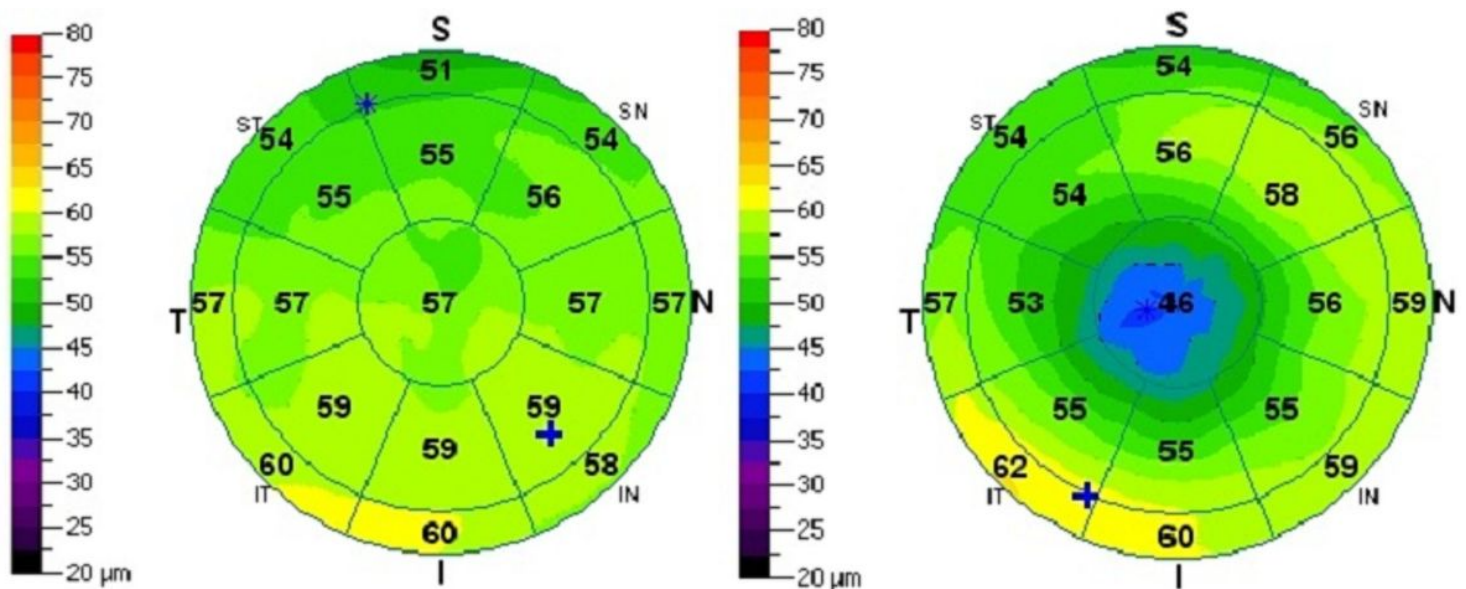


Figure 1

Corneal epithelium OCT before and after 1-month of lens wear. The thickness of the central epithelium was thinner, with a thickened circular area around it.

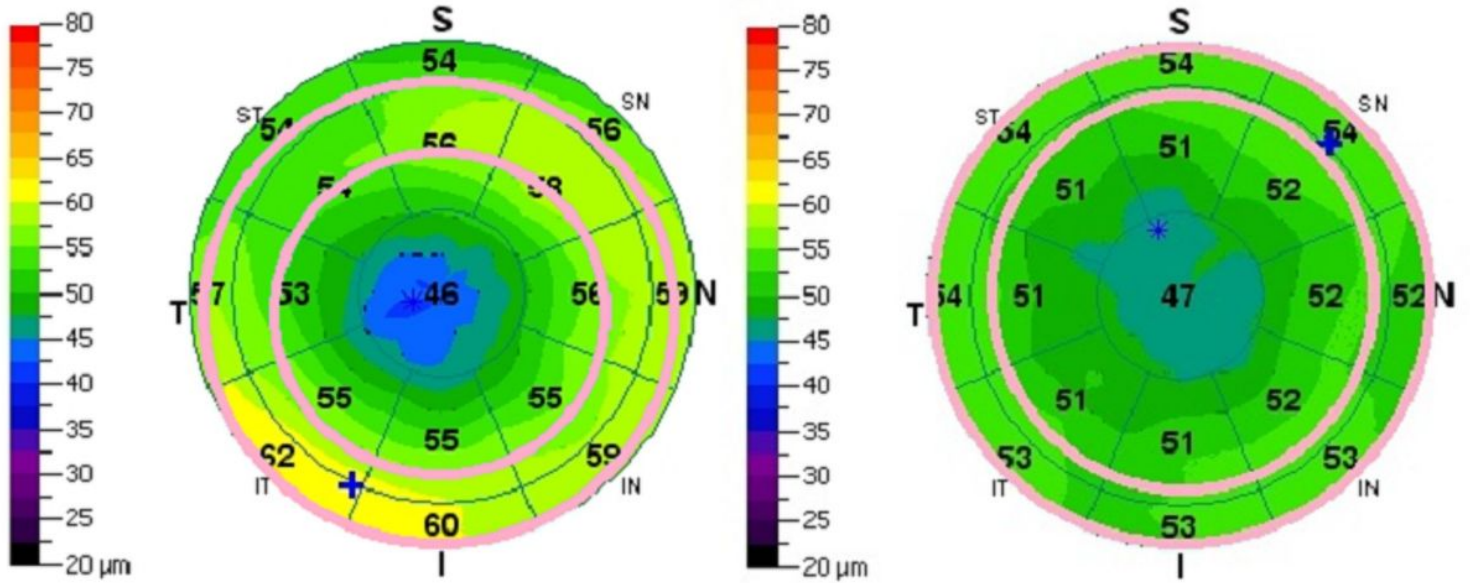


Figure 2

The reverse curve zone on the corneal topographic map was marked using pink color line.

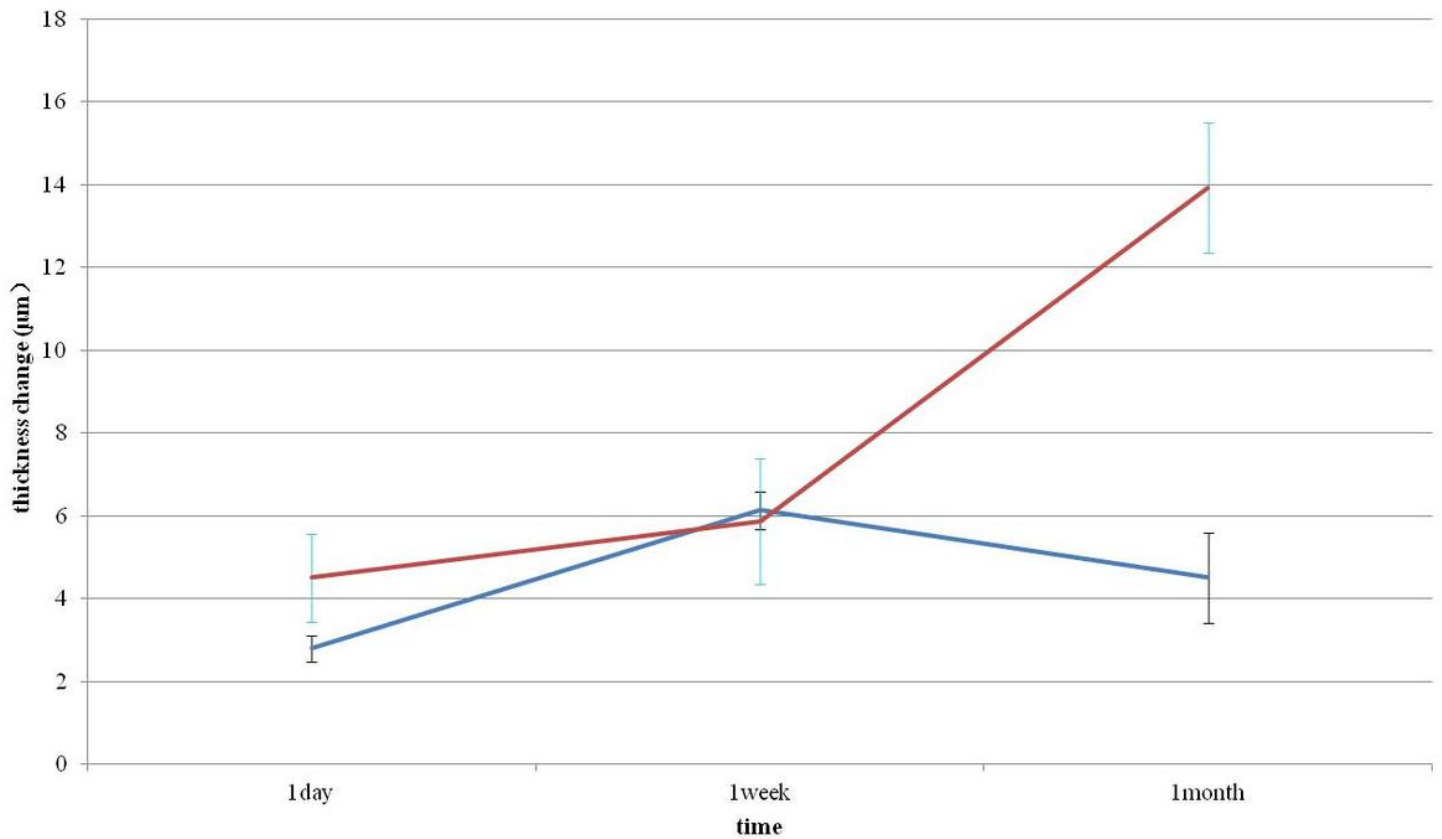


Figure 3

Central epithelial and corneal thickness change line chart at different time. The vertical coordinates represent the changes of corneal epithelium or corneal thickness; the horizontal coordinates represent different time points. The blue curve represents the trend of corneal epithelial thickness, while the red curve represents the change in corneal thickness. The changes in central epithelial thickness were basically equivalent to the corneal thickness changes at 1 week of lenses wear. The corneal epithelial thinning range was less than the corneal thickness at 1 month of lenses wear.