

Exploration of the Clinical Effect of Modified Peroneal Nerve Block in Foot Operation Under the Plane of the Ankle joint: A Non-Randomized Clinical Feasibility Observational Study.

ya tuo

The Second Affiliated Hospital of Inner Mongolia Medical University <https://orcid.org/0000-0001-9684-6753>

XUEQIANG FU (✉ fuxueqiang333@126.com)

The Second Affiliated 8 Hospital of Inner Mongolia Medical University <https://orcid.org/0000-0002-3273-1700>

YI QIU

The Second Affiliated Hospital of Inner Mongolia Medical University

XIAODONG WANG

The Second Affiliated Hospital of Inner Mongolia Medical University

SHENGJUAN YAN

The Second Affiliated Hospital of Inner Mongolia Medical University

YONGQIAN HU

The Second Affiliated Hospital of Inner Mongolia Medical University

YANRU GONG

The Second Affiliated Hospital of Inner Mongolia Medical University

Research article

Keywords: peroneal nerve block, foot operation, ultrasound guidance

Posted Date: November 9th, 2020

DOI: <https://doi.org/10.21203/rs.3.rs-102429/v1>

License:   This work is licensed under a Creative Commons Attribution 4.0 International License.

[Read Full License](#)

1 **Title page**

2 **Exploration of the clinical effect of modified peroneal nerve block in foot operation under the plane**
3 **of the ankle joint : a non-randomized clinical feasibility observational study.**

4

5 Ya Tuo ,517720709@qq.com the Department of Anesthesiology, The Second Affiliated Hospital of Inner
6 Mongolia Medical University. No.1 Yingfang Street, Huimin District, Hohhto,010030, Inner Mongolia,
7 China.

8 XueQiang Fu, fuxueqiang333@126.com the Department of Anesthesiology, The Second Affiliated
9 Hospital of Inner Mongolia Medical University. No.1 Yingfang Street, Huimin District, Hohhto,010030,
10 Inner Mongolia, China.

11

12 Yi Qiu, qiuyi003@163.com the Department of Anesthesiology, The Second Affiliated Hospital of Inner
13 Mongolia Medical University. No.1 Yingfang Street, Huimin District, Hohhto,010030, Inner Mongolia,
14 China.

15

16 XiaoDong Wang, 59203615@qq.com the Department of Anesthesiology, The Second Affiliated Hospital
17 of Inner Mongolia Medical University. No.1 Yingfang Street, Huimin District, Hohhto,010030, Inner
18 Mongolia, China.

19

20 ShengJuan Yan, 55708725@qq.com the Department of Anesthesiology, The Second Affiliated Hospital
21 of Inner Mongolia Medical University. No.1 Yingfang Street, Huimin District, Hohhto,010030, Inner
22 Mongolia, China.

23

24 YongQiang Hu, hzrohalekles@yeah.net the Department of Anesthesiology, The Second Affiliated
25 Hospital of Inner Mongolia Medical University. No.1 Yingfang Street, Huimin District, Hohhto,010030,
26 Inner Mongolia, China.

27

28 YanRu Gong, 461492747@qq.com the Department of Anesthesiology, The Second Affiliated Hospital of
29 Inner Mongolia Medical University. No.1 Yingfang Street, Huimin District, Hohhto,010030, Inner
30 Mongolia, China.

31 Correspondence to XueQiang Fu.

32 **Exploration of the clinical effect of modified peroneal nerve block in foot operation under the plane**
33 **of the ankle joint: a non-randomized clinical feasibility observational study.**

34 **【Abstract】 Background** This study was aimed at exploring the clinical effect of a modified dorsal
35 peroneal nerve block in foot operation under the ankle plane. **Methods** The study was observational
36 study, thirty patients ($n=30$) were observed with single-center and non-randomized. The patients were
37 treated with an ankle nerve block (including the posterior tibial nerve, superficial peroneal nerve,
38 saphenous nerve, and sural nerve block in the plane of the ankle) and a deep peroneal nerve block (7.5
39 mg/ml). The primary outcomes were intraoperative visual analogue scale score (0-10 points), numeric
40 rating scale score (0-10 points), and Neuropen score (0-2 points). The secondary outcomes were
41 postoperative pain VAS (visual analogue scale) and NRS(numeric rating scale scores) (0-10). Histograms
42 and normal probability QQ plots were used to test the distribution of normality. **Results** We analyzed
43 the data of 30 patients. It was found that after 20 min of ankle block and deep peroneal nerve block, 23
44 patients achieved a perfect block effect (VAS and Neuropen scores = 0), and the operation was
45 performed smoothly. Six patients experienced slight pain (VAS: ≤ 3 , Neuropen score = 1). An
46 intravenous sedative drip (dexmedetomidine 4 $\mu\text{g/ml}$, 1 $\mu\text{g/kg}$ dexmedetomidine hydrochloride
47 injection 2 ml:0.2 g; Jiangsu Nhwa Pharmaceutical Co., Ltd., China) was used. The block failed in one
48 patient, and the operation was performed under general anesthesia with a laryngeal mask in this
49 patient. **Conclusions** The modified deep peroneal nerve block combined with an ankle nerve block can
50 meet the anesthesia needs for foot surgery under the ankle plane. However, due to the limited number
51 of patients evaluated, it is difficult to accurately predict the effect and a large degree of uncertainty
52 exists regarding these findings. **Trial registration** This study had been registered
53 at <http://www.chictr.org.cn/index.aspx> with No. ChiCTR2000037880 on Sep 3, 2020. It was a
54 retrospectively registered.

55 **Keywords**

56 peroneal nerve block, foot operation, ultrasound guidance

57 **Introduction**

58 The most common types of foot surgery under the plane are hallux valgus osteotomy, high arch
59 osteotomy, fixation for foot fracture, as well as surgery for common foot trauma. Foot and ankle nerve
60 blocks are effective ways of ensuring anesthesia and analgesia ^[1]. The distribution of the foot nerves is
61 not complicated. However, the nerves in the foot are often accompanied by blood vessels and the
62 sheath of each nerve and vessel, which could easily be damaged due to vascular compression injury.
63 The innervation of the foot under the plane of the foot and ankle includes the tibial, superficial
64 peroneal, saphenous, sural, and deep peroneal nerves. The block point of the tibial meridian in the foot
65 and ankle is located in the middle of the line between the Achilles tendon and the medial malleolus,
66 which is in the ankle canal, and the superficial peroneal nerve. The deep peroneal nerve and dorsalis
67 pedis artery coexist in a narrow space in the anterior part of the ankle ^[2].

68 Foot operations can be performed by blocking the foot nerves through the ankle. The analgesic effect
69 after foot operation is similar to that achieved with the femoral nerve and sciatic nerve block, while
70 patient comfort is increased because a nerve block at the far end of the limb can make the movement
71 of the affected limb more convenient. Foot and ankle nerve blocks are not rare; however, they are often
72 associated with serious complications. An important clinical consideration is the narrow gap at the
73 block site, because of which it is easy to cause local nerve injury or even ischemic limb necrosis after
74 drug injection. This complication is more likely to occur when the deep peroneal nerve is blocked. Some
75 studies have shown that blocking the deep peroneal nerve in the front of the foot and ankle can cause
76 foot limb necrosis due to compression of the dorsal foot artery ^[3-4]. Therefore, the application of a foot

77 nerve block for ankle operations is limited.

78 A cadaver study found that the deep peroneal nerve divides into internal and external terminal
79 branches at the foot and ankle, from the medial terminal to the far dorsum of the foot, and the internal
80 terminal branch is distributed on the dorsum skin opposite to the first and second toes ^[5-6]. Only this
81 branch is the sensory branch in foot operations under the plane of the foot and ankle. Therefore, we
82 attempted to block the medial terminal branch of the deep peroneal nerve at the dorsum of the foot,
83 which could also block the innervation of the deep peroneal nerve in the sensory area of the foot.
84 There are two reasons for choosing such a block method: (1) The requirement of muscle relaxation in
85 foot operation is low, and the block can meet the requirements of the operation, and (2) improved
86 deep peroneal nerve block could reduce the overall risk associated with an ankle nerve block. Ankle
87 nerve block for patients undergoing foot surgery afforded greater postoperative comfort.

88 **Methods**

89 **Patients and design**

90 This was a single-center, non-randomized clinical feasibility observational study in The second affiliated
91 hospital of Inner Mongolia Medical University. This study had been registered
92 at <http://www.chictr.org.cn/index.aspx> with No. ChiCTR2000037880 on Sep 3, 2020. It was conducted
93 according to the principles of good clinical practice.
94 Ethical approval for this study (Ethical Committee NO.Y K D2019192) was provided by the Ethical
95 Committee of Inner Mongolia Medical University. Hohhot, Inner Mongolia, China(Prof GuangMing Niu)
96 on 4 January 2019.

97 We selected appropriate patients for foot surgery. Written informed consent was obtained from all
98 patients prior to their inclusion in the study.

99 From January 2019 to June 2019, we screened patients who had undergone foot surgery under the
100 ankle plane for inclusion in the study. Thirty patients were included (17 men and 13 women, age range:
101 18-60 years, weight: 45-90 kg, physical status classification: ASA(American Society of Anesthesiologists
102 grade) I-II. Thirteen patients were treated with hallux valgus osteotomy, six patients were treated by
103 removal of internal fixation, and 11 patients were treated for fracture of the toes. The exclusion criteria
104 were as follows: pregnancy, diabetes mellitus, hypoesthesia of the lower limbs, daily use of opioids, or
105 allergy to block drugs.

106 All patients were treated with four nerve blocks (posterior tibial nerve, superficial peroneal nerve,
107 saphenous nerve, and sural nerve) (Figure 1) and modified deep peroneal nerve block (Figure 2). After
108 nerve block administration under ultrasound guidance, the operation was completed. In patients with a
109 visual analog scale (VAS) and numeric rating scale(NRS) score of ≥ 3 for pain, general anesthesia was
110 administered using a laryngeal mask.

111 **Statistical methods**

112 SAS 9.3 was used for statistical analysis. Histograms and normal probability QQ plots were used to test
113 the distribution of normality. The measurement data that showed normal distribution are described as
114 mean values (standard deviation and 95% confidence interval). Count data that do not conform to
115 normal distribution are described as median values (interquartile spacing).

116 **Anesthesia and surgery**

117 Blood pressure, peripheral capillary oxygen saturation (SpO₂), and electrocardiography findings were
118 routinely monitored. Under ultrasound guidance, the nerve block was performed with a No. 22
119 puncture needle (PAJUNK GmbH Medizintechnologie Mod: 001156-71 NanoLine, Germany) (Figures 3
120 and 4). The drug used for the block was ropivacaine (7.5 mg/ml, 0.9% NS dilution) (Naropin, ropivacaine
121 hydrochloride injection, 10 ml:100 mg; AstraZeneca). The drug doses used for the block in the foot and
122 ankle were 3 ml each for the posterior tibial and gastrocnemius nerves and 4 ml each for the superficial
123 peroneal and saphenous nerves. The dose was 3 ml for the modified deep peroneal nerve in the
124 dorsum of the foot. To reduce the deviation, all blocking operations were performed by the same
125 anesthesiologist and we used the same 13-5 MHz linear sensor (Ultrasound System Mod: M-Turbo,
126 USA). The patients were administered midazolam 2 mg (midazolam injection 2 ml:2 mg; YiChang
127 Human Well Pharmaceutical Co., Ltd., China) and dezocine 5 mg (dezocine injection 1 ml:5 mg; Yangtze
128 River Jiangsu Nhwa Pharmaceutical Co., Ltd., China) through a vein 30 min before the operation. The
129 same type of operation was performed by the same group of orthopedic doctors. All operations were
130 routine; no modified procedures or complex procedures were used. During the operation, a tourniquet
131 was tied to the patient's ankle or not used.

132 **Regional block and success assessment**

133 We defined the end time of the drug injection as the beginning of the observation period. Before the
134 operation, we measured the pain score every 5 minutes to achieve the ideal analgesic effect (VAS = 0,
135 NRS = 0, neuron open = 0). After the operation, we measured the pain score every 3 hours until the foot
136 sensation returned to normal. The proportion of patients with pain scores (VAS, NRs, Neuropen) of 3 or

137 more was determined. The time of pain score of the foot area of patients with the block from injection
138 to VAS < 3, NRS < 3, and the time of foot sensory recovery of all patients were recorded.
139 VAS, NRS, and Neuropen scores were assessed 20 minutes after anesthesia. The cold test (5°C) was
140 performed on the dorsolateral skin of the opposite side of the 1.2 phalanx of the foot, which was
141 innervated by the medial branch of the deep peroneal nerve. A cold bottle was used to evaluate
142 sensory function, and the pain sensation in this area was evaluated by Neuropen. The sensory score
143 (normal sensation = 2, reduced sensation = 1, no sensation = 0), VAS pain score (0 = no pain, 10 =
144 severe pain), NRS pain score (0 = no pain, 10 = the most severe pain imaginable) after the block were
145 measured and recorded, and the posterior tibial nerve, superficial peroneal nerve were detected using
146 the same approach that was used for assessing the sensory function of the sural and saphenous nerves.
147 After the VAS, NRS, and Neuropen scores of the foot reached 0, the operation began, and the scores
148 were monitored until the end of the observation period. After the operation, we transferred the patient
149 to the resuscitation room. Within 12 hours after the operation, the patient received an injection of 120
150 mg flurbiprofen axetil (flurbiprofen axetil injection 5 ml:50 mg; Beijing Tide Pharmaceutical Co., Ltd.,
151 China), followed by 400 mg × 3 ibuprofen (ibuprofen sustained-release capsules 0.3 g SK & F) on the
152 second day after the operation for oral analgesia. During the observation period, the patients did not
153 receive opioids and glucocorticoids.

154 **Results**

155 Primary results: after 20 minutes of block, 23 patients achieved the ideal analgesic effect (VAS = 0, NRS
156 = 0 and Neuropen = 0), and the operation proceeded smoothly; ② 6 patients experienced slight pain

157 (VAS, NRS \leq 3, Neuropen = 1), and intravenous sedation drugs (4 μ g/kg/h dexmedetomidine) were used;
158 the ideal analgesic effect (VAS = 0, NRS = 0 and Neuropen = 0) was achieved 10 min later, and the
159 operation was carried out smoothly. ③ The block failed in one patient, who then received general
160 anesthesia under laryngeal mask. ④ After 16.38 min (95% CI = 15.04-17.71), the VAS decreased to 0;
161 after 17.41 min (95% CI = 15.68-19.15), the NRS decreased to 0; and after 16.38 min (95% CI =
162 15.04-17.71), the Neuropen score was 0, and the patient experienced no feeling.

163 Secondary results: ① after 1184.48 min (95% CI = 1134.31-1234.65), all patients began to recover. ②
164 After 1358.28 min (95% CI = 1324.47-1392.09), all patients felt normal.

165 Results: In the foot operation under the plane of the foot and ankle, a nerve block of the foot and ankle
166 can complete the operation, but after the improvement, the block of the deep peroneal nerve was
167 changed to a block of the medial branch of the deep peroneal nerve of the foot back. The procedure
168 was successful in 23 of the 30 patients who were assessed in this clinical observational study, yielding a
169 success rate of 77%. Among the seven cases in which a complete block could not be achieved with
170 intravenous drugs, the operation was completed in six, while the procedure failed in the seventh case.
171 As for the onset time of anesthetic drugs, an NRS score of 0 appeared slightly later than VAS and
172 Neuropen scores of 0. We believe that this may be due to the discomfort caused by some deep
173 sensation, the small number of cases, and because the scores cannot distinguish between pain and
174 discomfort. Of course, the overall findings of this clinical observational study suggest that the improved
175 deep peroneal nerve block causes no major change in the whole foot and ankle block and shows
176 positive effects in reducing complications and promoting foot and ankle block.

177 The average time of recovery was 22 hours after the operation. With postoperative oral medication,
178 patient discomfort was greatly relieved. More importantly, patients' leg movement after the operation
179 was normal, and they reported substantial relief from discomfort.

180 **Discussion**

181 To our knowledge, this is the first clinical observational study to evaluate the effect of deep peroneal
182 nerve block via the dorsalis pedis in foot surgery. We found that this block shows no significant
183 difference from the traditional anterior tibial block. Before designing this prospective clinical
184 observational study, we assessed a large amount of anatomical and clinical anesthesiologic data to
185 determine if this improved block could achieve the ideal anesthesia effect. However, due to the small
186 sample size, although this report presents positive results, there are many uncertain and negative
187 aspects to be considered, which should be the main topics for future research on this block. Some of
188 the debatable issues related to the results are outlined below.

189 First, some experts suggest that the anesthesia effect of deep peroneal nerve innervation can be solved
190 by skin infiltration anesthesia, which can not only reduce the risk of acupuncture but also make
191 anesthesia simpler. However, our literature review suggested that this is not feasible for the following
192 reasons: (1) skin infiltration anesthesia cannot guarantee an ideal anesthesia effect and anesthesia time,
193 while injection of the drug solution into the peripheral nerve can ensure an ideal anesthesia effect [7].

194 Although an improved block is still a traumatic operation, it is essential to ensure the appropriate
195 anesthesia effect in patients. ② In the three types of regional evaluations, the dynamic pain score
196 reached the ideal value slightly later than the static score. The anatomical literature suggests that the

197 probability of variations in nerve branches is very high^[5,6], and the sensory nerves that may dominate
198 the region will also be distributed in the deep facial block, so the effect of a block at the nerve branches
199 is higher than that of skin infiltration.

200 For foot surgery under the sole ankle plane, such as procedures for hallux valgus, phalange fracture,
201 foot trauma, etc., there is almost no requirement for muscle relaxation at the operation site, so the
202 nerve block only needs to ensure disappearance of sensation to allow the operation. Such anesthesia
203 can be completed through the ankle joint area block, and the traditional ankle joint block mode has
204 been gradually abandoned because of the risk of compressing the nerve and blood vessels, However, in
205 recent years, ultrasound-guided nerve blocks have greatly reduced the risks associated with such blocks.
206 Ultrasound can be used to conduct more detailed operations involving nerve blocks ^[2]. In this clinical
207 observational study, 23 of our 30 patients achieved the ideal anesthesia effect within 20 minutes for
208 surgery; six patients underwent smooth operations after 10 minutes of auxiliary sedative drugs; and the
209 protocol failed in only one case. Thus, the improved block does not influence the anesthesia effect of
210 the whole block, and the position of the new block point can avoid the narrow internal drug injection
211 space and reduce the risk of compression, yielding a positive effect.

212 The ankle regional block has minimal effects on lower limb movement and the patients' systemic
213 circulation and cardiovascular system ^[8]. It is suitable for daytime operations and short procedures for
214 both feet. The postoperative complications are fewer; safety is greatly improved; the duration of
215 hospitalization is reduced; and a lot of medical resources are saved ^[9]. This is especially applicable to
216 underdeveloped countries and regions with underdeveloped economies and limited medical resources,

217 since this technique can reduce the burden of patients and hospitals in such cases ^[10]. Improvements in
218 the deep peroneal nerve block, which has the highest risk of complications among ankle blocks, can
219 promote the application of ankle blocks in such operations.

220 The sensory branch of the deep peroneal nerve is located at the intersection of the proximal phalanx of
221 the second toe and the proximal phalanx of the third toe, where the deep peroneal nerve block does
222 not show an anesthetic effect, thereby reducing the risk of injury of the deep peroneal nerve-muscle
223 branch and the risk of vascular compression due to the passage of the artery to the sole.

224 In the current clinical observational study, we assessed only a small number of samples without a
225 control group or randomization, which limited the generalizability of the findings. We expect to improve
226 on these aspects in subsequent study designs. The main purpose of our clinical observational study was
227 to provide some information for the optimal design of a randomized controlled double-blind
228 experiment that could meet ethical and clinical requirements with the improved technique. Thus, the
229 application of this technique has great clinical significance.

230 For the six patients who required sedative drugs and the one patient for whom the technique was a
231 failure, we concluded that the 20-min period was insufficient. Thus, the starting time of the operation
232 should be adjusted to achieve the purpose of completing the operation only through the block. In the
233 follow-up clinical observational studies, we hope to assess the psychological and physiological factors of
234 the patients and adjust the type and measurement of preoperative medication to ensure the safety of
235 patients.

236 In summary, this improved technique can provide the same blocking effect as the original technique,

237 providing much supports for a follow-up study. However, there is no clinical data to support whether
238 the novel block can completely replace the original block. This report presents a mostly positive trend,
239 which is significant for our hypothesis of providing patients with an effective and safe new block point.

240 **Conclusion**

241 The modified deep peroneal nerve block combined with the ankle nerve block can meet the anesthesia
242 needs of foot surgery under the ankle plane. However, considering the limited number of observation
243 samples, its effect is not completely predictable, and the uncertainty ratio in the existing observation
244 patients is still large, necessitating further data to support these findings.

245 **Abbreviations**

246 VAS: visual analogue scale

247 NRS: numeric rating scale scores

248 ASA: American Society of Anesthesiologists grade

249

250

251

252

253

254

255

256

257

258

259

260

261

262

263

264

265

266

267

268

269

270

271

272

273

274

275

276

References

277

278

279

280

281

282

283

284

285

286

287

288

289

290

291

292

293

294

295

296

297

298

299

300

301

302

1. Marty P, Rontes O, Chassery C et al. Perineural Versus Systemic Dexamethasone in Front-Foot Surgery Under Ankle Block: A Randomized Double-Blind Study. *Regional anesthesia and pain medicine* 2018; **43**:732-737.
2. Bhoi S, Sinha TP, Rodhe M, et al. Feasibility and safety of ultrasound-guided nerve block for management of limb injuries by emergency care physicians. *Journal of Emergencies, Trauma, and Shock* 2012; **5**: 28-32.
3. Hromádka R, Barták V, Popelka S, et al. Ankle block implemented through two skin punctures. *Foot & ankle international* 2010; **31**:619-23.
4. Madsen MH, Christiansen CB, Rothe C et al. Local Anesthetic Injection Speed and Common Peroneal Nerve Block Duration: A Randomized Controlled Trial in Healthy Volunteers. *Regional anesthesia and pain medicine* 2018; **43**:467-473
5. Kahn RL, Ellis SJ, Cheng J et al. The Incidence of Complications Is Low Following Foot and Ankle Surgery for Which Peripheral Nerve Blocks Are Used for Postoperative Pain Management. *HSS journal: the musculoskeletal journal of Hospital for Special Surgery* 2018; **14**:134-142.
6. Lu Hui, Chen LiFeng, Jiang Shuai S et al. A rapidly progressive foot drop caused by the posttraumatic Intra-neural ganglion cyst of the deep peroneal nerve. *BMC musculoskeletal disorders* 2018; **19**:298.
7. Kim NY, Lee KY, Bai SJ et al. Comparison of the effects of remifentanyl-based general anesthesia and popliteal nerve block on postoperative pain and hemodynamic stability in diabetic patients undergoing distal foot amputation: A retrospective observational study [J]. *Medicine* 2016;**95**: e4302.
8. Kang C, Lee GS, Kim SB et al. Comparison of postoperative pain control methods after bony surgery in the foot and ankle. *Foot Ankle Surg* 2018; **24**: 521-524.
9. Vicchio N, Mossetti V, Bajocco C. Regional anesthesia: not only pain control. *Paediatr Anaesth* 2012;**22**: 725-6.
10. Melnyk V, Ibinson JW, Kentor ML et al. Updated Retrospective Single-Center Comparative Analysis of Peripheral Nerve Block Complications Using Landmark Peripheral Nerve Stimulation Versus

303 Ultrasound Guidance as a Primary Means of Nerve Localization. *J Ultrasound Med* 2018;**37**:
304 2477-2488.

305

306

Declarations

307 **Ethic approval and consent to participate**

308 Our study was approved by Medical ethics committee of Inner Mongolia Medical University. After
309 obtaining approval [No. Y K D2019192], we collected patient data from the patients record system at
310 The Second Affiliated Hospital of Inner Mongolia Medical University.

311 **Consent for publication**

312 Consent for publication was obtained from all participants.

313 **Availability of data and materials**

314 The datasets used and/or analysed during the current study available from the corresponding author
315 on reasonable request.

316 **Competing interests**

317 The authors declare that they have no conflict of interests.

318 **Authors' contributions**

319 Ya Tuo, XueQiang Fu and Yi Qiu contributed equally to this work.

320 **Affiliations**

321 Department of Anesthesiology, The Second Affiliated Hospital of Inner Mongolia Medical University

322 contributions

323 YT: original draft writing, conceptualization, and draft writing. XQF: Conceptualization and original draft
324 writing. YQ: Original draft writing, conceptualization, and draft writing. XDW: Statistical analysis. SJY:
325 Data collection. YRG: Data collection. YQH drew figures 1 and 2 and copyrighted them. All authors read

326 and approved the final manuscript.

327 Correspondence to XueQiang Fu

328 **Funding**

329 There was no funding for this manuscript.

330 **Acknowledgements**

331 Not applicable

332

333

334

335

336

337

338

Figures

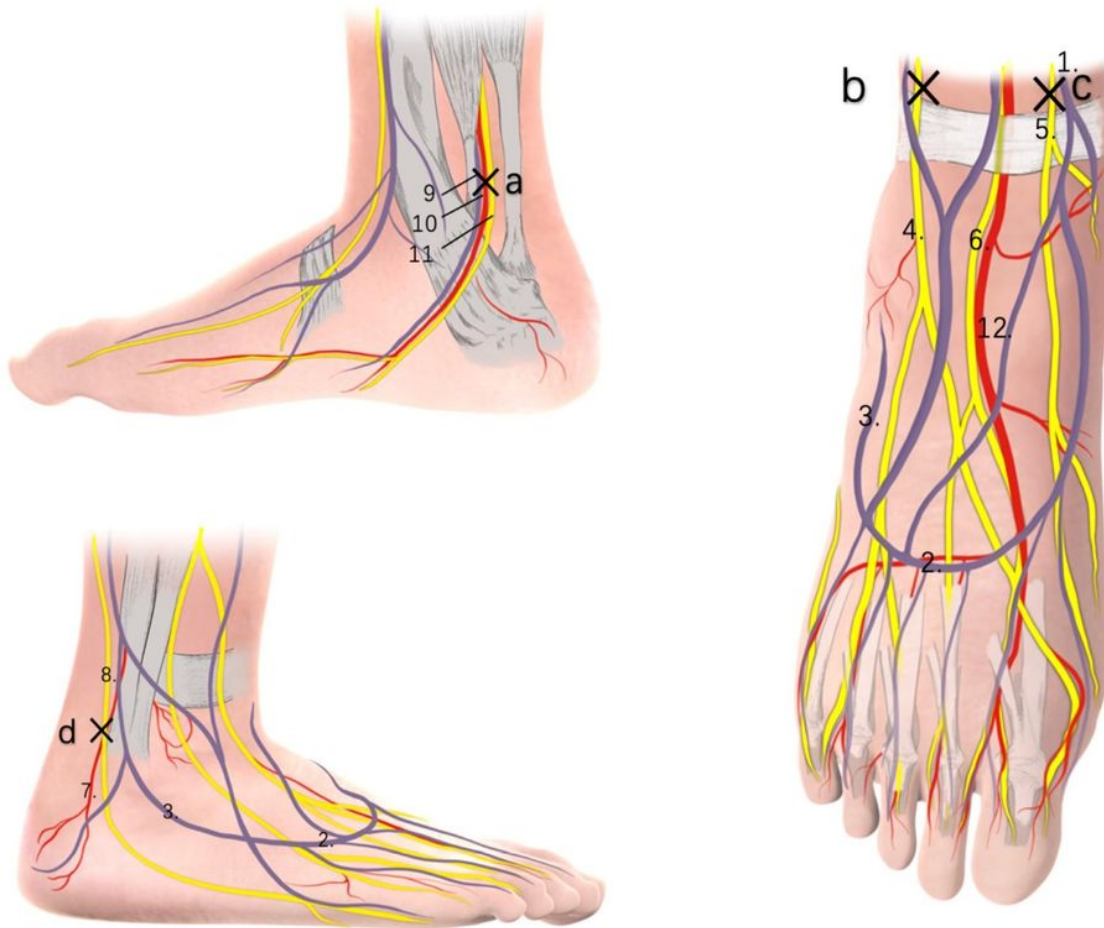


Figure 1

1. Great saphenous vein 2. Dorsal vein arch of foot 3. Small saphenous vein 4. Superficial peroneal nerve 5. Saphenous nerve 6. Deep peroneal nerve 7. Peroneal artery 8. Sural nerve 9. Posterior tibial vein 10. Posterior tibial artery 11. Posterior tibial nerve 12. Dorsal foot artery a. Posttibal nerve block point b. superficial peroneal nerve block point c. saphenous nerve block point d. sural nerve block point

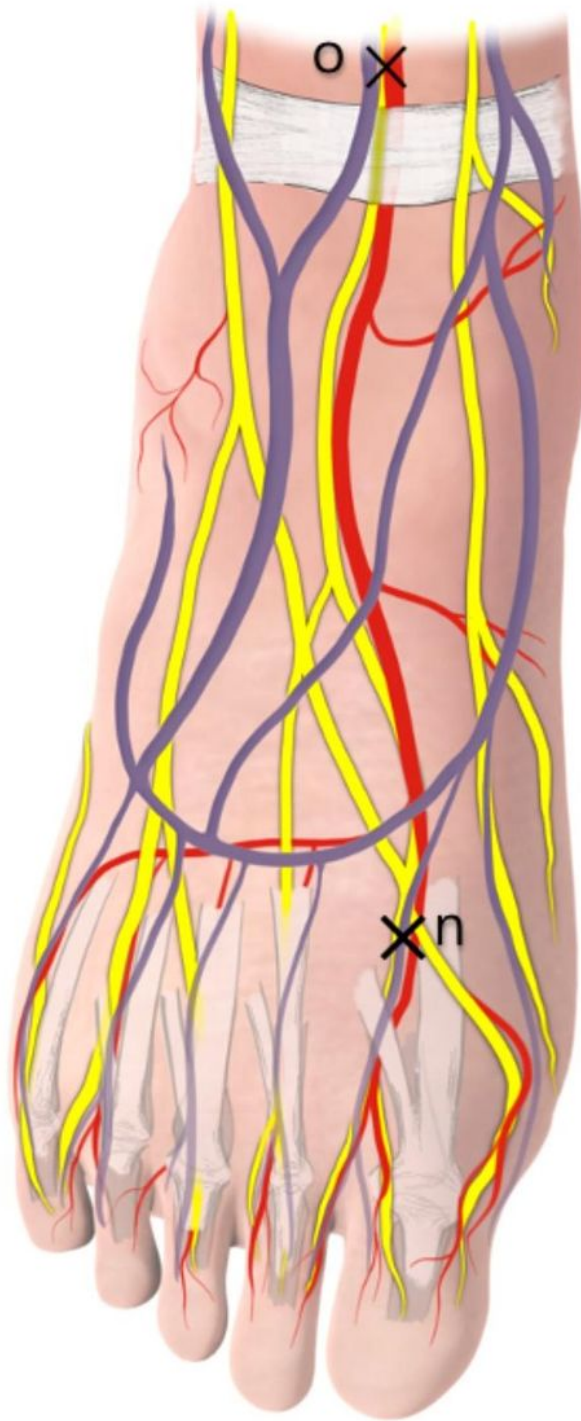


Figure 2

o. Traditional deep peroneal nerve block point: above the upper support band of extensor muscle, accompanied by dorsalis pedis artery. n. Modified deep peroneal nerve block point: at the intersection of the proximal phalanx and the proximal phalanx of the second toe, the probe is placed perpendicular to the foot surface

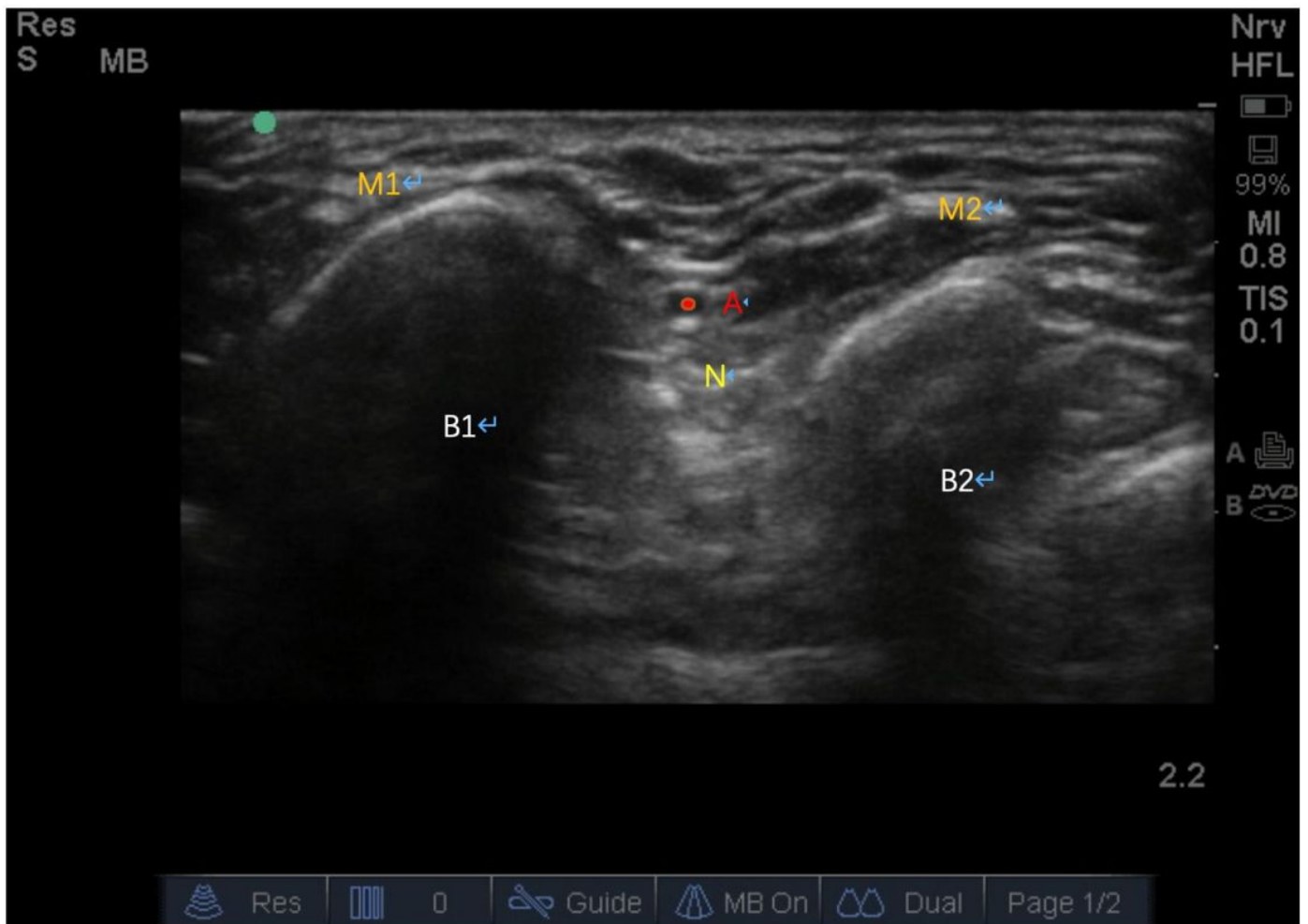


Figure 3

B1: second phalange B2: first phalange B3: third phalange M1: extensor digitorum dorsalis M2: extensor digitorum longus A: Dorsalis pedis artery N: Deep peroneal nerve Under ultrasound, the proximal phalanx of the second toe and the proximal phalanx of the third toe were found, the extensor digitorum longus was covered above the first metatarsal bone, the extensor digitorum dorsalis was covered above the second metatarsal bone, the dorsal muscle of the first interosseous bone and the tendon of the short toe were covered on the inside, the dorsal artery of the foot was found in the space between the first metatarsal bone and the second metatarsal bone. The dorsal artery of the foot could be determined by color Doppler method, and the deep peroneal nerve was around the dorsal artery of the foot.

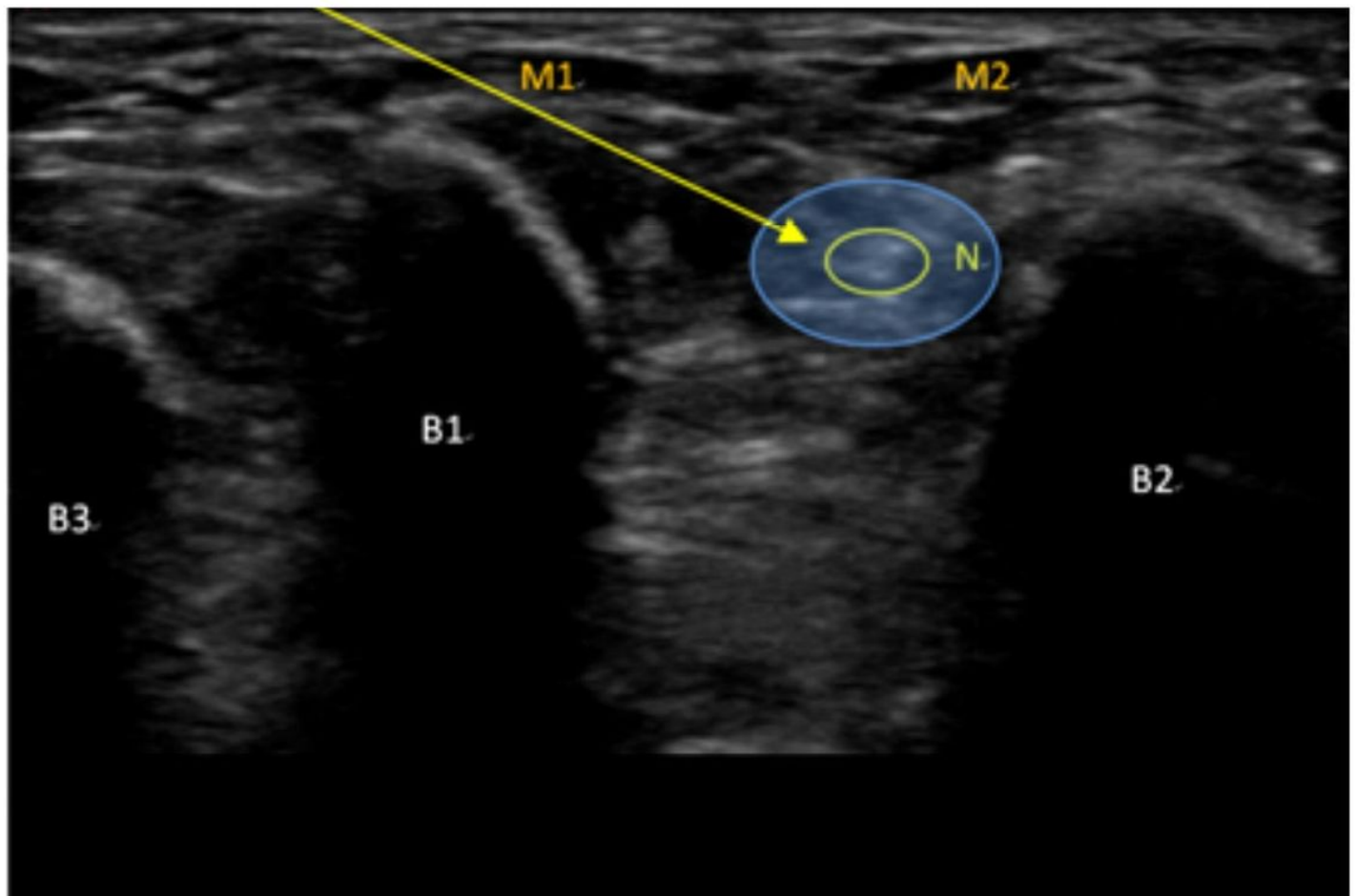


Figure 4

The ultrasound probe slides to the toe tip, and it can be seen that the proximal phalanges of the third toe and the proximal phalanges of the second toe, as well as the muscles and tendons attached to them, have no change compared with the position shown in Fig. 3. Only the dorsal foot artery disappears gradually. This is the place where the terminal branch of the deep peroneal nerve is blocked. The drug is injected around the nerve to complete the block.

Supplementary Files

This is a list of supplementary files associated with this preprint. Click to download.

- [STROBEchecklistcrosssectional.doc](#)