

# Perianal and Perineal Rhabdomyosarcomas - A Retrospective Multicenter Study of 35 Cases

**Yaoyu Guo**

Sixth Affiliated Hospital of Sun Yat-sen University <https://orcid.org/0000-0003-0793-3615>

**Bang Hu**

Sun Yat-sen University Sixth Affiliated Hospital

**Dandan Huang**

Sun Yat-sen University Sixth Affiliated Hospital

**Xinhua Wang**

Sun Yat-sen University Sixth Affiliated Hospital

**Juan Li**

Sun Yat-sen University Sixth Affiliated Hospital

**Di Zhang**

Sun Yat-sen University Sixth Affiliated Hospital

**Xueying Li**

Sun Yat-sen University Cancer Center

**Gong Chen**

Sun Yat-sen University Cancer Center

**Donglin Ren** (✉ [rendl11@163.com](mailto:rendl11@163.com))

Sun Yat-sen University <https://orcid.org/0000-0001-5599-8654>

---

## Research article

**Keywords:** Perianal, Perineal, Abscess, Rhabdomyosarcoma

**Posted Date:** November 6th, 2020

**DOI:** <https://doi.org/10.21203/rs.3.rs-101463/v1>

**License:** © ⓘ This work is licensed under a Creative Commons Attribution 4.0 International License. [Read Full License](#)

---

**Version of Record:** A version of this preprint was published on January 30th, 2021. See the published version at <https://doi.org/10.1186/s12893-021-01073-x>.

# Abstract

## Background

Perianal/perineal rhabdomyosarcoma (PRMS) is rare, easy to be misdiagnosed and has poor prognosis. This study was designed to analyze the clinical, diagnostic, pathological and prognostic features of PRMS, and to explore its therapeutic modality.

## Methods

Clinical data of PRMS patients in the Sixth Affiliated Hospital and the Cancer Center of Sun Yat-sen University and related Chinese literatures published between 1987 and 2018 were described and analyzed. Chi-square test was used to test the differences between groups. The Kaplan-Meier methods were used to estimate and compare survival rates.

## Results

35 patients, 20 identified in the Chinese literatures and 15 of our center from 1997 to 2019, were included in this study. 34 cases presented as perianal mass and one presented as inguinal mass. 20 patients complained about pain and 16 cases were misdiagnosed as perianal abscess, in which pain was found related to misdiagnosis ( $p=0.05$ ). The average time from symptoms to pathological diagnosis was 3.1 months. 13 cases were categorized into IRS group III/IV and 20 cases into stages 3/4. 14 Cases were diagnosed as embryonal rhabdomyosarcoma pathologically and 9 as alveolar rhabdomyosarcoma. Five patients survived for more than two years, three of them survived for more than five years. The overall survival rates of two years and five years were 32% and 24% respectively, in which misdiagnosis contributes to poor prognosis ( $p=0.05$ ). MRI showed that PRMS was closely related to external anal sphincter in 10 cases.

## Conclusion

PRMS is easy to be misdiagnosed, which could lead to worse outcome. Patients with painful perianal mass should be evaluated to exclude PRMS. MRI shows PRMS is closely related to external anal sphincter. Comprehensive therapy including radical operation and chemotherapy is recommended.

# Background

Rhabdomyosarcoma (RMS) is a common soft tissue malignancy, but primary perianal and perineal rhabdomyosarcoma (PRMS) is extremely rare, accounting for only 2% of all RMS[1]. PRMS is easy to be misdiagnosed and mistreated and the mortality rate is relatively high. In this study, 35 Chinese patients were reviewed to clarify the clinical manifestations, imaging, pathology and prognostic features of PRMS and to explore the optimal therapeutic regimen of this disease.

## Patient eligibility

15 PRMS patients treated and followed up at the Sixth Affiliated Hospital (n=6) and the Cancer Center (n=9) of Sun Yat-sen University were reviewed in this study. The perianal region is consist of the area posterior or lateral to the anus and the perineal region is defined as the area between anus and the scrotum or labia magna. Patients with gluteal or deep pelvic primaries involving the perineum or of urogenital origin were excluded[2]. Information including patients' sex, age at first diagnosis, symptoms, preoperative tumor size, pathological type, lymph node involvement, metastasis and treatments were collected and analyzed. The staging and grouping after operation were in accordance with IRS (Intergroup Rhabdomyosarcoma Study) standard[3]. A database of medical journals published in Chinese between 1987 and September 2018 was examined and 20 patients were identified[4-19]. Adding together, 35 patients were included in this study. The Ethics Committee at the Six Affiliated Hospital approved the study.

## Statistical analysis

Spss26.0 software package was used for statistical analysis. Chi square test was used to test the differences between groups. The Kaplan-Meier method was used to assess Overall Survival, which was calculated as the time from pathological diagnosis to the point of death or the last follow-up. Survival curves among different patient subgroups were compared with the Mantel log-rank test.  $P<0.05$  was considered significant.

# Results

## Patient characteristics

Table1 summarizes the data of the patients treated in our center and clinical characteristics of all 35 patients were listed in table2. The study group comprised 10 males and 25 females ranging in age form 1 to 56 years. The most common presenting symptom was perianal/perineal mass, only one patient complained about inguinal mass. Other symptoms including pain, bloody stool, difficult defecation and fecal incontinence (3%) were noted. 15 patients had regional lymphatic metastasis and 5 patients had distant metastasis at the time of diagnosis. The IRS group was I in 1, II in 11, III in 8 and IV in 5 cases. The pre-treatment staging were stage-2 in 6, stage-3 in 15 and stage-4 in 5 cases.

## Imaging

15 patients treated in our center received imaging evaluation. 4 patients were examined by color Doppler ultrasound and showed hypoechoic or mix-echoic mass with unclear boundary and irregular shape. Spot blood flow signals were detected by CDFI in 3 cases and 1 has abundant blood flow signals around the mass. These patients were then subjected to ultrasound-guided biopsy and pathology showed RMS. All the 15 patients received CT/MRI scan, which showed

the average maximum diameter of tumor was 6.8cm (1.8-12.2cm). Tumor compression of internal anal sphincter and rectal mucosa was observed in 5 cases and 3 had urogenital involvement was identified in 3 cases. MRI was conducted in 10 patients and showed equal signal on T1WI (n=10) and high (n=5) or mixed (n=5) signal on T2WI in tumors. Furthermore, external anal sphincter (EAS) involvement was observed in all the 15 cases (Figure 1), including 3 having puborectalis involvement and 3 having levator ani involvement (Figure 2). Regional lymph node metastasis was found in 12 patients. 5 patients had distant metastases at the sites including bone, lung, pancreas, breast and pelvic cavity. Clinical stages were determined based on imaging evaluation: 5 cases in stage 2, 6 in stage 3 and 4 in stage 4.

#### Pathological findings

6 of 15 cases in our 2 centers were histologically confirmed as alveolar RMS (Figure 3) and 9 were embryonal (Figure 4). Myogenin was expressed in all cases. Desmin and vimentin were positive in 5 of 5 cases. MyoD1 was positive in 3 of 4 cases. Of all the 35 patients, 14 were embryonic RMS, 9 were alveolar and 1 was pleomorphic. 11 cases have no histological reports. Desmin (+) (20/20), vimentin (+) (14/14), myogenin (+) (15/15), MyoD1 (+) (9/10) and myoglobin (+) (9/9) are reported in 20 immunohistochemistry available cases.

#### Treatments and outcomes

10 patients received surgical treatment in our center, primary surgery was performed in 3 (R0=2, Rx=1) and secondary surgery after chemotherapy was performed in 6 (R0=3, R1: n=1; Rx: n=2). Among these patients, 4 received abdominoperineal resection (APR) and 5 received local radical tumor resection (LRR). 1 patient undergone inguinal lymphadenectomy only. All 15 patients in our center received chemotherapy, including MAID (mesna, adriamycin, isocyclic amide, dacarbazine), CYVADIC (cyclophosphamide, vincristine, adriamycin, dacarbazine), CEVAIE (carboplatin, epirubicin, vincristine, dactinomycin, ifosfamide, etoposide), FOLFOX (fluorouracil, oxaliplatin, calcium folinate) and TP (cisplatin, paclitaxel) regimens. 2 patients received radiotherapy postoperatively and one preoperatively. The median survival time was 14 months (8-120 months). 9 patients died of disease progression after diagnosis (8-25 months).

Taking into account the literatures retrieved from the Chinese database, 18 of 35 received surgical treatment (APR: n=7; LRR: n=11) and 9 of them received radiotherapy or chemoradiotherapy alone. Treatment process was unknown in 8 cases. 15 patients were misdiagnosed as perianal abscess, 14 of them underwent abscessotomy and 1 was treated with intravenous antibiotics only. 1 was misdiagnosed as anal fistula with subsequent fistula resection. Pain is found to be related with misdiagnosis ( $p=0.010$ ) (Table 3). The average time interval from symptom onset to pathological diagnosis is 3.1 months (3 days to 10 months), 2.6 months for patients with misdiagnosis history (10 days to 3 months) and 3.4 months (3 days to 10 months) for those without misdiagnosis history. Median survival time was 12 months (Table 2). The 2-year and 5-year overall survival rates were 33% and 25% respectively. Kaplan Meier survival analysis showed misdiagnosis was associated with poor prognosis ( $P=0.038$ ) (Figure 5).

## Discussion

RMS is a malignant mesenchymal neoplasm that exhibits striated muscle differentiation, accounting for 5-10% of all solid tumors and 55-60% of soft tissue sarcomas in pediatric age group[20] but relatively rare in adults[21]. In this retrospective study, however, patients aged  $\geq 20$  years accounted for 51%. The most common primary sites for RMS were head/neck, extremities and genitourinary tract[22], perianal and perineum area are rare and considered unfavorable RMS sites[1, 3, 23]. RMS in adults is more likely to occur in unfavorable sites than in adolescents[24], which may explain the majority of adults in this study. In addition, female predominance is noticed in Chinese literatures (71%), similar feature was reported in a Japanese study[25], indicating regional and ethnic differences in the occurrence of this disease.

The prognosis of primary RMS in perianal and perineal area is extremely poor, prognostic factors including age, pathological type, clinical group and staging[26]. In this study, patients older than 20 years comprised 51% of all patients, 38% were classified as alveolar RMS and 52% were categorized into IRS group III-IV, which may contribute to the poor outcome. In addition, misdiagnosis rate was 45.7% in this group, which was significantly related to poor prognosis ( $P=0.038$ ).

PRMS is easy to be misdiagnosed as perianal abscess and may lead to poor prognosis, careful evaluation and differential diagnosis for suspected patients are crucial. Perianal mass is the most common manifestation of both PRMS and perianal abscess. 97% patients presented as perianal mass in this study. Perianal abscess is almost always accompanied by pain[27]. In this study, pain is found to be related with misdiagnosis ( $P=0.010$ ). When combined with infection, local redness, swelling and fever can be observed, which resembles perianal abscess and thus leads to high misdiagnosis rate[2]. It is difficult to distinguish PRMS from perianal abscess by symptoms. For firstly-diagnosed patients with painful perianal mass, paying attention to the delay of seeking health care, predisposing factors for abscess formation (immune deficiency, HIV infection, diabetic ketoacidosis and Crohn's disease) and the increasing level of lactate dehydrogenase would be helpful for differential diagnosis[2]. In addition, epidemiological characteristics can provide clues, that perianal abscesses mainly affect adults and male infants younger than 1 year[28-30], which is different from the population features of PRMS reported in literatures[25, 31, 32]. Therefore, solid or even malignant tumor, instead of perianal abscess, should be considered when the patient is a girl presented with perianal mass. Theoretically, misdiagnosis would delay the correct assessment of this disease[2]. However, correlation between misdiagnosis and the average time interval from symptom onset to pathological diagnosis was found insignificant in this study ( $P=0.712$ ). On the contrary, the average diagnosis time of misdiagnosed cases is shorter than that of cases without misdiagnosis (2.6 months vs. 3.4 months). The possible reason is that patients' complaints about pain prompted clinicians to carry out emergency abscess incision/resection, rendering an earlier acquisition of postoperative pathological results than those without pain.

Doppler ultrasound is a noninvasive, accessible and radiation-free method for preliminary examination of patients with perianal painful masses suspected as PRMS. It has unique advantages in distinguishing solid, cystic or lacunar masses, providing high specificity and sensitivity of the diagnosis of perianal abscess. Endoanal ultrasound can clarify tumor involvement of the anal canal, and thus provide clues for accurate diagnosis and following treatment[33]. 5

cases of PRMS treated in our center showed solid masses with uneven echo and rich intratumoral blood flow signal with or without clear boundary, which was consistent with the relevant reports[34-36]. 1 case was indicated perianal abscess by Doppler ultrasound, but pathological result following concomitant ultrasound-guided biopsy corrected the diagnosis, suggesting a method to further lower the risk of misdiagnosis. Endoscopic ultrasound-guided fine needle aspiration is recommended for its accuracy and minimal invasion when conducting biopsy[37].

The sonographic features of RMS are variable and nonspecific[38] and it has certain limitations on the assessment of deep-tissue lymph nodes and distant metastasis, hence the necessity of using CT or MRI for further evaluation. MRI has clearer soft tissue imaging compared with CT and can better reveal the invasion of RMS to the adjacent pelvic organs. It has become the first choice for pelvic RMS[39-41] but few reports are available for MRI description of PRMS. By observing the sagittal, coronal, and axial T2 weighted high-resolution images of the pelvis, we found a significant feature of PRMS that the hypointensity of the external anal sphincter (EAS) is replaced by the hyperintensity of the tumor, causing a discontinuity of the anal sphincter complex. In some cases, the muscle signal of EAS can be observed cutting into the tumor; a pseudocapsule-like structure was formed by the compressed EAS surrounding the tumor (Figure 1). According to these features, we suggest that PRMS probably originates from EAS. Compression rather than direct invasion of rectal wall and anal canal is observed (n=4), which is different from the characteristics of anal canal cancer[42, 43] and thus valuable for differential diagnosis.

Among the 15 patients treated in our center, 5 underwent abscess incision or drainage previously in other hospitals and 4 of them had poor prognosis. For the 2 patients survived for more than 5 years, one was initially diagnosed as perianal abscess but only treated with antibiotics without surgery; both of them received radical operation (R0) in our center and no evidence of recurrence was found after 5 years' follow up. Wrong surgical treatment can destroy the integrity of tumor and leads to poor prognosis. If PRMS is diagnosed on time and distant metastasis is excluded, surgical treatment should be carried out as soon as possible. Taking into account the tumor is likely to be originated from EAS, ELAPE (extra-levator abdominalperineal excision) could be the choice for most patients to achieve R0 excision. If the tumor was relatively confined and only a small portion of EAS was involved, LRR with reserved anus can be performed. In fact, 5 patients received LRR in our center and 3 of them survived for more than 5 years; 1 recurred due to failure to achieve R0 resection and is undergoing further treatment until now; 1 has no evidence of recurrence after 2 years of follow-up but course of disease was prolonged due to rectovaginal fistula caused by surgical damage of perineum. LRR can achieve long-term survival without compromising anal function, but R0 resection must be guaranteed and perineum shall be protected during the operation to avoid rectovaginal/rectourethral fistula.

Optimal treatment of PRMS is controversial. Comprehensive therapy is recommended by relative literatures but most of them are single-center retrospective analysis of few cases. Recently, a multicenter study showed a 64-86% 5-year survival rate of patients receiving chemotherapy combined with surgery or radiotherapy reached[32]. Among the 15 patients treated in our center, 9 received radical operation and chemotherapy and the 5-year OS of them is 57%; the other 6 patients received chemotherapy alone and had poor prognosis. 4 patients received chemoradiotherapy with or without surgery in our center have survived up to now with no evidence of recurrence, but long-term efficacy of radiotherapy remains to be evaluated. Inguinal lymph node metastasis is one of the main factors of poor outcome. In this group, 11 patients were complicated with lymph node metastasis. 5-year survival rate was only 26% for the 9 patients with preoperative inguinal lymph nodes involvement. One patient had ilium lymph node metastasis in 5 months and died in 11 months postoperatively. Concerning the high incidence of regional lymph node metastasis in PRMS, it is suggested that inguinal lymph nodes resection or irradiation should be performed prophylactically[26], but such aggressive approach may be avoided with the application of PET-CT which can effectively improve the detection rate of lymph node metastasis[44, 45]. Breast metastasis was found in 2 cases in this study, which was also reported in a Japanese literature[25], providing a clue for the specific metastatic pathway and histological characteristic of PRMS.

## Conclusion

In summary, primary PRMS is a rare disease. It is easy to be misdiagnosed, which could lead to worse outcome. Patients presented as painful perianal mass should be carefully evaluated to exclude this malignancy. PRMS is found to be closely related to external anal sphincter, MRI should be conducted to determine EAS invasion. Comprehensive therapy including radical operation and chemotherapy is recommended. It is necessary to achieve further improvements in the clinical outcome of PRMS patients by developing new therapeutic modalities.

## Abbreviations

RMS: Rhabdomyosarcoma; PRMS: Perianal/perineal rhabdomyosarcoma; CT: Computed tomography; MRI: Magnetic resonance imaging; IRS: Intergroup Rhabdomyosarcoma Study; CDFI: color Doppler flow imaging; EAS: external anal sphincter; APR: abdominoperineal resection; LRR: local radical tumor resection; MAID: mesna+adriamycin+isocyclic amide+dacarbazine; CYVADIC: cyclophosphamide+vincristine+adriamycin+dacarbazine; CEVAIE: carboplatin+epirubicin+ vincristine+dactinomycin+ifosfamide+etoposide; FOLFOX: fluorouracil+oxaliplatin+calcium folinate; TP: cisplatin+paclitaxel

## Declarations

### Ethics approval and consent to participate

This study was approved by the Medical Ethics Committee of the Sixth Affiliated Hospital, Sun Yat-sen University.

### Consent for publication

Not applicable.

### Availability of data and materials

The datasets generated during and/or analyzed during the current study are available from the corresponding author on reasonable request.

## Competing interests

The authors declare that they have no competing interests

## Funding

No

## Authors' contributions

YYG and BH contributed to the research design; YYG, DDH, XHW and DLR contributed to the data collection, data analysis, and manuscript writing. JL, DZ, XYL and GC contributed to the data collection and manuscript writing. All authors contributed to the writing review and editing. All authors read and approved the final manuscript.

## Acknowledgements

We appreciated all authors for their efforts on the manuscript.

## References

1. Raney RB, Donaldson MH, Sutow WW, Lindberg RD, Tefft M: **Special considerations related to primary site in rhabdomyosarcoma: experience of the Intergroup Rhabdomyosarcoma Study, 1972–76.***National Cancer Institute Monograph* 1981, **56**:69-74.
2. Hill DA, Dehner LP, Gow KW, Pappo AS, Crawford D, Pflaumer SM, Furman WL, Hayes-Jordan AA, McDermott MB: **Perianal rhabdomyosarcoma presenting as a perirectal abscess: A report of 11 cases.***J Pediatr Surg* 2002, **37**:576-581.
3. Raney RB, Maurer HM, Anderson JR, Andrassy RJ, Donaldson SS, Qualman SJ, Wharam MD, Wiener ES, Crist WM: **The Intergroup Rhabdomyosarcoma Study Group (IRSG): Major Lessons From the IRS-I Through IRS-IV Studies as Background for the Current IRS-V Treatment Protocols.***Sarcoma* 2001, **5**:9-15.
4. Liu H, He HB, Wu J, Yang CM : **A case of adult perianal rhabdomyosarcoma with abscess (Titled in Chinese).***Med J West Chin* 2011, **023**:2431.
5. Liu ZS, Yang FJ, Li D: **Perianal rhabdomyosarcoma misdiagnosed as perianal abscess: analysis of two cases (Titled in Chinese).***Contemporary Med* 2009, **0**:115.
6. Li LQ, Liu YJ: **A Case of Perianal Rhabdomyosarcoma (Titled in Chinese).***Railway Med* 1993.
7. Mo B, Xu B: **A Case Report of Perianal Rhabdomyosarcoma (Titled in Chinese).***J Colorectal & Anal Surg* 2015, **021**:387.
8. Wang JH, Yu L, Yan WX, Jia XJ: **A Case of Perianal Rhabdomyosarcoma Treated by synchronous radical Chemoradiotherapy (Titled in Chinese).***Chin J Lab Diagn* 2018, **022**:1590-1591.
9. Chen YQ, Qian HH, Huang JC, Li GN: **Perianal rhabdomyosarcoma: report of 3 cases and clinical analysis (Titled in Chinese).***Chin J Crit Care Med (Electronic Version)* 2008, **1**:39-40.
10. He LZ, Wang ZQ, Yin M: **Perianal Rhabdomyosarcoma Misdiagnosed as Perianal Abscess: A Case Report (Titled in Chinese).***Chin J Coloproctol* 2011, **031**:63.
11. Nie JL, Zhang YJ, Liu WY, Chen L: **Perianal Embryonal Rhabdomyosarcoma: A Case Report (Titled in Chinese).***Chin J Lab Diagn* 2016:681-682.
12. Liu HB, Song M, Wang LN, Liu JP, Ren XY: **Primary Perianal Solid Alveolar Rhabdomyosarcoma: A Case Report (Titled in Chinese).***Guangdong Med J* 2016, **037**:3172.
13. Zong JY, Yu YD, Ji XG, Ni DB: **Rhabdomyosarcoma Misdiagnosed as Perianal Abscess: A Case Report (Titled in Chinese).***The 12th academic conference of colorectal diseases of Chinese Association of traditional Chinese Medicine* 2006:2.
14. Zhao W, Chen HM: **A Case of Girl Perianal Rhabdomyosarcoma (Titled in Chinese).***Chin Clin Oncol* 2013:100-101.
15. Zhu MX, Zhu N: **Experience of Misdiagnosis of Perianal Rhabdomyosarcoma: A Case Report (Titled in Chinese).***J New Med* 2007:676.
16. Jin ML, Jiang J: **A Case of Embryonal Rhabdomyosarcoma in Children (Titled in Chinese).***Chin J Bases Clin General Surg* 2005:9.
17. Wang Y, Zou YR, Li JH: **A Case of Perianal Pleomorphic Rhabdomyosarcoma in Children (Titled in Chinese).***Sichuan J Cancer Control* 2000:29.
18. Yu L, Zhang PD, Zhao LZ: **Primary Perianal Embryonal Rhabdomyosarcoma: A Report of 2 Cases (Titled in Chinese).***Chin J Clin Oncol* 2000:3.
19. Jian NG, Zhou YY: **Perianal Alveolar Rhabdomyosarcoma: A Case Report (Titled in Chinese).***Chin J Coloproctol* 2001, **21**:28.
20. S. A: **Rhabdomyosarcoma and other soft tissue sarcomas of childhood.***Curr Opin Oncol* 1994, **6**:397-402.
21. Ferrari A, Dileo P, Casanova M, Bertulli R, Meazza C, Gandola L, Navarria P, Collini P, Gronchi A, Olmi P: **Rhabdomyosarcoma in adults : A retrospective analysis of 171 patients treated at a single institution.***Cancer-Am Cancer Soc* 2003, **98**:571-580.
22. Crist W, Gehan EA, Ragab AH, Dickman PS, Donaldson SS, Fryer C, Hammond D, Hays DM, Herrmann J, Heyn R, Et A: **The Third Intergroup Rhabdomyosarcoma Study.***J Clin Oncol* 1995, **13**:610-630.
23. Lawrence WJ, Anderson JR, Gehan EA, Maurer H: **Pretreatment TNM staging of childhood rhabdomyosarcoma: a report of the Intergroup Rhabdomyosarcoma Study Group. Children's Cancer Study Group. Pediatric Oncology Group.***Cancer-Am Cancer Soc* 1997, **80**:1165-1170.
24. Sultan I, Qaddoumi I, Yaser S, Rodriguez-Galindo C, Ferrari A: **Comparing adult and pediatric rhabdomyosarcoma in the surveillance, epidemiology and end results program, 1973 to 2005: an analysis of 2,600 patients.***J Clin Oncol* 2009, **27**:3391-3397.

25. Okamura K, Yamamoto H, Ishimaru Y, Takayasu H, Otani Y, Yamagishi J, Takahashi A, Kuwano H, Nagashima K, Ikeda H: **Clinical characteristics and surgical treatment of perianal and perineal rhabdomyosarcoma: analysis of Japanese patients and comparison with IRSG reports.***Pediatr Surg Int* 2006, **22**:129-134.
26. Casey DL, Wexler LH, LaQuaglia MP, Meyers PA, Wolden SL: **Patterns of failure for rhabdomyosarcoma of the perineal and perianal region.***Int J Radiat Oncol Biol Phys* 2014, **89**:82-87.
27. Marcus RH, Stine RJ, Cohen MA: **Perirectal Abscess.***Ann Emerg Med* 1995, **25**:597-603.
28. Christison-Lagay ER, Hall JF, Wales PW, Bailey K, Terluk A, Goldstein AM, Ein SH, Masiakos PT: **Nonoperative Management of Perianal Abscess in Infants Is Associated With Decreased Risk for Fistula Formation.***Pediatrics* 2007, **120**:e548-e552.
29. Serour F, Somekh E, Gorenstein A: **Perianal Abscess and Fistula-In-Ano in Infants: A Different Entity?***Dis Colon Rectum* 2005, **48**:359-364.
30. Macdonald A, Storey DW, Munro F: **Treatment of perianal abscess and fistula-in-ano in children.***Brit J Surg* 2003, **90**.
31. Blakely ML, Andrassy RJ, Raney RB, Anderson JR, Wiener ES, Rodeberg DA, Paidas CN, Lobe TE, Crist WM: **Prognostic factors and surgical treatment guidelines for children with rhabdomyosarcoma of the perineum or anus: A report of intergroup rhabdomyosarcoma studies I through IV, 1972 through 1997.***J Pediatr Surg* 2003, **38**:353.
32. Fuchs J, Dantonello TM, Blumenstock G, Kosztyla D, Klingebiel T, Leuschner I, Schuck A, Niggli FK, Koscielniak E, Seitz G: **Treatment and outcome of patients suffering from perineal/perianal rhabdomyosarcoma: results from the CWS trials—retrospective clinical study.***Ann Surg* 2014, **259**:1166-1172.
33. Youssef AT: **Use of Ultrasonography in Clarifying the Etiology of Anal Pain.***J Med Ultrasound* 2017, **25**:208-214.
34. Mak CW, Chou CK, Su CC, Huan SK, Chang JM: **Ultrasound diagnosis of paratesticular rhabdomyosarcoma.***Brit J Radiol* 2004, **77**:250-252.
35. Annam A, Munden MM, Mehollin-Ray AR, Schady D, Browne LP: **Extratesticular masses in children: taking ultrasound beyond paratesticular rhabdomyosarcoma.***Pediatr Radiol* 2015, **45**:1382-1391.
36. Bahnson RR, Zaontz MR, Maizels M, Shkolnik AA, Firlit CF: **Ultrasonography and diagnosis of pediatric genitourinary rhabdomyosarcoma.***Urology* 1989, **33**:64-68.
37. Linea C, Sinagra E, Gioia F, Rimi C: **Perianal embryonal rhabdomyosarcoma diagnosed by endoscopic ultrasound-guided fine needle aspiration.***Endoscopy* 2012, **44 Suppl 2 UCTN**:E342-E343.
38. Agrons GA, Wagner BJ, Loneragan GJ, Dickey GE, Kaufman MS: **From the archives of the AFIP. Genitourinary rhabdomyosarcoma in children: radiologic-pathologic correlation.***Radiographics* 1997, **17**:919-937.
39. Tappouni RF, Sarwani NI, Tice JG, Chamathi S: **Imaging of unusual perineal masses.***Ajr Am J Roentgenol* 2011, **196**:412-420.
40. Fletcher BD, Kaste SC: **Magnetic resonance imaging for diagnosis and follow-up of genitourinary, pelvic, and perineal rhabdomyosarcoma.***Urologic Radiology* 1992, **14**:263-272.
41. Finelli A, Babyn P, Lorie GA, Bagli D, Khoury AE, Merguerian PA: **The use of magnetic resonance imaging in the diagnosis and followup of pediatric pelvic rhabdomyosarcoma.***J Urol* 2000, **163**:1952-1953.
42. Swami VG, Joseph K, Severin D, Tankel K, Usmani N, Nijjar T: **Benefit of MRI scanning in the pretreatment assessment of anal canal carcinoma.***Pract Radiat Oncol* 2013, **3**:S9-S10.
43. Roach SC, Hulse PA, Moulding FJ, Wilson R, Carrington BM: **Magnetic resonance imaging of anal cancer.***Clin Radiol* 2005, **60**:1119.
44. Ricard F, Cimarelli S, Deshayes E, Moggetti T, Thiesse P, Giammarile F: **Additional Benefit of F-18 FDG PET/CT in the staging and follow-up of pediatric rhabdomyosarcoma.***Clin Nucl Med* 2011, **36**:672-677.
45. Volker T, Denecke T, Steffen I, Misch D, Schonberger S, Plotkin M, Ruf J, Furth C, Stover B, Hautzel H: **Positron Emission Tomography for Staging of Pediatric Sarcoma Patients: Results of a Prospective Multicenter Trial.***J Clin Oncol* 2007, **25**:5435-5441.

## Tables

table1: Clinical features in 15 patients from the Sixth Affiliated Hospital and the Cancer Center of Sun Yat-sen University

Gender/Age	Presenting symptoms	Misdiagnosis/Mistreatment	time interval from symptom onset to pathological diagnosis	Tumor site	Maximum diameter of tumor (cm)	Treatment*	Pathological subtype	IRS Stage
1/10y	Perianal mass	None	3d	Perineal	6.6	LRR(R0)+Chemotherapy	ERMS	IV/ple Me
2/≥20y	Perianal mass	None	1m	Perineal	4.5	APR(R0)+Chemotherapy	ARMS	II/1
2/≥20y	Perianal mass	None	1m	Perineal	12.2	Chemotherapy	ERMS	III/
2/10-19y	Perianal mass	None	1m	Perianal	6.8	Chemotherapy	ERMS	IV/ pel ret
2/≥20y	Painful perianal mass	Perianal abscess/abscessotomy	2m	Perianal	10.0	APR(Rx)+Chemotherapy	ARMS	II/1
2/≥20y	Painful perianal mass	None	7d	Perianal	4.7	APR(R0)+Chemotherapy	ARMS	I/T
2/10-19y	Perianal mass	None	2m	Perineal	5	Inguinal lymph node dissection+ chemotherapy	ERMS	III/
2/≥20y	Perianal mass	Perianal abscess/ Intravenous antibiotics	2m	Perianal	8	LRR(Rx)+Inguinal lymph node dissection+Chemoradiation therapy	ARMS	II/1
2/10-19y	Perianal mass	None	5m	Perianal	6.0	LRR(R0)+chemotherapy	ERMS	II/1
1/10-19y	Perianal mass;; difficult defecation	None	1m	Perianal	1.8	Chemotherapy	ERMS	IV/
2/≥20y	Perianal mass	Perianal abscess/Abscessotomy+ partial mass ectomy	4m	Perianal	6.2	APR(R0)+Chemotherapy	ARMS	II/1
2/10-19y	Painful perianal mass	Abscessotomy	2m	Perianal	6.3	LRR(Rx)+Chemoradiation therapy	ERMS	II/1
2/10-19y	Painful perianal mass;; Bloody stool	None	2m	Perianal	7.5	Chemotherapy	ARMS	IV/ ab
2/10-19y	Inguinal mass	None	3m	Perineal	5.9	LRR(Rx)+abdominopelvic and inguinal lymph node dissection+  Chemoradiation therapy	ERMS	II/1
2/≥20y	Painful perianal mass	Abscessotomy	3 m	Perianal	10.0	Chemotherapy	ARMS	III/

\*R0: Microscopic negative margins; R1: Microscopic positive margins; Rx: Not evaluated

Abbreviations: y, year; m, month; d, day; ARMS, alveolar rhabdomyosarcoma; ERMS, embryonal rhabdomyosarcoma; NED, no evidence of disease; DOD, died of disease; AWD, alive with disease.

Table2: Data of 35 patients		
age	23m-56y (median, 23y)	
	≤10y	4 (11%)
	10-19y	13 (38%)
	≥20y	18 (51%)
gender	male	10 (29%)
	female	25 (71%)
symptoms	Perianal mass	34 (97%)
	Pain	20 (57%)
	Inguinal mass	2 (6%)
	Bloody stool	2 (6%)
	Difficult defecation	2 (6%)
	Fecal incontinence	1 (3%)
Misdiagnosis history/ time interval of diagnosis	35(3d-10m, 3.1m)	
	Misdiagnosis	16(10d-3m, 2.6m)
	No misdiagnosis	19(3d-10m, 3.4m)
Pathological subtype	Alveolar	9
	Embryonal	14
	Pleomorphic	1
	ND	11
IRS clinical group	I	1
	II	11
	III	8
	IV	5
	ND	10
Stage	2	6
	3	15
	4	5
	ND	9
Tumor site	Perianal	26
	Perineal	9
Tumor size	≤5cm	12
	≥5cm	22
	ND	1
Regional lymph node metastasis	N0	7
	N1	15
	ND	13
Distant metastasis	M0	17
	M1	5
	ND	12
Surgical approach	LRR	12
	APR	7
	No surgery	9
	or biopsy only	



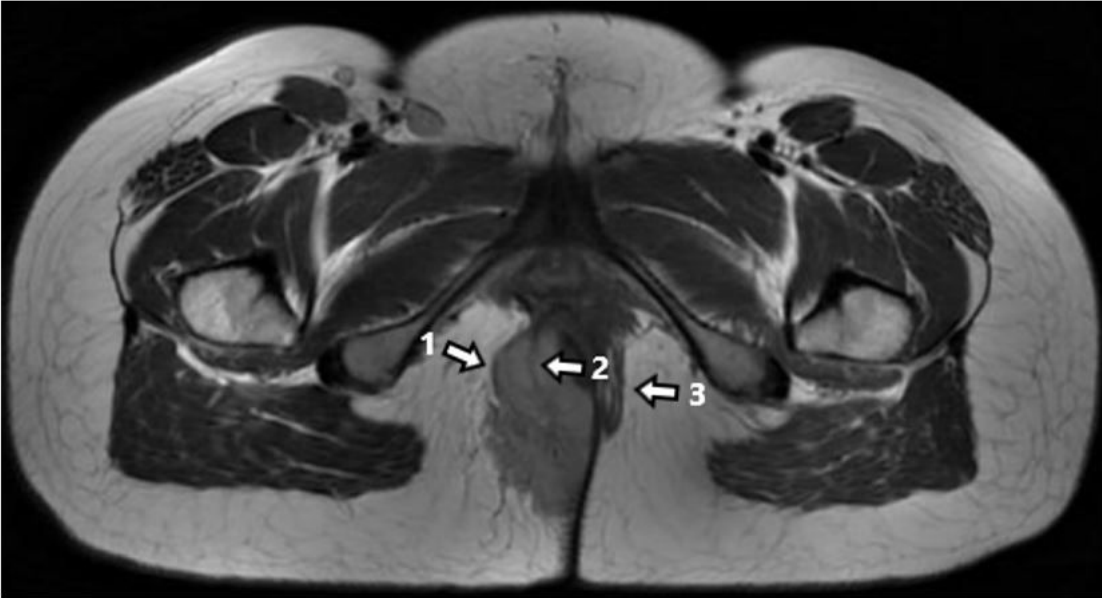
	ND	7
Outcome	Survival time $\geq$ 5y	5
	NED	3
	AWD	2
	Survival time $\geq$ 5y	3
	NED	2
	AWD	1
	DOD	14
	ND	13

Abbreviations: y, year; m, month; d, day; NED, no evidence of disease; DOD, died of disease; AWD, alive with disease; ND, not described

**Table3: Factors of misdiagnosis**

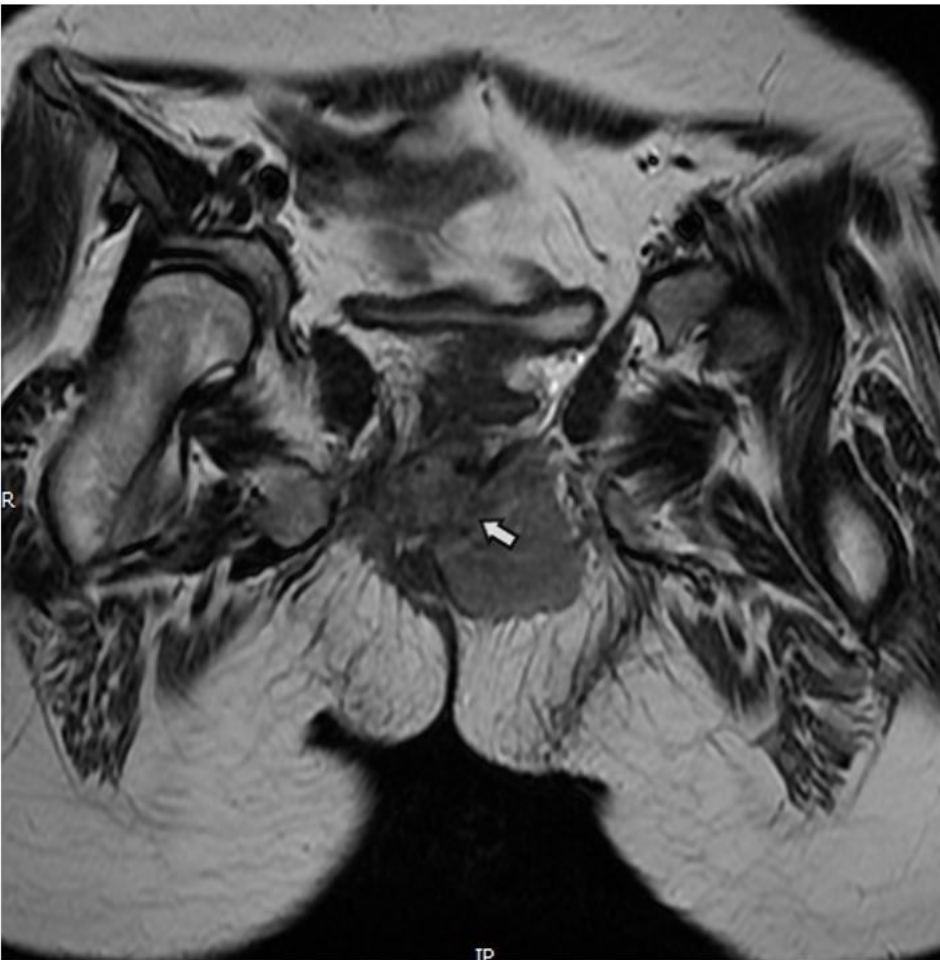Features	Misdiagnosis		P
	no	yes	
Pain			
no	12	3	0.010
yes	7	13	
Gender			
male	5	5	0.519
female	14	11	
Age			
≤20y	12	5	0.061
≥20y	7	11	
Tumor site			
perianal	13	13	0.319
perineal	6	3	
Tumor size			
≤5cm	8	4	0.285
≥5cm	11	11	
Pathological subtype			
Alveolar	5	4	0.239
Embryonal	11	3	
IRS clinical group			
I	1	0	0.783
II	7	4	
III	4	4	
IV	4	1	
Stage			
2	5	1	0.391
3	8	7	
4	4	1	

## Figures



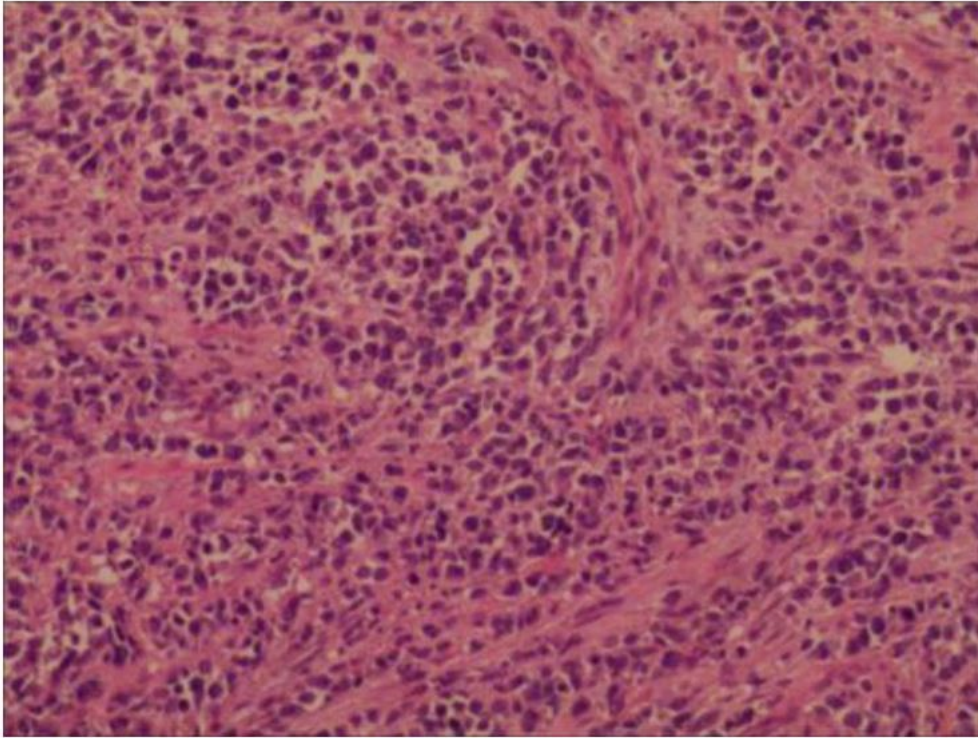
**Figure 1**

EAS was suppressed and formed Pseudocapsule (arrow 1); Part of the remaining muscle bundles were cutted into the tumor (arrow 2); contralateral EAS remained intact (arrow 3)



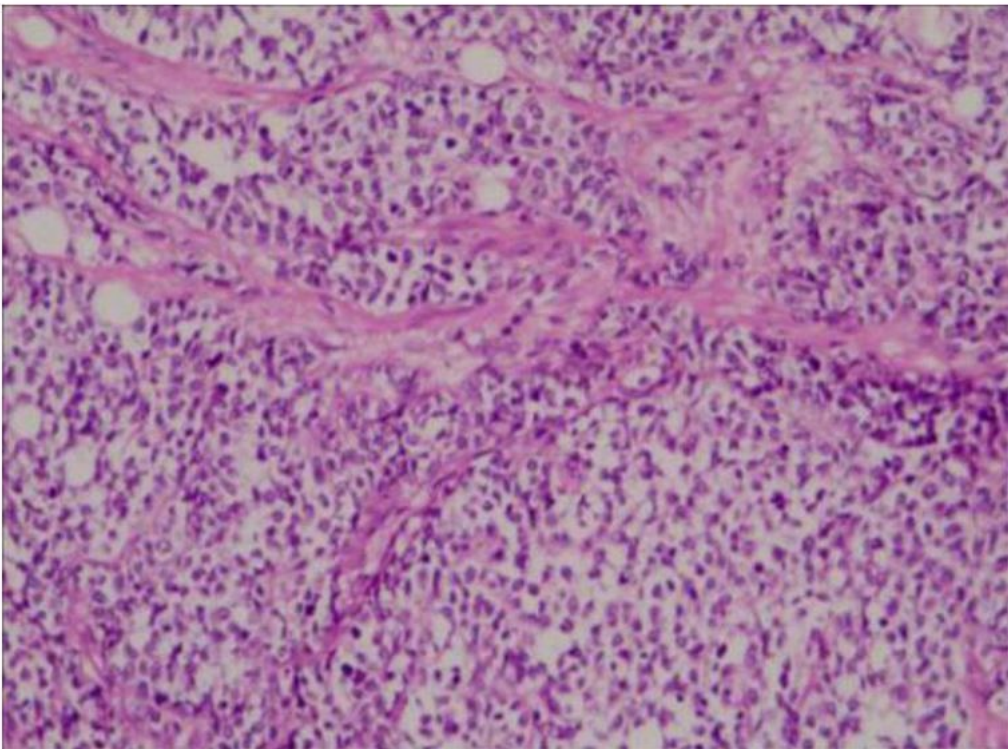
**Figure 2**

Puborectalis was replaced by tumor signal and bilateral levator ani was involved (arrow)



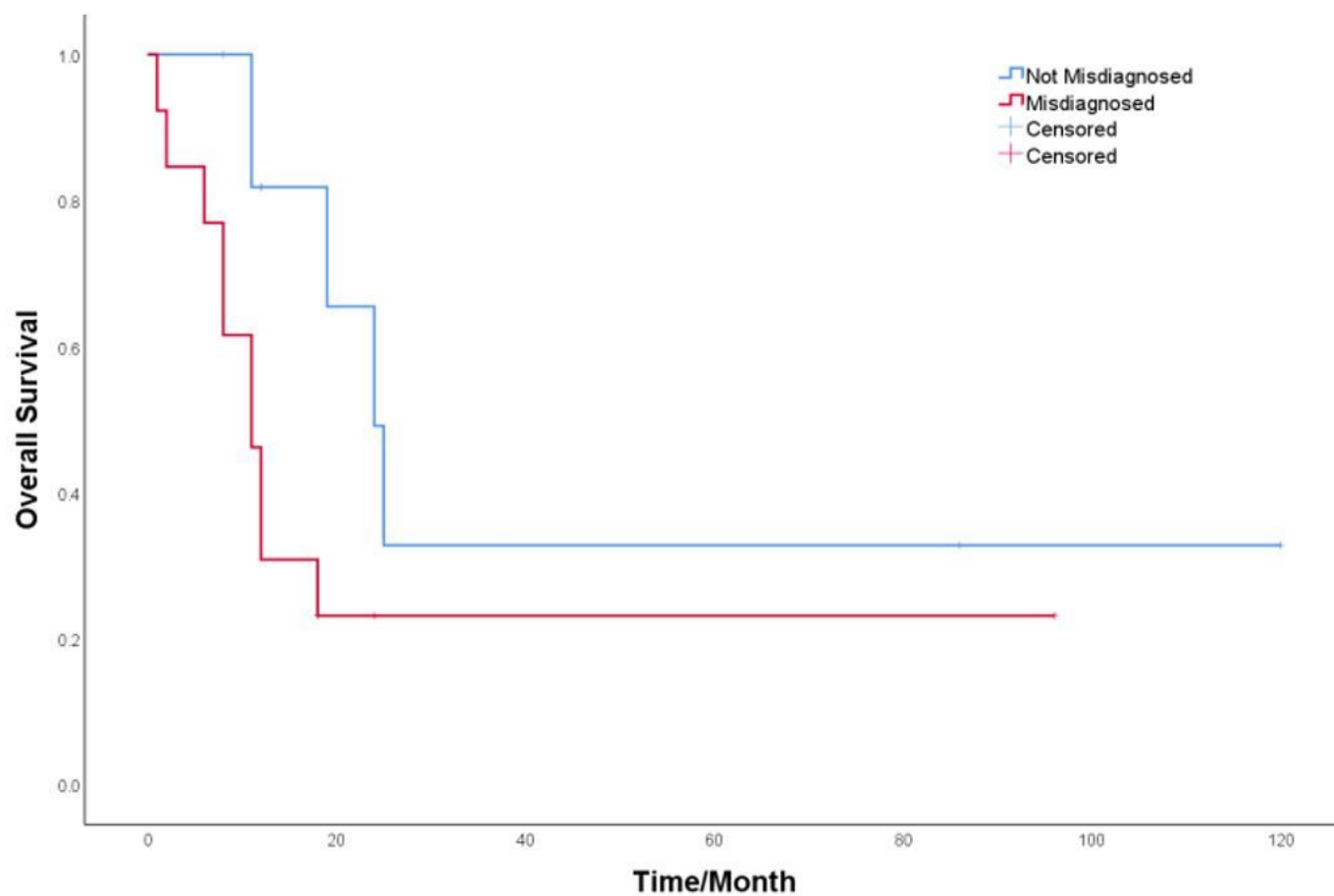
**Figure 3**

Alveolar RMS: Round, oval or spindle shaped tumor cells were arranged in an acinar, tubular, fissured or nest-like form. Multifocal necrosis and interstitial fibrosis were constantly presented.



**Figure 4**

Embryonal RMS was characterized by small round cells with scant eosinophilic cytoplasm and hyperchromatic ovoid-shaped nuclei.



**Figure 5**

Kaplan-Meier curves comparing survival of patients with or without misdiagnosis history.

## Supplementary Files

This is a list of supplementary files associated with this preprint. Click to download.

- [supplement1.docx](#)